Renal Artery Stenosis: Clinical and Therapeutic Implications

Richard A. Regnante, MD, John W. Obell, MD, and Paul Gordon, MD

Renal artery stenosis is a common cause of secondary hypertension with a rising incidence due to systemic atherosclerosis in an aging population. Patients with renovascular disease complicated by refractory hypertension, acute pulmonary edema, or progressive renal dysfunction benefit from aggressive medical therapy and may be considered for renal revascularization. **Atherosclerotic renal artery stenosis** (**ARAS**) accounts for the majority of patients with **renal artery stenosis** (**RAS**); however, the subset of patients with **fibromuscular dysplasia** (**FMD**) and hypertension represents a unique group that benefits from renal artery revascularization.

Clinical Features of Renal Artery Stenosis

Renovascular disease can result from a number of pathophysiologic and anatomic abnormalities. Rarely, renal artery congenital malformations, renal artery vasculitides, renal artery aneurysms, embolic phenomena, arteriovenous malformations or fistulas, extrinsic compression of the renal arteries, prior abdominal radiation therapy, neurofibromatosis, William's syndrome, spontaneous dissections and traumatic injury to the renal arteries, can result in renal artery pathology.[1-11] Atherosclerotic renal artery disease and renal artery fibromuscular dysplasia are by far the most common causes of RAS, with atherosclerotic disease accounting for 80-90% of RAS.[12,13] ARAS usually occurs in the setting of systemic atherosclerotic cardiovascular disease. It is common to identify coronary, carotid, aortic and peripheral arterial disease in patients with ARAS.

Atherosclerotic disease of the renal artery usually involves the proximal 2 cm of the renal artery, and aorto-ostial segment disease typically represents a continuum of aortic disease extending into the main renal artery branch. (Figure 1)[13] Atherosclerotic disease typically progresses, with 36-71% of lesions progressing to significant stenosis and 16% progressing to total occlusion after 12-60 months of follow-up.[14-18]

The prevalence of ARAS in the general population is difficult to quantify and varies depending on age and other vascular comorbidities. One population-based study that randomly screened elderly patients in the population found a prevalence of 6.8%.[19] Typically patients with ARAS tend to be older, with traditional risk factors for cardiovascular disease and associated comorbidities such as coronary artery disease or cerebral vascular disease. In one study, 30% of patients undergoing cardiac catheterization were incidentally found to have RAS.[20] Significant RAS can be found in up to 70% of patients with evidence of atherosclerosis in other vascular beds.[21]

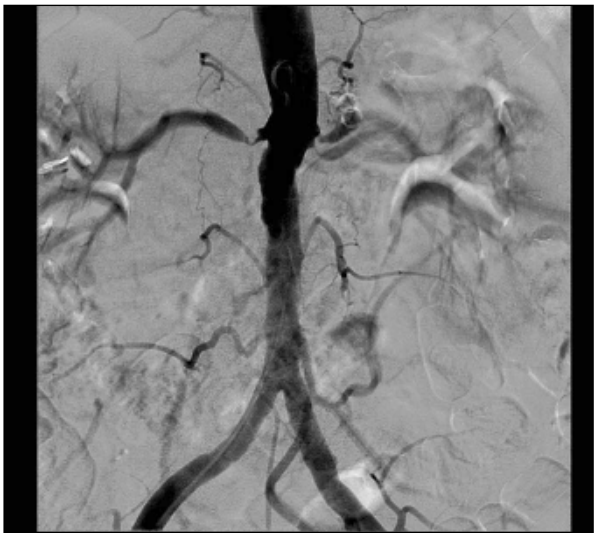

Figure 1. Non-selective distal abdominal aortic angiography showing bilateral aorto-ostial atherosclerotic renal artery stenoses (single right renal artery and 2 left renal arteries). Note the luminal irregularities in the infrarenal abdominal aorta and proximal portions of the iliac arteries secondary to atherosclerotic plaque.

Hypertension, the most common clinical manifestation of RAS, is present in nearly a third of patients with malignant or uncontrolled hypertension despite multidrug therapy. However, half of the patients with significant RAS do not have hypertension, or their blood pressure is well controlled on minimal therapy. Progressive RAS can lead to the development of progressive renal failure, clinically significant renal atrophy, and decreased life expectancy.[22-24]

The impact of RAS on the time to development of renal replacement therapy has not been well established due to multiple confounding factors. However, the life expectancy of a patient on hemodialysis with renovascular disease is much shorter than that of a patient on hemodialysis due to polycystic kidney disease or uncontrolled hypertension without RAS.[25] This is likely due to the association of comorbid atherosclerotic cardiovascular and cerebrovascular disease. In fact, the presence of ARAS, even if not hemodynamically significant, is associated with premature cardiovascular events (myocardial infarction, stroke, and death), and the presence of ARAS in patients with coronary artery disease independently doubles a patient's risk of death, even if coronary revascularization is performed.[26]

Fibromuscular dysplasia

FMD usually occurs in younger patients, mainly women age 15-50 years, without systemic vascular disease or cardiovascular risk factors. FMD accounts for 10-20% of adult cases of RAS.[13] Patients with FMD usually present with refractory hypertension and rarely have renal dysfunction.[27] The suspicion for FMD should be raised in a younger woman with severe or newly diagnosed hypertension.

FMD is sub-classified into three categories based on the layer of arterial wall affected, intimal, medial and adventitial. Medial FMD is the most common of the three sub-groups by far in the adult population.[13] While ARAS typically involves the ostial and proximal segments

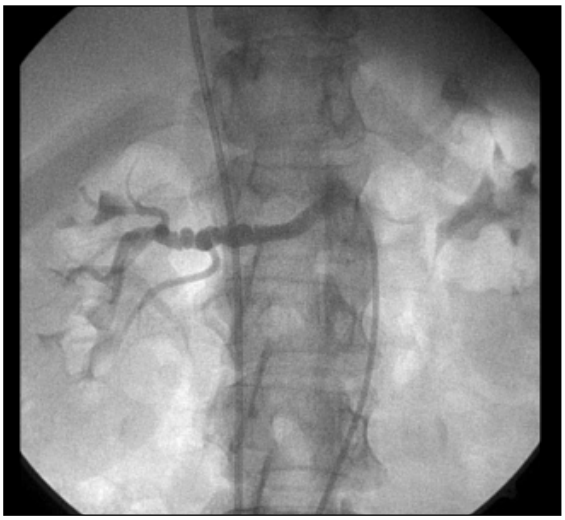

Figure 2. Selective right renal angiography in a patient with fibromuscular dysplasia extending from the distal third of the main renal artery into the branch vessels. Note the "beaded" appearance of the artery.

of the renal artery, FMD involves the mid to distal segment of the main renal artery and may extend into branches, with a characteristic "beaded" angiographic appearance.[13] (Figure 2)

FMD can affect the carotid, vertebral, iliac and mesenteric arteries, and there is an association with cerebral artery aneurysms.[28] The diagnostic evaluation of patients with suspected RAS from FMD is similar to patients with ARAS.

Clinical Evaluation and Diagnosis

The clinical evaluation of patients with suspected RAS should begin with the history, physical examination and basic laboratory testing. Patients with hypertension, renal dysfunction or recurrent unexplained flash pulmonary edema should raise suspicion for the diagnosis of RAS, particularly in a patient with known cardiovascular disease or with multiple cardiovascular risk factors.

Hypertensive patient

RAS is the most common cause of secondary hypertension. RAS causes or exacerbates hypertension via endocrinologic activation of the renin-angiotensin-aldosterone axis. In patients with unilateral RAS, elevated blood pressure is predominantly secondary to activation of angiotensin II, which is a potent vasoconstrictor, but volume expansion as a result of excess aldosterone secretion is limited by natriuresis of the contralateral normally functioning kidney.[29,30] In patients with bilateral RAS or with only one functioning kidney, the natriuretic effect of the contralateral kidney is lost and the elevated blood pressure is maintained by volume expansion rather than chronically elevated renin levels.[29,30] In the hypertensive patient, there are several clues that suggest the diagnosis of a secondary cause of hypertension such as RAS.[31] (Table 1) Other causes of secondary hypertension include pheochromocytoma, Cushing's syndrome, Conn's syndrome, obstructive sleep apnea, coarctation of the aorta, hypothyroidism, hyperparathyroidism and medications such as oral contraceptives, non-steroidal anti-inflammatory agents, steroids, immunosuppresants, erythropoietin derivatives, and some antidepressants.[32]

Renal dysfunction

RAS should be considered in the patient with renal insufficiency without hematuria or significant proteinuria and bland urinary sediment. Specific patterns of renal dysfunction exist that suggest RAS as the etiology of the renal dysfunction.[31] (Table 2)

Congestive heart failure

Certain patients with congestive heart failure should raise the suspicion of RAS.[31] (Table 3)

Diagnostic Imaging

After a thorough history and physical examination, multiple diagnostic imaging modalities exist to identify RAS. **Magnetic resonance angiography (MRA), computed tomographic angiography (CTA)**, duplex **ultrasound (U/S)** and conventional angiography are the main imaging tests for the evaluation of RAS. All of the non-invasive tests have similar sensitivity and specificity compared to conventional angiography.[31] Captopril renal scintigraphy, selective renal vein renin measurement and plasma renin measurement with or without captopril administration are no longer recommended as initial diagnostic tests for RAS due to their lack of sensitivity and specificity, although they may still be helpful in isolated circumstances.[31] Test availability and patient factors are the main determinants of the test to be used for diagnosis of RAS.

Magnetic resonance angiography

MRA is an accurate, comprehensive way to evaluate for RAS, and is now the test of choice to diagnose RAS.[31] The benefits include its lack of ionizing radiation, ability to visualize both main and accessory renal arteries, the renal parenchyma, and the aorta and adjacent mesenteric and iliac arterial branches. MRA requires the infusion of gadolinium as a contrast agent, so caution should be used in patients with renal insufficiency given the recently described potentially fatal nephrogenic systemic fibrosis secondary to gadolinium tissue deposition in patients with renal insufficiency.[33] Other limitations include lack of widespread availability, long acquisition and exam time resulting in claustrophobia in some patients, and limitations of metallic artifact that preclude its use as an imaging tool to follow patients with prior renal stenting.[31]

Table 1. Clinical Scenarios suggesting renal artery stenosis

- New onset hypertension at age less than 30 or greater than 55
- Severe, malignant hypertension (refractory to 3 or more medications, including a diuretic)
- Uncontrolled hypertension that was previously well controlled medically
- Hypertension in an individual without a family history of essential hypertension
- Severe hypertension causing refractory angina or congestive heart failure
- Presence of an abdominal bruit on physical examination in a patient with hypertension

Table 2. Patterns of renal dysfunction that suggest renal artery stenosis

- Development of worsening renal function after initiation of an ACE-I or ARB (greater than 25% increase in creatinine)
- Unexplained atrophy of kidneys (less than 8cm) or size discrepancy of greater than 1.5cm between each kidney
- Unexplained renal dysfunction, including those patients starting hemodialysis
- Presence of an abdominal bruit on physical examination in a patient with renal insufficiency

Table 3. Subsets of patients with congestive heart failure that suggest renal artery stenosis

- Recurrent pulmonary edema without significant coronary artery disease, valvular disease or left ventricular dysfunction
- Severe hypertension and otherwise unexplained congestive heart failure

Computed tomographic angiography

CTA is a fast, effective, comprehensive way to evaluate for RAS.[31] The advantages include its widespread availability, short exam time, the ability to visualize the main and accessory renal arteries, the renal parenchyma and the abdominal aorta and adjacent mesenteric and iliac arterial branches. However, its use requires the infusion of 100-150ml of iodinated contrast, which may limit its use in patients with renal insufficiency. The exposure to radiation may limit its use in younger patients or in patients who require serial evaluations of a stent after a revascularization procedure. In addition, the metallic artifact of stents may make it difficult to evaluate the severity of in-stent stenoses.

Duplex ultrasound

Duplex ultrasound is a safe, effective and inexpensive way to evaluate for RAS. Ultrasound is portable and there is no radiation or use of potential nephrotoxic contrast agents. Anatomic and functional information can be obtained about the main renal arteries, renal size and appearance. The diagnosis of renal artery stenosis is both based on anatomic appearance and on doppler flow. The *renal resistive index* is calculated based on doppler findings. An abnormal renal resistive index may identify patients with significant renal parenchymal disease who may not benefit from renal revascularization.[31] Unfortunately, ultrasound is highly operator and patient dependent, with limited images in obese patients or patients with significant bowel gas. There is limited ability to evaluate for accessory renal arteries. Ultrasound is thus limited as an initial diagnostic test for renal artery stenosis. However, ultrasound is an excellent test for serial evaluations of stent patency after percutaneous revascularization since there is no radiation or contrast risk and images are not limited by metallic stent artifact.

Conventional angiography

Catheter-based angiography, long considered the "gold standard" for the evaluation of RAS, has largely been replaced by the non-invasive tests, but is still very valuable in patients with equivocal findings on non-invasive tests. Conventional angiography may be especially helpful in patients with suspected FMD, as the sensitivity of non-invasive testing is much lower in patients with FMD.[31] In patients without renal failure, the rate of serious adverse outcomes with non-selective renal angiography, such as contrast-induced nephropathy, bleeding or atheroemboli, is low.[34] American Heart Association guidelines support the use of non-selective renal angiography in patients undergoing diagnostic cardiac catheterization or peripheral angiography in whom there is a high suspicion of RAS, especially if they are candidates for renal revascularization.[34] Conventional angiography is performed in all patients considered for percutaneous renal revascularization.

Clinical management and medical therapy

Patients with known renovascular disease should be managed aggressively. The goals of therapy should be normalization of blood pressure, preservation of renal function and prevention of cardiovascular events.[31] The use of multiple medications to control blood pressure is often warranted in patients with RAS. However, lowering the blood pressure too much in patients with RAS may hinder renal perfusion. Most nephrologists will aim for a blood pressure of 140/90 mmHg although data on specific BP targets in this population are lacking. An ideal regimen includes an **angiotensin converting enzyme inhibitor** (**ACE-I**) or **angiotensin receptor blocker** (**ARB**), which directly counter the activation of the renin-angiotensin system. These agents should be used with caution in patients with significant bilateral renal artery disease or with a solitary kidney as they can decrease renal perfusion.[32] A diuretic is frequently employed in this setting to counter intravascular volume overload. Monitoring of electrolytes and creatinine is essential. In patients with concominant renal dysfunction, nephrotoxic agents and nephrotoxic medications should be avoided. Medical therapy should also include aggressive management of atherosclerotic disease and cardiovascular risk factors. In patients with ARAS, therapy should include aggressive lipid management, aspirin or anti-platelet agents, antihypertensive therapy, aggressive blood sugar control in diabetics, and smoking cessation. A comprehensive history should be obtained in patients with RAS to evaluate for coronary artery disease, cerebrovascular disease and peripheral arterial disease. Patients should be monitored closely for progression of RAS or failure of medical therapy.

Patients with hypertension and FMD can initially be managed medically, but the clinician should have a low threshold for referral for angiography and angioplasty since the success rate of revascularization and improvement in blood pressure control in this patient subset is very high.[27]

Revascularization

Patients with clinically significant RAS due to FMD are almost always referred for revascularization procedures; however, significant controversy exists about the role of revascularization in pa-

tients with ARAS.[35,36] Revascularization can be achieved surgically or endovascularly with **percutaneous transluminal renal angioplasty (PTRA)** and possible stenting.

Surgery

Due to the advent of PTRA and the excellent results with stenting, the use of surgical revascularization is now limited to those individuals who have failed PTRA, who have complex anatomy not amenable to PTRA, or have concominant abdominal aortic disease that warrants surgical repair (such as a abdominal aortic aneurysm).

Endovascular

The use of PTRA has largely replaced surgical techniques due to their less invasive nature with faster recovery times and decreased morbidity. The addition of stenting to PTRA has significantly improved procedural success rates and provided improved long term outcomes with less need for repeat revascularization.[37] Endovascular techniques continue to improve. The use of filter guide wires can limit embolization of atheroma into the distal renal arterioles. Stenting is used mainly for ARAS at the ostium or proximal third of the main renal or accessory renal arteries, whereas balloon angioplasty alone has excellent success and a sustained benefit for FMD.[27]

Significant controversy exists about the role of revascularization in patients with ARAS. Several studies have evaluated medical therapy versus surgery or PTRA.[38] Most do not include the use of modern aggressive medical therapy nor do they represent modern endovascular therapy techniques with the use of stenting and distal protection devices. PTRA alone without stenting is limited by high restenosis rates, and randomized trials have suffered from small sample size and high crossover rates from medical therapy to PTRA. Randomized trials with PTRA and stenting have shown improved blood pressure control.[38] The 2005 ACC/AHA guidelines on the management of peripheral arterial disease address the current expert opinion from multiple professional societies on the role of renal revascularization.[31] (Figure 3) The anatomy of the lesion and the clinical status of the patient must be considered.

Anatomically, lesions are considered significant if they are greater than 70% stenotic or if they are 50-70% stenotic with a pressure gradient greater than 20mmHg measured across them at the time of angiography. Lesions with doppler velocities greater than 300cm/second by U/S are considered hemodynamically significant as well. Clinically symptomatic patients with unilateral or bilateral disease may be considered for revascularization. It is less clear if asymptomatic patients with significant unilateral disease and two functioning kidneys will benefit from revascularization. PTRA is usually performed in patients with FMD even if the lesions appear less than 70% stenotic as the true anatomic caliber of the vessel is often underestimated and clinical improvement can occur in patients with lesions that appear mildly obstructive.

Factors predicting a poor outcome from PTRA with or without stenting include patients with known progressive intrinsic renal disease, known diabetic nephropathy with significant proteinuria, atrophic kidney (<7 cm), elevated renal resistive index (>80), and advanced renal failure (Cr > 3.5) since the likelihood of renal recovery is low.[31]

Due to the ongoing controversy about the role of renal revascularization in ARAS, ongoing randomized, controlled trials including the **CORAL (Cardiovascular Outcomes in Renal Atherosclerotic Lesions)**, **STAR (Stenting in Renal Dysfunction Caused by Atherosclerotic Renal Artery Stenosis)** and **ASTRAL (Angioplasty and Stent for Renal Artery Lesions)** trials will help to further define which patients are best treated with aggressive medical therapy versus medical therapy combined with modern day endovascular techniques.

References

1. Abud O, Chechile GE, Sole-Balcells F. Aneurysm and arteriovenous malformation. In: Novick AC, Scoble JE, Hamilton G, eds. *Renal Vascular Disease*. London, UK: WB Saunders Co, Ltd;1996:35-46.
2. Novick AC. Renal artery aneurysms and arteriovenous malformation.In: Novick AC, Straffon RA, eds. *Vascular Problems in Urologic Surgery* Phila-

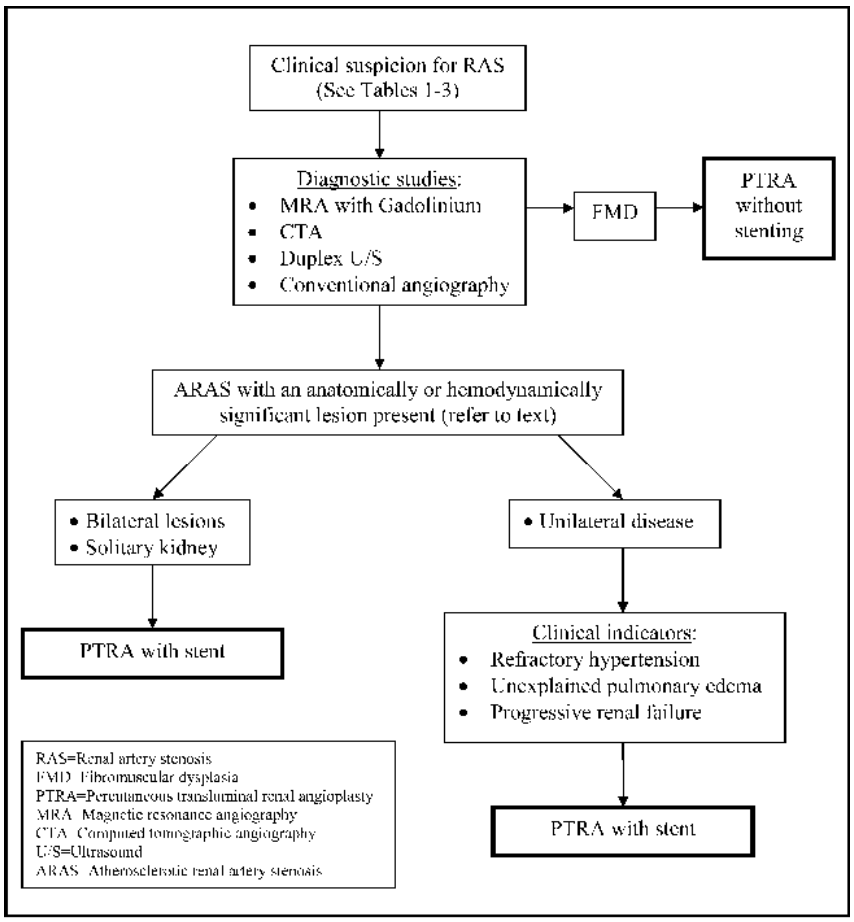

Figure 3. Algorithm for renal revascularization.

delphia, Pa: WB Saunders; 1982:189-204.
3. Poutasse EF. *J Urol.* 1975;113:443-9.
4. McCready RA, Hyde GL, et al. *Surg* 1983;93:306-12.
5. Guthaner DF, Schmitz L. *Radiol* 1982;144:77-8.
6. Andros G, Schneider PA, et al. *Cardiovasc Surg* 1996;4:135-42.
7. Ingelfinger JR, Newburger JW. *J Pediatr*. 1991;119:771-3.
8. Booth C, Preston R, et al. *Nephrol Dial Transplant* 2002;17:1235-40.
9. Courtel JV, Soto B, et al. *Pediatr Radiol* 1998;28:59-63.
10. Tyagi S, Singh B, et al. *Am Heart J* 1993;125(5 pt 1):1386-93.
11. Teoh MK. *Cardiovasc Surg* 1999;7:626-32.
12. Safian R, Textor S. *NEJM* 2001;344:431-42.
13. Kaplan N, *Kaplan's Clinical Hypertension*. 8th ed. Baltimore, Lippincott Williams & Wilkins, 2002, p 385.
14. Tollefson D, Ernst C. *J Vascul Surg* 1991;14:327-31.
15. Caps N, Perissontto C, et al. *Circulation* 1998;98:2866-72.
16. Wollenweber J, Sheps S, Davis G. *Am J Cardiol* 1968;21:60-71.
17. Meaney T, Dustan H, McCormack L. *Radiol* 1968;91:881-7.
18. Schreiber M, Pohl M, Novick A. *Urol Clin N Am* 1984;11:383-92
19. Hansen K, Edwards M, et al. *J Vascul Surg* 2002;36:443-51
20. Harding M, Smith L, et al. *J Am Society Nephrol* 1992;2:1608-16.
21. Olin J, Melia M, et al. *Lancet* 1990;88(1N):46N-51N.
22. Dean R, Kieffer R, et al. *Arch Surg* 1981;116:1408-15.
23. Guzman R, Zierler R et al. *Hypertension* 1994;23:346-50.
24. Crowley J, Santos R, et al. *Am Heart J* 1998;136:913-8.
25. Mailloux L, Bellucci A, et al. *Lancet* 1988;84:855-62.
26. Conlon P, Little M, et al. *Kidney Int* 2001;60:1490 –7
27. Slovut D, Olin J. Fibromuscular dysplasia. *N Engl J Med* 2004;350:1862-71.
28. Cloft H, Kallmes D, et al. *Journal of Neurosurgery* 1998;88:436-40.
29. Vensel L, Devereux R, et al. *Am J Cardiol* 1986;58:575-82.
30. Korner P. *Blood Pressure* 1995;2:6-16.
31. Hirsch, et al. *J Am Coll Cardiol*, 2006; 47:1-192.
32. *Brenner and Rector's The Kidney* (7th edition). Saunders 2004.
33. Kuo H, Kanal E, et al. *Radiol* 2007;242:647-9.
34. White C, Jaff M, et al. *Circulation.* 2006;114:1892-5.
35. Cooper C, Murphy T. *Circulation* 2007; 115: 263-70.
36. Dworkin L, Jamerson K. *Circulation* 2007; 115: 271-6.
37. Van de Ven P, Kaatee R, et al. *Lancet* 1999;353:282-6.
38. Balk E, Raman G, et al. *Ann Intern Med* 2006: 145: 901-12.

Richard A. Regnante, MD, is an Intervention Cardiology Fellow, The Miriam Hospital.

John Obell MD, is Assistant Professor Medicine, Division of Kidney Disease and Hypertension, The Warren Alpert Medical School of Brown University.

Paul Gordon MD, is Assistant Professor of Medicine, The Warren Alpert Medical School of Brown University.

Disclosure of Financial Interests

The authors have no financial interests to disclose.

CORRESONDENCE:
Richard A. Regnante, MD
The Miriam Hopsital
164 Summit Ave.
Providence, RI 02906
Phone: (401) 793-4102
e-mail: regnante@gmail.com