



Images In Medicine

Nonbacterial Thrombotic (Marantic) Endocarditis

Carlos J. Esteva, MD, Ronald A. DeLellis, MD, Lauren Hartman, MD

A 19-year-old man with aplastic anemia underwent a matched unrelated bone marrow transplant. He later developed severe complications including graft versus host disease, cytomegalovirus, aspergillus, herpes zoster and H1N1 influenza infections and dialysis dependant renal failure. His mental status fluctuated during his hospital stay and he required intensive support for multi-organ system dysfunction. Shortly after a CT scan, he was noted to have an episode of sudden chest pain following which he became unresponsive with unreactive pupils. Resuscitative measures were started, but after no response, efforts were terminated and the patient was pronounced dead.

Autopsy demonstrated cardiomegaly with biventricular hypertrophy and severe narrowing of the coronary arteries. Scattered areas of myocardial necrosis with surrounding foci of myocytolysis were present in the left ventricle. There was also evidence of nonbacterial thrombotic (marantic) endocarditis of the mitral valve.

NONBACTERIAL THROMBOTIC (MARANTIC) ENDOCARDITIS

In **nonbacterial thrombotic endocarditis (NBTE)** small sterile vegetations deposit on the leaflets or cusps of the cardiac valves, usually along the lines of closure. The vegetations are multiple and commonly measure less than 3mm in size. They are most frequently seen on the atrial surfaces of the mitral valve (Figure 1) but can be present on the atrial surfaces of the tricuspid valve and the ventricular surfaces of the aortic and pulmonary valves. Microscopically the vegetations consist of collections of fibrin and platelets that are loosely adherent to the valves. (Figure 2)

NBTE was previously known as marantic endocarditis, from the Greek *marantikos*, meaning “wasting”. It is found most frequently in patients with advanced malignancy (predominantly adenocarcinomas), but can be present in patients with sepsis or burns, indwelling pulmonary artery catheters, disseminated intravascular coagulation, or acquired immune deficiency syndrome. Endothelial damage and a hypercoagulable state are important etiologic factors. The vegetations are not associated with a local inflammatory response, and the clinical manifestations are usually those resulting from systemic embolization.

REFERENCES

1. Lopez AJ, Ross RS, et al. Nonbacterial thrombotic endocarditis. *Am Heart J* 1987;113:773-84.
2. Ian I. Joffe, et al. . Noninfective valvular masses. *Am Heart J* 1996;131:1175-83.

Carlos Esteva, MD, PGY1, is a Resident in the Department of Pathology, Rhode Island Hospital and the Warren Alpert Medical School of Brown University.

Ronald DeLellis, MD, Pathologist-in-chief at the Rhode Island Hospital and The Miriam Hospital and Professor and Associate Chair of the Department of Pathology and Laboratory Medicine at the Warren Alpert Medical School of Brown University.

Lauren Hartman, MD, PGY4, is a Resident in the Department of Pediatrics, Rhode Island Hospital and the Warren Alpert Medical School of Brown University.

Disclosure of Financial Interests

The authors and spouses/significant others have no financial interests to disclose.

CORRESPONDENCE

Carlos J. Esteva, MD
cesteva@lifespan.org

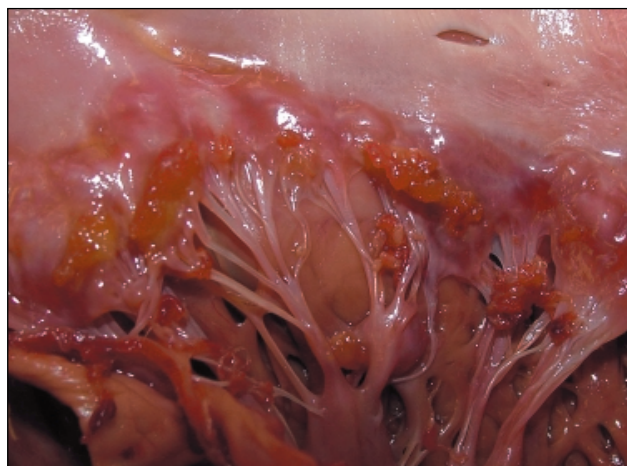

Figure 1.

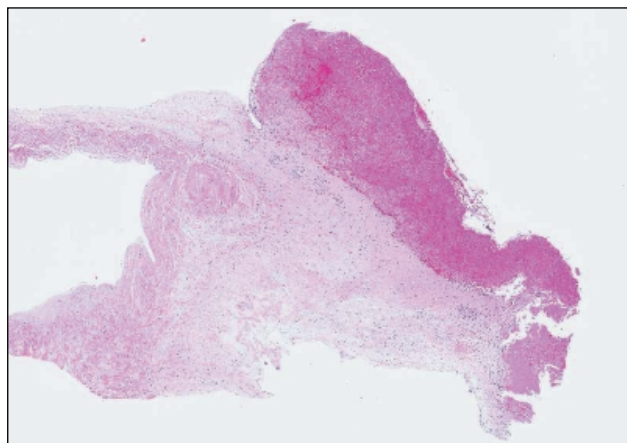


Figure 2.