

Cardiac Manifestations of Lyme Disease

Thomas J. Earl, MD

CASE 1

A 15-year old man with no significant medical history presented to the emergency department following two episodes of syncope. He was in his usual state of good health until earlier on the day of admission when he awoke with a severe headache, shortly followed by a syncopal episode with brief loss of consciousness. Later that same day, he experienced a second syncopal episode and subsequently sought medical attention.

On arrival to the emergency department, he was afebrile and hemodynamically stable. Physical examination was notable for irregular and bradycardic heart sounds without murmurs, rubs, or gallops. **Electrocardiogram (ECG)** (Figure 1) revealed complete heart block with a narrow QRS complex. Transthoracic echocardiogram showed normal biventricular size and function and mild mitral regurgitation. There was no pericardial effusion visualized. He was given intravenous ceftriaxone for presumed Lyme carditis and transferred to the Coronary Care Unit for monitoring and treatment.

Shortly after admission, telemetry monitoring revealed progressively lower heart rates requiring transcutaneous and eventual transvenous pacing. He was continued on ceftriaxone. Subsequent ECGs showed progression from complete heart block, to 2:1 **atrioventricular (AV)** block, and eventually sinus rhythm with first degree AV block. (Figure 2) Subsequent laboratory data revealed elevated Lyme IgM and IgG antibodies.

With improvement in his native conduction the transvenous pacing wire was removed. He was discharged home to complete a twenty-eight day course of ceftriaxone and remained well in follow-up.

CASE 2

A 34-year old man with no significant medical history presented to the emergency department with pleuritic chest pain. Approximately five weeks prior to presentation he developed fevers, a "bull's-eye" type rash, and Bell's palsy. Serologic workup at an outside hospital

was notable for elevated Lyme antibody titres. He was prescribed doxycycline but discontinued it after 3 days after experiencing nausea and vomiting.

On presentation to our institution, initial workup was notable for an ECG (Figure 3) showing diffuse, upsloping ST-

segment elevations without reciprocal depressions along with subtle PR-segment depressions. Serial cardiac biomarkers were negative. Transthoracic echocardiogram revealed normal biventricular size and systolic function without a pericardial effusion.

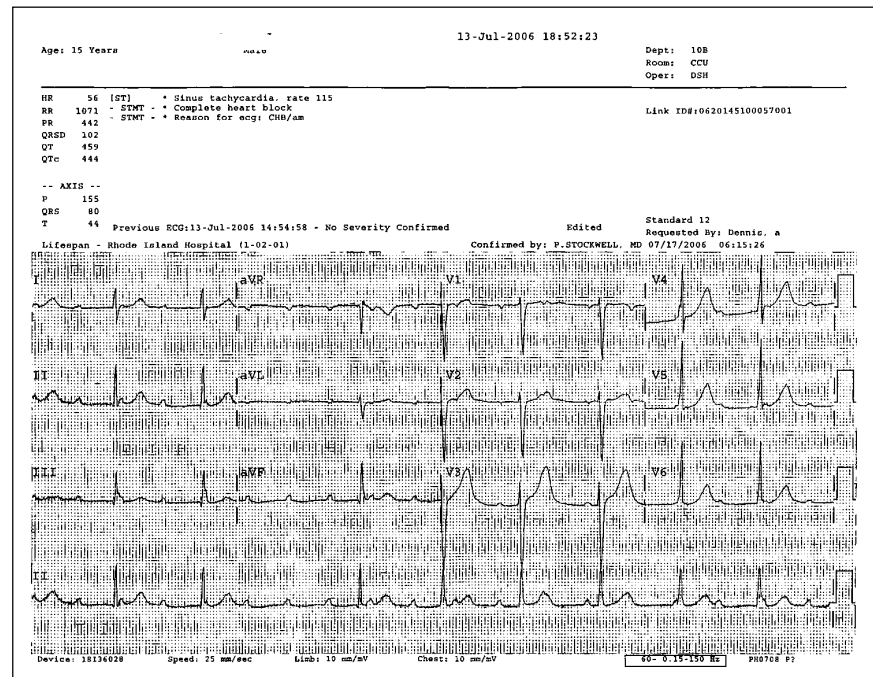


Figure 1. 12-lead ECG showing complete heart block with a narrow QRS complex.

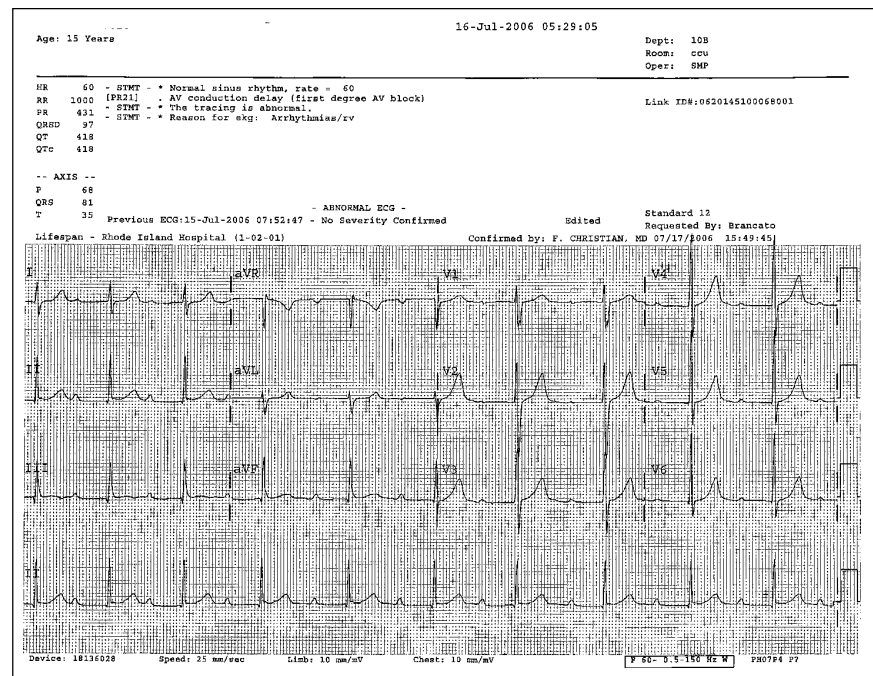


Figure 2. 12-lead ECG showing sinus rhythm with a first-degree AV block.

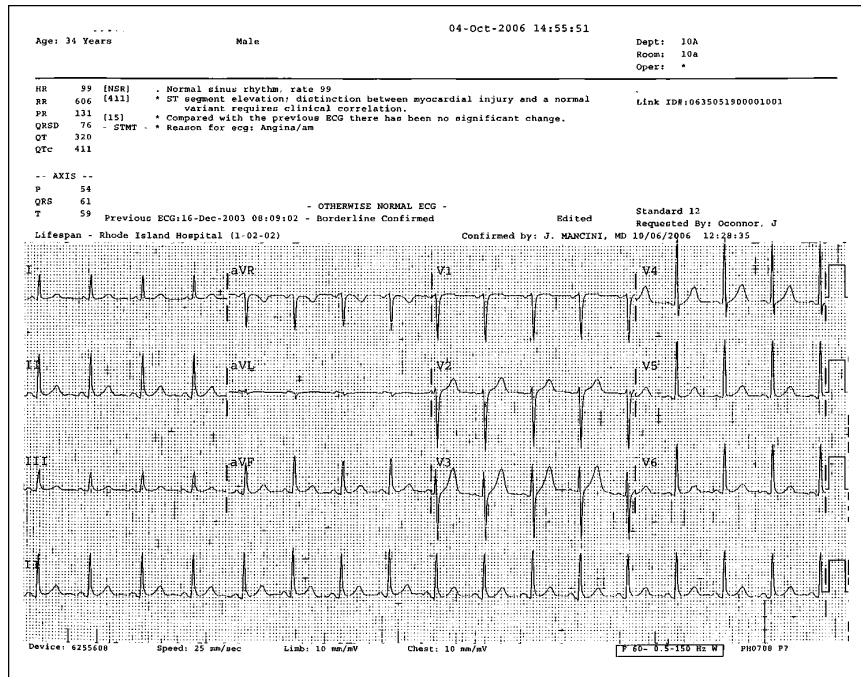


Figure 3. 12-lead ECG showing sinus rhythm with diffuse, upsloping ST-segment elevations as well PR-segment depressions in the inferior leads.

Given his clinical presentation and recent serologic data he was started on intravenous ceftriaxone for a diagnosis of Lyme pericarditis. Treatment was continued for a total of twenty-eight days. He was treated with NSAIDs and opiate analgesics with eventual relief of his pain. At the time of completion of antibiotic therapy he was without chest pain.

DISCUSSION

Lyme disease, a tick-borne illness first described in Connecticut in 1977, is currently the most commonly reported vector-borne illness in the United States. In this country, Lyme disease is caused by the spirochete *Borrelia burgdorferi*, which is transmitted by the bite of Ixodes tick. According to the Centers for Disease Control and Prevention (CDC), the incidence of Lyme disease in Rhode Island in 2008 was 17.7 (confirmed cases per 100,000 persons), with peak reporting in the mid and late summer months.^{1,2} The majority of patients present with the classic rash of Lyme disease, erythema migrans, and/or arthritis, while a small minority experience cardiac manifestations of the disease.³

Cardiac manifestations of Lyme disease are typically seen in the early-disseminated phase (Stage 2) of the illness, with approximately 5% of untreated patients having cardiac involvement within the

first few weeks after disease onset.⁴ Despite a slightly higher incidence of Lyme disease in females, there is a 3:1 male-to-female predominance of Lyme carditis. The spectrum of cardiac involvement in Lyme disease is highly variable, ranging from asymptomatic to severe manifestations. Notably, early recognition of infection and prompt administration of antibiotic therapy is thought to decrease the likelihood of cardiac involvement, although to my knowledge there are no randomized trials demonstrating a clinical benefit of antibiotics in terms of duration or severity of cardiac symptoms.⁵ Clinical manifestations of Lyme carditis include syncope or pre-syncope, palpitations, dyspnea, and/or chest pain. Cardiac abnormalities in Lyme disease most commonly include varying degrees of AV block and/or myopericarditis.

Steere et al reported twenty patients with cardiac manifestations of Lyme disease in 1980. Within this group, eighteen patients developed fluctuating degrees of AV block, with eight patients developing complete heart block. Interestingly, the degree of AV block was noted to fluctuate even over the course of minutes.⁶ Electrophysiology studies performed on select patients with Lyme carditis from van der Linde's series revealed diffuse conduction system involvement, with the majority of patients dem-

onstrating prolonged A-H intervals suggestive of AV nodal involvement.⁷ There is typically no response to atropine in acquired AV block attributed to Lyme disease, suggesting direct involvement of the conduction system as opposed to increased vagal tone.

Fortunately, acquired AV block in Lyme carditis is typically transient and resolves with antibiotic therapy. This is demonstrated in Case 1 in which a rapid improvement in native conduction was observed. The need for temporary pacing is not uncommon, but persistent AV block necessitating permanent pacemaker placement is rare. In a retrospective study of 105 patients with documented Lyme carditis, 35% of patients required temporary pacing, while only five patients went on to receive a permanent pacemaker. Among these patients receiving a permanent pacemaker, four were noted to have resolution of their conduction system disease, while one remained pacer-dependent.⁷

Following conduction system disease, Lyme carditis most commonly manifests as myopericarditis. Steere et al described ECG abnormalities suggestive of myocardial involvement such as ST-segment depressions, T-wave inversions, and/or intraventricular conduction delays in thirteen of twenty patients. Of note, all of the observed abnormalities resolved over time. Furthermore, three patients were observed to have mild left ventricular (LV) systolic dysfunction by radionuclide imaging during the active phase of the disease; all had normalization of LV systolic function on repeat imaging when the disease was in remission.⁶ Several case reports and small cohort studies have additionally described patients with clinical and ECG evidence of pericarditis.⁸⁻¹¹ Finally, Lyme disease has been purported to play a causative role in the development of a dilated cardiomyopathy and/or chronic congestive heart failure following small European studies showing higher rates of seropositivity in patients with an idiopathic dilated cardiomyopathy as compared to controls as well as the ability to grow *B burgdorferi* from endomyocardial biopsy specimens taken from a small cohort of patients with an idiopathic dilated cardiomyopathy.^{12,13} To date, similar findings have not been replicated in the United States.

The diagnosis of Lyme carditis is typically established through a combination of clinical presentation, serologic data, and non-invasive cardiac testing. A directed history should focus on potential tick exposures as well as current or antecedent erythema migrans. In Steere's cohort, eighteen of the twenty patients described erythema migrans at some point in the disease course, while fifteen had the classic skin manifestation at the time that cardiac involvement was recognized.⁶ Of note, cardiac disease as the sole manifestation of Lyme disease has also been reported.¹⁴ Suspicion of Lyme carditis is confirmed with serologic testing.

Guidelines from the Infectious Diseases Society of America suggest that patients with Lyme disease and AV block and/or myopericarditis be treated with either oral or parenteral antibiotics for fourteen days. For hospitalized patients, a parenteral antibiotic is the preferred initial choice. Preferred oral antibiotics include amoxicillin, doxycycline, or cefuroxime axetil, while ceftriaxone is the suggested parenteral antibiotic of choice.¹⁵

In summary, Lyme disease is an uncommon but readily reversible cause of a variety of cardiac complications, most notably AV block. The diagnosis of Lyme carditis requires a high index of suspicion, especially in the absence of the antecedent skin rash typically seen in Lyme disease. For clinicians practicing in an endemic area, the differential diagnosis of newly recognized AV block should include Lyme disease. As demonstrated by our two patients, cardiac manifestations of Lyme disease are typically reversible and patients recover completely without any long-term sequelae.

REFERENCES

1. Reported Lyme disease cases by state, 1999-2008. Division of Vector-Borne Infectious Diseases. www.cdc.gov.
2. Reported Cases of Lyme Disease by Month of Illness Onset United States, 1992-2004. Division of Vector-Borne Infectious Diseases. www.cdc.gov.
3. Reported Clinical Findings Among Lyme Disease Patients, 1992-2004. Division of Vector-Borne Infectious Diseases. www.cdc.gov.
4. Steere AC. Lyme disease. *NEJM* 1989;321:586-96.
5. Sangha O, Phillips CB, et al. Lack of cardiac manifestations among patients with previously treated Lyme disease. *Ann Intern Med* 1998;128:346-53.
6. Steere AC, Batsford WP, et al. Lyme carditis. *Ann Intern Med* 1980;93:8-16.
7. van der Linde MR. Lyme carditis. *Scand J Infect Dis Suppl* 1991;77:81-4.
8. Horowitz HW, Belkin RN. Acute myopericarditis resulting from Lyme disease. *Am Heart J* 1995;130:176-8.
9. Lorcerie B, Boutron MC, et al. Pericardial manifestations of Lyme disease. *Ann Med Interne (Paris)* 1987;138:601-3.
10. Bruyn GA, De Koning J, et al. Lyme pericarditis leading to tamponade. *Br J Rheumatol* 1994;33:862-6.
11. Veyssier P, Davous N, Kaloustian E, et al. Cardiac involvement in Lyme disease. 2 cases. *Rev Med Interne* 1987;8:357-60.
12. Stanek G, Klein J, et al. *Borrelia burgdorferi* as an etiologic agent in chronic heart failure? *Scand J Infect Dis Suppl* 1991;77:85-7.
13. Lardieri G, Salvi A, et al. Isolation of *Borrelia burgdorferi* from myocardium. *Lancet* 1993;342:490.
14. Kimball SA, Janson PA, LaRaia PJ. Complete heart block as the sole presentation of Lyme disease. *Arch Intern Med* 1989;149:1897-8.
15. Wormser GP, Dattwyler RJ, et al. The Clinical Assessment, Treatment, and Prevention of Lyme Disease, Human Granulocytic Anaplasmosis, and Babesiosis: Clinical Practice Guidelines by the Infectious Diseases Society of America. *Clin Infect Dis* 2006;4:1089-134.

Thomas J. Earl, MD, is a Fellow in Cardiovascular Medicine, Rhode Island Hospital and The Miriam Hospital/The Warren Alpert Medical School of Brown University.

Disclosure of Financial Interests

The author and/or spouse/significant other has no financial interests to report.

CORRESPONDENCE

Thomas J. Earl, MD
Rhode Island Hospital
593 Eddy St, room 209
Main Building, Room 209
Providence, RI 02903
Phone: (401) 862-6179
E-mail: tearl@lifespan.org

