

Digital and Thumb Arthroplasty as Treatment for Arthritis of the Hand

Edward Akelman, MD, and Arnold-Peter C Weiss, MD

OSTEOARTHRITIS OF THE HAND IS A COMMON medical diagnosis made in patients seen in a primary care, rheumatologic, and orthopedic practice.¹ The hand is an extremely common site of this disease. This diagnosis primarily affects the thumb carpometacarpal joint, as well as the finger distal interphalangeal and proximal interphalangeal joints. Patients with hand osteoarthritis have bony nodules at the distal interphalangeal joint called Heberden's nodes. These prominences may initially be painful, but pain generally improves over time. Patients may also present with ganglion cysts of the distal interphalangeal joint called mucous cysts. Bony nodules at the PIP joints are also seen, although less frequently, and these are called Bouchard's nodes.

Idiopathic thumb carpo-metacarpal osteoarthritis occurs most commonly in women between the ages of 40 and 75 years. (Figure 1) Thumb osteoarthritis may also be caused by joint and ligament factors that may cause instability, subluxation, and subsequent arthritis. Patients complain of pain at the base of the thumb with functional activities such as pinch and grip. This usually starts with activity, but at later disease stages may be present at rest. There are other common functional symptom complaints such as difficulty in taking tops off of jars, turning keys,

or opening doors. In the digits, patients with osteoarthritis initially describe joint stiffness, with loss of digital motion, and subsequent pain with finger use. Pinch and grip strength may be diminished secondary to pain and limited motion. Diagnosis of these conditions is made by physical exam and radiographs. Radiographs generally show findings of joint space narrowing, osteophytes, as well as angular deformities.

Initial conservative care of hand osteoarthritis consists of the use of heat, non-steroidal anti-inflammatory medicines, and splinting. The use of corticosteroid injections in affected joints may be appropriate for later treatment and improve pain relief, but is never permanent.

Rheumatoid arthritis is a systemic autoimmune medical inflammatory condition that affects the synovium surrounding the joints.¹ In the hand, it primarily affects the metacarpal-phalangeal joints, although other joints may be involved. Patients with rheumatoid arthritis of the hand complain of loss of strength, morning stiffness, difficulty with function because of poor digital positioning, and deformity. Physical exam will generally demonstrate ulnar deviation of the digits at the metacarpal phalangeal joints as well as volar subluxation. Patients may present with fusiform swelling of digital joints, described as bogginess.

Flexion deformities can be seen at the PIP joint, or patients may present with hyperextension deformities at the PIP joint called swan-neck deformities. Diagnosis is made by physical exam and radiograph. Radiographs typically show metacarpal-phalangeal subluxation with ulnar deviation deformity of the digits.

Major strides have been made in the medical treatment of rheumatoid arthritis. Newer generation **disease-modifying anti-rheumatic drugs (DMARDs)** have been shown to decrease pain and diminish disease progression in affected joints. Conservative treatment also involves the use of resting splints, especially night, as well as functional splints that can be used during the day.

OSTEOARTHRITIS— THUMB CARPOMETACARPAL (CMC) JOINT

Surgical treatment of thumb CMC joint osteoarthritis includes arthrodesis, arthroscopy, suspension/ligamento-taxis, interposition arthroplasty, or prosthetic joint replacement.^{2,3} Prosthetic joint replacement of the thumb CMC joint has been infrequently used to treat CMC arthritis due to the reported complications of aseptic loosening and soft tissue and foreign body reaction to implants. Newer implants have been recently introduced, but long-term studies are not yet available to see if these implants have diminished previous complication rates.

Currently, the most commonly used surgical procedures to treat thumb CMC osteoarthritis are soft tissue arthroplasty procedures which include resection of the trapezium with or without ligament reconstruction using either the flexor carpi radialis tendon, the extensor carpi radialis longus tendon or the abductor pollicis longus tendon. Alternatively suspensionplasties using tendons or suture materials have been devised to hold the thumb metacarpal out to length. Removing the trapezium allows the base of the thumb metacarpal to articulate against a soft tissue mass/scar with or without ligamentous reconstruction, eliminating painful bone on bone contact. This type of procedure, first popularized by Carroll, Littler, and Eaton^{4,5} in the United States has been used for over 50 years with excellent results. Large prospective randomized series of surgical treatment comparisons have as yet not been able to determine a difference in outcome between these

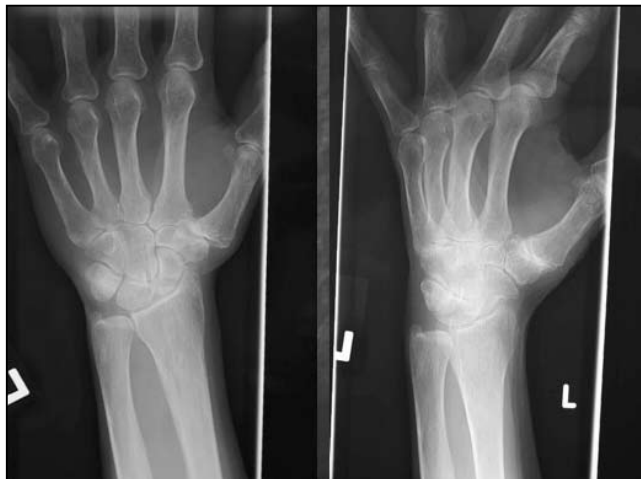

Figure 1. Radiographic appearance of osteoarthritis of the thumb carpometacarpal joint.

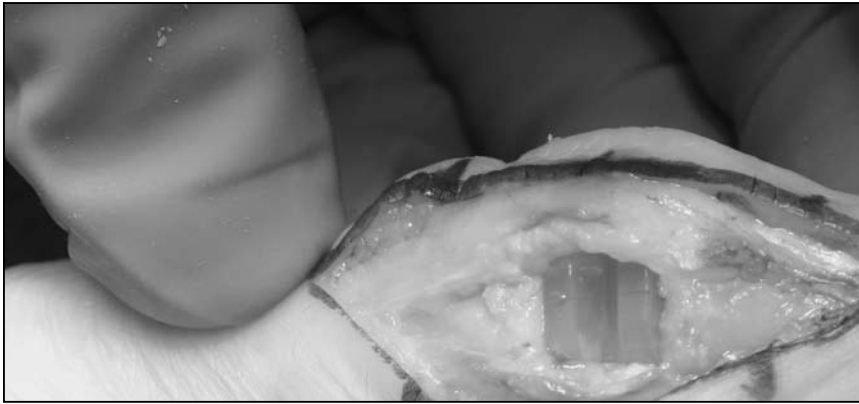


Figure 2. Implant silastic arthroplasty for pip osteoarthritis.

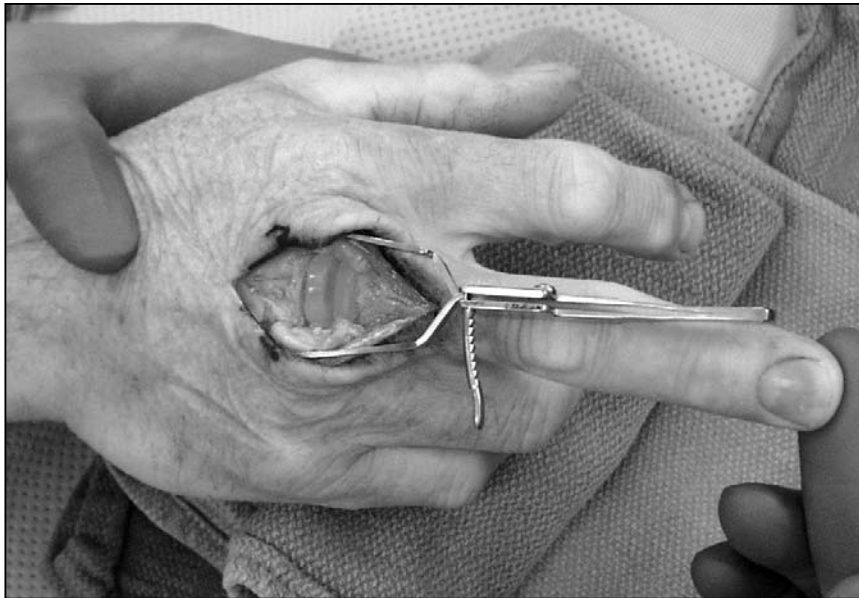

Figure 3 Silastic arthroplasty MCP joint with implant in place.

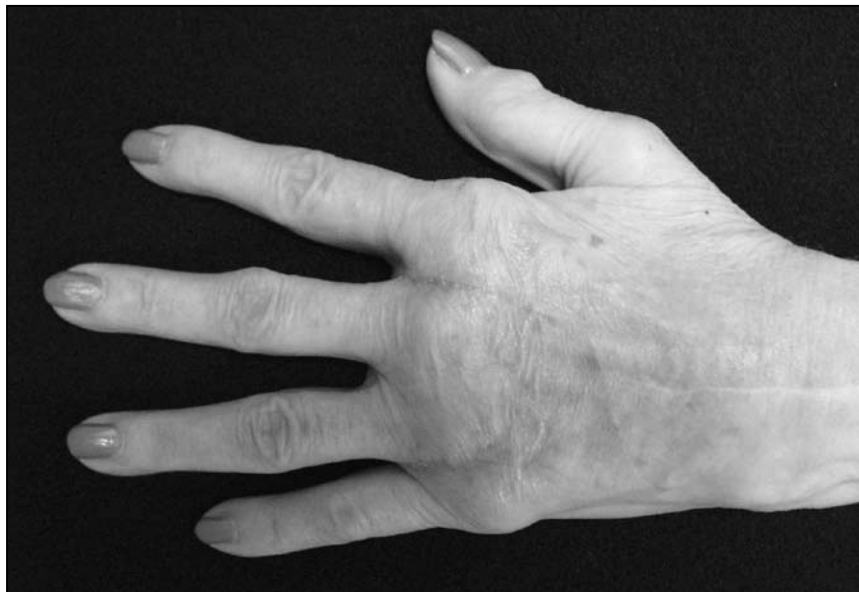

Figure 4 Clinical appearance with silastic arthroplasty in place.

different soft tissue procedures.⁶ Surgery in these patients failing conservative care has given excellent outcomes for pain relief, improved function, and patient satisfaction.

OSTEOARTHRITIS—DISTAL INTERPHALANGEAL JOINT (DIP)/ PROXIMAL INTERPHALANGEAL JOINT (PIP)

DIP joint arthritis may cause severe pain, and may not respond to conservative care including splinting, nonsteroidal anti-inflammatory drugs, or cortisone injection. Long-term follow-up studies of silicone arthroplasty replacement of the DIP joint have not been frequently reported. Wilgis⁷ reviewed 38 joints treated by silicone arthroplasty over a ten year period. In this series less than 10% of the implants needed to be removed. Soft tissue arthroplasty of the DIP may be accomplished by surgically exploring the joint and removing dorsal osteophytes on the proximal portion of the distal phalanx and the distal portion of the middle phalanx. This surgical procedure has not been well studied, but has worked well in selected patients. Long-term relief of severe pain and deformity in this patient population is best provided by DIP joint arthrodesis using screw fixation.

PIP joint osteoarthritis may be treated in the patient failing conservative care with either PIP joint arthrodesis or arthroplasty. Arthroplasty is done in this joint by a dorsal approach, resecting both arthritic sides of the joint, and placing an implant that bridges the joint. (Figure 2) PIP joint silastic arthroplasty has been used for 50 years treating this condition. There has been some concern regarding long-term results with implant failure. A recent study of 70 implants followed for over six years demonstrated 11 implant fractures.⁸ Another study using a different implant appeared to show lower implant failure rates.⁹ Much research has been done on other types of implants including those using Pyro carbon as well as those based on cobalt chrome on polyethylene articulations. Pyrolytic carbon arthroplasty appears to show some similar outcome measures at early follow up compared with silicone implants, but concerns have been raised regarding loosening, squeaking, and rates of dislocation. Metal on polyethylene joint implants have

not been followed long-term, although there has been concern raised regarding the possibility of wear debris.

RHEUMATOID ARTHRITIS— METACARPOPHALANGEAL (MCP) JOINT REPLACEMENT ARTHROPLASTY

Patients with involvement of the MCP joints of the hand with the diagnosis of rheumatoid arthritis are initially treated medically, with the use of supporting splinting, especially at night, being most helpful. When ulnar deviation and subluxation deformities occur, these are best treated with replacement arthroplasty.^{10,11} Surgery is done dorsally, with resection of the involved joint, joint replacement, and soft tissue and tendon stabilization procedures done around and for the affected joint. (Figure 3 and 4) Implants made from silicone are most commonly used to replace all four joints. Hand therapy protocols are instituted after soft tissue healing to improve range of motion. Recent outcome studies by Chung have shown considerable improvement of patient function, patient satisfaction as well as hand appearance at one year after surgical MCP joint replacement when compared with a similar group of patients treated medically.¹²

MCP joint arthroplasty in rheumatoid patients appears to maintain correction of ulnar drift. This requires appropriately stabilized soft tissue, centralization of tendons, and bone resection. Patient followed long term after silicone arthroplasty do appear to have implant fractures over time. Trail retrospectively reviewed 1,000 silicone MCP arthroplasty done over a 17 year period.¹³ Implants fractured at a rate of 42% at ten years and 66% at 17 years. Revision arthroplasty rates were 17% at ten years and 37% at 17 years. Revision surgery has excellent outcomes, and patient satisfaction with this procedure is high. It is hoped that new manufacturing techniques and hinge designs may improve upon these good outcomes.

REFERENCES

1. *Essentials of Musculoskeletal Care*, American Academy of Orthopedic Surgeons, John F Sarwark, MD, editor. 2010;397–427.
2. Jacobs BJ, Verbruggen G, Kaufmann RA. Proximal interphalangeal joint arthritis; *J Hand Surg.* 2010;35A:2107–16.
3. Kapoutsis DV, Dardas A, Day CS. Carpometacarpal and Scaphotrapezotrapezoid Arthritis: Arthroscopy, Arthroplasty, and Arthrodesis. *J Hand Surg.* 2011;36A:354–66.
4. Escott BG, Ronald K, Judd MGP, Bogoch ER. Neuflex and Swanson Metacarpophalangeal implants for rheumatoid arthritis: prospective randomized, controlled clinical trial. *J of Hand Surg.* 2010;35A:44–51.
5. Rizzo M. Metacarpophalangeal joint arthritis. *J Hand Surg.* 2011;36A:345–53.
6. Wilgis EF. Distal interphalangeal joint silicone inter-positional arthroplasty of the hand. *Clin Orthop Relat Res.* 1997 Sep;(342):38–41.
7. Shuler MS, Luria S, Trumble TE. Basal Joint Arthritis of the Thumb. *J AM Acad Orthop Surg.* 2008;16:418–23.
8. Chung KC, Burns PB, Wilgis EF, Burke FD, Regan M, Kim HM, et al. A multicenter clinical trial in rheumatoid arthritis comparing silicone metacarpophalangeal joint arthroplasty with medical treatment. *J Hand Surg.* 2009;34A:815–23.
9. Trail IA, Martin JA, Nuttall D, Stanley JK. Seventeen-year survivorship analysis of Silastic metacarpophalangeal joint replacement. *J Bone Joint Surg.* 2004;86B:1002–6.
10. Barron OA, Glickel SZ, Eaton RG. Basal joint arthritis of the thumb. *J Am Acad Orthop Surg.* 2000;8(5):314–23.
11. Froimson A. Tendon interposition arthroplasty of the trapeziometacarpal joint. *Clin Orthop Relat Res.* 1970;70:191–9.
12. Nylén S, Johnson A, Rosenquist AM. Trapeziectomy and ligament reconstruction for osteoarthritis of the base of the thumb: a prospective study of 100 operations. *J Hand Surg Br.* 1993;18(5):616–9.
13. Takigawa S, Meletiou S, Sauerbier M, Cooney WP. Long-term assessment of Swanson implant arthroplasty in the proximal interphalangeal joint of the hand. *J Hand Surg.* 2004;29A:785–95.
14. Namdari S, Weiss AP. Anatomically neutral silicone small joint arthroplasty for osteoarthritis. *J Hand Surg.* 2009; 34A: 292–300.

Edward Akelman, MD, is Professor and Vice Chairman of Orthopaedics at the Warren Alpert Medical School of Brown University, and the head of the Division of Hand, Upper Extremity and Microvascular Surgery of the Department of Orthopaedics at Rhode Island Hospital.

Arnold-Peter C. Weiss, MD, is a Professor of Orthopaedics and Dean of Admissions at The Warren Alpert Medical School of Brown University, and a staff surgeon in the Division of Hand, Upper Extremity and Microvascular Surgery of the Department of Orthopaedics at Rhode Island Hospital.

Disclosure of Financial Interests

Edward Akelman, MD, does not have any financial interest to disclose.

Peter-Arnold C. Weiss, MD, has financial interest in DePuy, Inc.

CORRESPONDENCE

Edward Akelman, MD
University Orthopedics, Inc.
2 Dudley St., Suite 200
Providence, RI 02905
e-mail: edward_akelman@brown.edu

