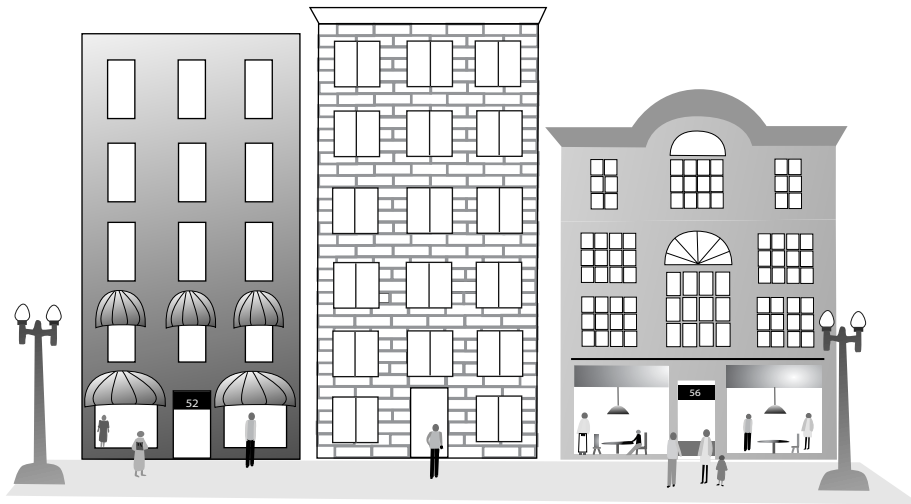

Medicine Health RHODE ISLAND



Orthopaedics & Joint Replacement

We're not LIKE A Good Neighbor,
WE ARE
The Good Neighbor Alliance



Specializing in Employee Benefits since 1982

Health Dental Life Disability Long Term Care
Pension Plans Workers' Compensation Section 125 Plans



The Good Neighbor Alliance Corporation

The Benefits Specialist

Affiliated with

**RHODE ISLAND
MEDICAL SOCIETY**



**RIMS-INSURANCE
BROKERAGE
CORPORATION**

401-828-7800 or 1-800-462-1910

P.O. Box 1421 Coventry, RI 02816

www.goodneighborall.com

**UNDER THE JOINT
SPONSORSHIP OF:**

The Warren Alpert Medical School of
Brown University
Edward J. Wing, MD, Dean of Medicine
& Biological Science

Rhode Island Department of Health
Michael Fine, MD, Director

Quality Partners of Rhode Island
Richard W. Besdine, MD, Chief
Medical Officer

Rhode Island Medical Society
Nitin S. Damle, MD, President

EDITORIAL STAFF

Joseph H. Friedman, MD
Editor-in-Chief

Sun Ho Ahn, MD
Associate Editor

John Teehan
Managing Editor

Stanley M. Aronson, MD, MPH
Editor Emeritus

EDITORIAL BOARD

Stanley M. Aronson, MD, MPH
John J. Cronan, MD
James P. Crowley, MD
Edward R. Feller, MD
John P. Fulton, PhD
Peter A. Hollmann, MD
Anthony E. Mega, MD
Marguerite A. Neill, MD
Frank J. Schaberg, Jr., MD
Lawrence W. Vernaglia, JD, MPH
Newell E. Warde, PhD

OFFICERS

Nitin S. Damle, MD
President

Alyn L. Adrain, MD
President-Elect

Elaine C. Jones, MD
Vice President

Elizabeth B. Lange, MD
Secretary

Jerry Fingerut, MD
Treasurer

Gary Bubby, MD
Immediate Past President

DISTRICT & COUNTY PRESIDENTS

Geoffrey R. Hamilton, MD
Bristol County Medical Society

Robert G. Dinwoodie, DO
Kent County Medical Society

Rafael E. Padilla, MD
Pawtucket Medical Association

Patrick J. Sweeney, MD, MPH, PhD
Providence Medical Association

Nitin S. Damle, MD
Washington County Medical Society

Cover: "Nested Bird," mixed media, by Kim Ellery. Kim Ellery is an Experimental Expressionist Painter. She is also the Fine Arts Coordinator for the RIBA Home Show. Her work can be seen at Five Main in Wickford Rhode Island; Smyle on Main Street in East Greenwich, Rhode Island, and on her website www.kimelleryart.com.

Medicine & Health
RHODE ISLAND

VOLUME 95 No. 4 April 2012

PUBLICATION OF THE RHODE ISLAND MEDICAL SOCIETY

COMMENTARIES

- 98 Parkinson, Shaking Palsy MS#1817-010038. Reviewer Comments [April Fools]
Joseph H. Friedman, MD
- 99 April First Reflections on Diseases of the Future
Stanley M. Aronson, MD
- 100 The Rhode Island Medical Society's 200th Anniversary
Nitin S. Damle, MD, MS, FACP

CONTRIBUTIONS

SPECIAL ISSUE: ORTHOPAEDICS & JOINT REPLACEMENT

Guest Editor: *Theodore A. Blaine, MD*


- 101 Introduction: Arthritis and Joint Replacement – The Upper Extremities
Theodore A. Blaine, MD
- 102 Digital and Thumb Arthroplasty as Treatment for Arthritis of the Hand
Edward Akelman, MD, and Arnold-Peter C Weiss, MD
- 105 Cervical Spondylosis and Stenosis
Matthew McDonnell, MD, and Phillip Lucas, MD
- 110 Elbow Arthritis and Total Elbow Replacement
Lee A. Kaback, MD, Andrew Green, MD, and Theodore A. Blaine, MD
- 117 Total Wrist Replacement
Edward Akelman, MD, and Arnold-Peter C Weiss, MD
- 120 Glenohumeral Arthritis and Total Shoulder Replacement
Lee A. Kaback, MD, Andrew Green, MD, and Theodore A. Blaine, MD
- 125 Diagnosis and Management of Heel and Plantar Foot Pain
Gregory A. Sawyer, MD, Craig R. Lareau, MD, and Jon A. Mukand, MD, PhD

COLUMNS

- 129 HEALTH BY NUMBERS: Analysis of Blood Lead Screening Data (2008–2011) for Refugee Children in Rhode Island
Edwina Williams, Robert Vanderslice, PhD, and Carrie Bridges, MPH
- 131 PHYSICIAN'S LEXICON: A Lexical Bridge of Psighs
Stanley M. Aronson, MD
- 131 Vital Statistics
- 132 April Heritage

Medicine and Health/Rhode Island (USPS 464-820), a monthly publication, is owned and published by the Rhode Island Medical Society, 235 Promenade St., Suite 500, Providence, RI 02908. Phone: (401) 331-3207. Single copies \$5.00, individual subscriptions \$50.00 per year, and \$100 per year for institutional subscriptions. Published articles represent opinions of the authors and do not necessarily reflect the official policy of the Rhode Island Medical Society, unless clearly specified. Advertisements do not imply sponsorship or endorsement by the Rhode Island Medical Society. Periodicals postage paid at Providence, Rhode Island. ISSN 1086-5462. POSTMASTER: Send address changes to *Medicine and Health/Rhode Island*, 235 Promenade St., Suite 500, Providence, RI 02908. Classified Information: Cheryl Turcotte/Rhode Island Medical Society, phone: (401) 331-3207, fax: (401) 751-8050, e-mail: cturcotte@rimed.org. Information on permissions and reprints available from jteeahan@rimed.org.

Note: *Medicine & Health/Rhode Island* appears on www.rimed.org, under Publications.



Commentaries

Parkinson, Shaking Palsy MS#1817-010038. Reviewer Comments [April Fools]

Dear Mr. Parkinson:

I regret having to inform you that your paper: The Shaking Palsy, did not get through our extremely competitive and fastidious review process. Due to financial constraints which we're sure you understand, we have limited space and have had to limit our acceptance rate, now taking only the best 75% of submitted manuscripts. This is a high hurdle to overcome, given the large number of manuscripts that we receive. We do hope you'll find success in submitting your efforts elsewhere, although you may consider publishing this yourself as a monograph, given its length and narrow focus.

Reviewer 1

To the editors: I am expecting that you will credit me with at least three reviews for having read this gargantuan manuscript. In fact, I deserve and demand five CME credits. (I thought this journal had limits on word numbers. If it doesn't, it should) At least it was well written. I had a number of concerns, noted in the comments below for the author. In the interest of civility I have contained my criticisms but I wonder if the medical community might be better off if the author confined his investigations and theorizing to paleontology and geology.

To the author: this is certainly an interesting and thought provoking description. First of all I suggest reducing the length. You are much more likely to have the reader maintain interest if you shorten the discussion. You did an admirable job with the six case presentations, each of which took a small paragraph, yet the remainder of the work dwarfed what you actually had to say about these patients, who are, after all, at the heart of your thesis. It appears that you met some of them only once and others not at all. Please clarify your relationship and how you obtained your historical information.

I am concerned about your IRB approval. Did they know that you studied pa-

tients who were not in your practice and were even, apparently, accosted on the street?

I am concerned also by some of your verbiage. For example, "Involuntary tremulous motion, with lessened muscular power, in parts not in action and even when supported." Might it not be more expeditious to simply use the term "tremor at rest," or "resting tremor?" Why use 16 words when two will do? It is the great fallacy of our age that rococo descriptions are often substituted for the clear and pithy, oftentimes with the hidden goal of obfuscation, assuming these orotund phrases are taken for signs of erudition. This reader is not confused by this maneuver.

Could you be clearer when you describe the "senses and intellect being uninjured." Are you using the word "sense" as in "sensibilities" or do you mean the special senses (smell, taste, etc), or the perception of touch, heat, etc, as in sensation.

I must point out to you that this journal considers disorders of women to be almost as important as disorders of men, yet you make no mention of this condition affecting women. All six of your subjects were men. Do you believe the illness is limited to men or is it your opinion that afflicted women are of less interest? Perhaps you limit your practice as well as your observational skills to men? If so, please specify.

You describe the bowels becoming increasingly "torpid." Please define what you mean.

Your proposed treatment merits support for its scientific foundations, based as it is on your understanding of this severe affliction. If it does, indeed, initiate its deadly root in the medulla oblongata, then bloodletting in the upper neck makes a lot of sense, especially to be employed first, before the application of blistering poultices and then incisions to withdraw the disease's toxins via pus. However, I wonder how you balance this with your observation that, the resolution of the patients will seldom be sufficient to enable them to persevere

through the length of time which the proposed process will necessarily require." Shall I take this to mean that your treatments may retard disease progression but never lead to cure? If so, please state. While on this topic, I must note that you make no reference to treatment of the first six and only patients who you describe. Please clarify.

I am both perplexed and upset by the name you have provided for this condition. If palsied, how does it tremor? One might suppose, especially given the cases you describe towards the end of the manuscript, that, as the process continues, a patient may even be paralyzed, leading to the apparent contradictory descriptor of paralysis agitans! I think that the disorder I see more commonly in young women, with weakness of both legs and tremulous motion "in parts in action" in the arms is more accurately described as a "shaking palsy" than this illness. You even described several cases after the original six that had disorders involving shaking palsies, although none quite like the first six. I therefore strongly suggest that you alter the name you have chosen for this illness. Perhaps a more appropriate name would be The Bent Spine With Tremor Illness, or, following your own line of argument, Sceletyre Festinans cum Tremor? I strongly suggest that you take the issue of naming the disease up with the Royal Academy's subcommittee on disease naming, since they are soon meeting to consider the next revision of the *Empire's Classification of the Diseases of Man, Edition 3, Revised Text XL 3*.

As a final comment, meant to improve the tenor of your argument, I strongly suggest that you not refer to yourself in the third person. It has a very off-putting effect on this reader.

— JOSEPH H. FRIEDMAN, MD

Disclosure of Financial Interests

Lectures: Teva, Ingelheim Boehringer; General Electric

Consulting: United Biosource; Buba-loo, Halsted, Reitman LLC; EMD Serono; Genzyme; Teva; Acadia; Addex Pharm; Schwarz Pharma

Research: MJFox; NIH: Cephalon; EMD Serono; Teva; Acadia

Royalties: Demos Press

CORRESPONDENCE

e-mail: joseph_friedman@brown.edu

April First Reflections on Diseases of the Future

WHEN WRITING ABOUT PAST EVENTS, THE HISTORIAN MUST EMPLOY verifiable facts. The criteria for writing competent narratives about future events, however, must abide by even more stringent rules. Such futuristic narratives must combine the skills of extrapolation with feasible speculation to generate a story that is both innovative yet plausible. Commentaries on diseases of the future—defining sicknesses as yet unrealized—must not yield to apocalyptic scenarios since few sicknesses ever reach pandemic dimensions. Conjectures about future ailments must therefore carry some relationship to current reality.

Reflections on the burdens of disease in populations not yet born, have generally been wild surmises more in the realm of fiction than science. Demographers, molecular microbiologists and population epidemiologists have taught us that our future is not a limitless canvas of possibilities and that biological realities have established certain boundaries for the unnamed illnesses of tomorrow. Each new chapter of history, much like successive chapters in works of fiction, must display some continuity, must acknowledge an identified cast of characters acting under rules that do not change in midstream.

This being but one day after April First—a day assigned by society to honor witless reveries—herewith is a list of some human diseases that surely might be encountered in future decades but have not as yet arisen:

Cape Cod Fever, a disorder that arises in those adults who consume excessive amounts of shell-fish particularly oysters. An infallible diagnostic sign distinguishing Cape Cod Fever from other enteric illnesses: The patient's abdomen rises and falls coincident with the Atlantic tides.

Malaria, a tropical disorder of the oral cavity wherein parasites, confined to the surfaces of the teeth, cause molar cavities. On rare occasions, when the disease spreads to organs and tissues beyond the teeth, it is then considered transcendental rather than merely dental.

Ideational Schizophrenia: A newly evolving psychiatric disorder wherein its victims can readily tolerate two divergent views without appreciating their mutual incompatibility. The disorder seems to reach epidemic proportions during the weeks preceding Election Day.

Multi-Colored Diseases: Physicians, when confronting new disorders the causes of which remain a puzzle, often resort to the use of colors when seeking a suitable label. Thus, historically, we have had the Black Death, a compelling name for the pandemic of bubonic plague commencing in Europe of the 14th Century. Another perplexing disease, first encountered in Africa, resulted in jaundice in its victims. And thus was born the title, Yellow Fever. Tuberculosis became a major cause of

urban mortality by the 18th Century; and to contrast it with bubonic disease (the Black Death), it was identified as the White Plague. And some forms of streptococcal infection, causing a roseate rash, were promptly called Scarlet Fever. Thus, color was a readily available descriptive agent when attempting to characterize certain diseases.

Might there be newly emerging diseases in the future, that might be properly associated with a color? Indeed, some physicians have already noted a curious behavioral malady in a few of their male patients. These troubled middle-class adults have recently foresworn the wearing of neckties; and while still employed in business offices they have even decried the wearing of white shirts, declaring themselves to be emotionally more aligned with their blue-collar brethren. Accordingly, and in keeping with the medical tradition of employing color in assembling disease-titles, some experts have suggested that this new disorder be entitled **White-Cholera Disease**.

The widening abyss in yearly income that arbitrarily divides the American population into the 1% and the 99% categories, has created a parallel world of diseases firmly allied with each of these economic enclaves. One disorder of the very wealthy is a newly evolving respiratory infection, communicable in only certain rarefied circles, and is now referred to as **Affluenza**.

Still other maladies hidden in future years include: **Retention-Deficit Disorder**, a urinary tract disability seen particularly in the early years of senescence; **Prep-tic Ulcers**, a disorder of thinking that advocates public schooling for all children except one's own; and **Charles de Gaulle Stones**, a variant form of chronic gallbladder disease confined to francophone patients.

What then is our future but a congenial array of uncontested illusions; and an interlude when our many prophesies have yet to be denied or even tested?

— STANLEY M. ARONSON, MD

Stanley M. Aronson, MD is dean of medicine emeritus, Brown University.

Disclosure of Financial Interests

The author and his spouse/significant other have no financial interests to disclose.

CORRESPONDENCE

e-mail: SMAMD@cox.net

The Rhode Island Medical Society's 200th Anniversary

Nitin S. Damle, MD, MS, FACP

ON APRIL 21ST 2012 THE RHODE ISLAND MEDICAL SOCIETY (RIMS) will celebrate its 200th anniversary as an organization. The milestone is noteworthy due to the significant impact of RIMS on the lives of Rhode Island residents.

The Society was formed at the old Court House in Providence in 1812 (eighth oldest in the United States) and Dr. Amos Throop was elected as its first President. It was on February 25, 1812, that the Rhode Island General Assembly granted a charter for the creation of the Rhode Island Medical Society. In the timeless words of that charter, "The medical art is important to the health and happiness of society, and medical societies have been found conducive to this end." It was a time of apprenticeship medicine, with a few medical schools in the United States (University of Pennsylvania, Columbia, Harvard and Dartmouth) and Europe, no germ theory, anesthesia, imaging or antibiotics. Infection was thought to be caused by "bad air" or "miasma." It was Louis Pasteur, fifty years later who identified bacteria as one cause of infection. It was a time of sooth-sayers, snake oil salesmen, water cure practitioners and soothing syrups full of morphine. A primary motive to form the Society was to educate and bring some standardization to the practice of medicine.

RIMS fought hard to raise the standards of practice, register births, deaths and marriages and helped create the American Medical Association in the middle of the 19th century. RIMS promoted sanitation; combated epidemics; promoted occupational health; and disciplined the ranks of physicians, and those who pretended to be physicians. RIMS was not monolithic in its efforts; as one member stated "it is an inalienable right of the people to be humbugged if they so choose." Fortunately, this became an increasing untenable position with advances in bacteriology, immunology and physiology. In 1910 the Flexner report was published. The report called for the practice of medicine based in science. It called for universities to found more medical schools and raise the standards and the ethics of the profession. Johns Hopkins and the University of Michigan had been recently formed and by the 1920's the care of patients was based in scientific knowledge applied to individual patients. It would still be several decades before the advent of controlled clinical trials and the advances in surgery and pharmaceuticals.

In 1917 RIMS published Rhode Island Medicine (now Rhode Island Medicine and Health) and has continuously published the journal for nearly one hundred and fifty years. For most of the 20th century, the Society's library and lecture hall at the corner of Hayes and Francis Streets in Providence was the premier center for continuing medical education in Rhode Island. Through the 20th century RIMS promoted campaigns to improve milk quality, eliminate the common drinking cup, abate air and water pollution, regulate work hours for women and children and make cancer and infectious disease reportable to a registry.

In 1939 and 1949 RIMS helped to form Blue Cross and then Blue Shield of Rhode Island. In 1978 RIMS established

the Physicians Health Program to assist physicians with mental and substance abuse health problems. This program has saved countless careers and lives through the past three decades.

Medical professional liability crises occurred in the United States in 1975 (a "crisis of availability"), 1985 and 2003/4 ("crisis of affordability") and in 1994 a crisis of insolvency in Rhode Island was averted by the availability of NORCAL Mutual Insurance Company, who accepted the complete book of business without underwriting. RIMS helped to form Quality Partners of Rhode Island (Healthcentric Advisors) to improve the quality of patient care. In 2004 the Society helped found the Office of the Health Insurance Commissioner, which has resulted in reform and improved regulation of the health insurance market.

Today, the Rhode Island Medical Society remains strong with over 1,700 members, including physicians, medical students and allied health professionals. The Council and Committees of the Society represent all medical and surgical specialties. Most importantly the Society maintains close relationships with all the health plans, the Office of the Health Insurance Commissioner, the Department of Health and major health care systems in the state, with the mission to advocate for fair and transparent treatment of patients and physicians.

The Rhode Island Medical Society is active in promoting health information technology through the adoption of electronic health records and the health information exchange (currentcare), works tirelessly with the legislature on public health issues such as seat belt laws, a sugared beverage tax and ignition interlocks to prevent drunk driving. The Society has promoted an anti-smoking campaign in schools for years and will combat the epidemic of obesity with education about a healthy lifestyle of diet and exercise. The society continues to advocate for professional liability reform with "Apology" legislation (early, complete and empathetic disclosure of medical errors), decreasing interest rates on claims and promoting a merit review board for potential malpractice cases. The Society also provides a series of professional educational opportunities for health care providers.

The Affordable Care Act of 2010 has resulted in health insurance reform and will continue to change the delivery of health care through 2014 and beyond. A reformed health care system will further focus on increased quality and cost conscious care. Its center is primary care and the Patient Centered Medical Home model of care, which will provide chronic, complex and acute disease management, preventive health, performance measurement, cost control and a coordinated care delivery system between primary care physicians, specialists, hospitals, laboratories, imaging centers and long term care facilities. The Medical Society supports the above initiative, the Health Benefits Exchange and other efforts to provide affordable, high quality health care for all Rhode Island residents.

While the agenda for RIMS has changed through two centuries, the mission remains unchanged: "the Society advocates for all Rhode Island physicians in their effort to provide the best

possible care to their patients.” The Society provides education to physicians and patients, represents the values of the medical profession and promotes enlightened public policy in the field of health care.

There are a series of planned commemorative events through the year including a series of public lectures on “Neuroscience and Society”. The series will draw upon recent discoveries in the biology of the human brain, which is transforming fields as diverse as medicine, criminal justice, philosophy and theology. A Presidential lecture series is also underway, focusing on contemporary topics in the practice of medicine. There will be a grand celebration on April 21st 2012 in Newport Rhode Island. Please join your friends and colleagues and celebrate the history of medicine in Rhode Island.

Disclosure of Financial Interests

The author and/or their spouse/significant other do not have financial interest to disclose.

CORRESPONDENCE

Nitin S. Damle, MD, MS, FACP
President
Rhode Island Medical Society
481 Kingstown Rd.
Wakefield, RI 02879
phone: (401) 789-0283
fax: (401) 789-0314
e-mail: nsdamle@scim.necoxmail.com

Introduction: Arthritis and Joint Replacement – The Upper Extremities

Theodore A. Blaine, MD

ARTHRITIS IS THE MOST COMMON MUSCULOSKELETAL JOINT CONDITION, affecting over 27 million Americans. Although it is most commonly seen in the hip and knee, arthritis also frequently affects the upper extremities (shoulder, elbow, wrist and hand) and spine. The shoulder accounts for 30 percent of all patients presenting with chronic joint pain, and it is the third most common large joint to require surgical reconstruction, after the knee and the hip.

The most common types of arthritis include osteoarthritis, rheumatoid arthritis and other inflammatory arthropathies. However, arthritis may also occur as a secondary process after trauma, infection, or avascular necrosis. Patients with arthritis typically present with pain, loss of motion, and mechanical symptoms such as catching and locking. Radiographic features of osteoarthritis include sclerosis, subchondral cyst formation, loss of joint space and architecture, and osteophyte formation.

Standard non-operative treatment measures for arthritis include oral medications (nonsteroidal anti-inflammatories, acetaminophen, narcotic pain medications), injectable medications (corticosteroids, methotrexate, etc.) and physical therapy. When these treatments fail, joint replacement is a successful option for these patients.

Joint replacement surgery in the upper extremity has increased dramatically in numbers and variety of procedures available in the past decade. From 1998 to 2008 there was a 2.5 times increase (from 19,000 to 47,000) in the number of shoulder arthroplasties performed in the United States. With the advancing age of the population, and with new materials and technologies available, joint replacement is expected to continue its increase in the next decade and beyond.

In this issue of *Medicine & Health/Rhode Island*, we present articles on the most current treatment alternatives available for arthritis affecting the upper extremities and cervical spine. The most common joint replacement procedures are described, and some of the newer cutting-edge replacement procedures are presented. Many of these procedures were designed, developed, or advanced by our own physicians and orthopedic surgeons in Rhode Island. It is hoped that the dissemination of this information will benefit the patients and physicians of Rhode Island by sharing the many successful joint replacement procedures available to them in the treatment of arthritis.

Dr. Theodore Blaine was formerly Associate Professor of Orthopaedic Surgery at the Warren Alpert Medical School of Brown University. Currently, he is Chief of Shoulder and Elbow Surgery at Yale Orthopaedics and Rehabilitation and Associate Professor of Orthopaedic Surgery at the Yale School of Medicine.

Disclosure of Financial Interests

Theodore Blaine, MD, is a consultant and on the speakers' bureau for Zimmer Corp, and receives grant research support from Tomier Corp.

CORRESPONDENCE

Theodore A. Blaine, MD
Chief of Shoulder and Elbow Surgery
Sports Medicine, Arthroscopic, Reconstructive and
Trauma Surgery
Yale University Department of Orthopaedics and Rehabilitation
Yale University School of Medicine
phone: 203-737-2348
e-mail: theodore.blaine@yale.edu

Digital and Thumb Arthroplasty as Treatment for Arthritis of the Hand

Edward Akelman, MD, and Arnold-Peter C Weiss, MD

OSTEOARTHRITIS OF THE HAND IS A COMMON medical diagnosis made in patients seen in a primary care, rheumatologic, and orthopedic practice.¹ The hand is an extremely common site of this disease. This diagnosis primarily affects the thumb carpometacarpal joint, as well as the finger distal interphalangeal and proximal interphalangeal joints. Patients with hand osteoarthritis have bony nodules at the distal interphalangeal joint called Heberden's nodes. These prominences may initially be painful, but pain generally improves over time. Patients may also present with ganglion cysts of the distal interphalangeal joint called mucous cysts. Bony nodules at the PIP joints are also seen, although less frequently, and these are called Bouchard's nodes.

Idiopathic thumb carpo-metacarpal osteoarthritis occurs most commonly in women between the ages of 40 and 75 years. (Figure 1) Thumb osteoarthritis may also be caused by joint and ligament factors that may cause instability, subluxation, and subsequent arthritis. Patients complain of pain at the base of the thumb with functional activities such as pinch and grip. This usually starts with activity, but at later disease stages may be present at rest. There are other common functional symptom complaints such as difficulty in taking tops off of jars, turning keys,

or opening doors. In the digits, patients with osteoarthritis initially describe joint stiffness, with loss of digital motion, and subsequent pain with finger use. Pinch and grip strength may be diminished secondary to pain and limited motion. Diagnosis of these conditions is made by physical exam and radiographs. Radiographs generally show findings of joint space narrowing, osteophytes, as well as angular deformities.

Initial conservative care of hand osteoarthritis consists of the use of heat, non-steroidal anti-inflammatory medicines, and splinting. The use of corticosteroid injections in affected joints may be appropriate for later treatment and improve pain relief, but is never permanent.

Rheumatoid arthritis is a systemic autoimmune medical inflammatory condition that affects the synovium surrounding the joints.¹ In the hand, it primarily affects the metacarpal-phalangeal joints, although other joints may be involved. Patients with rheumatoid arthritis of the hand complain of loss of strength, morning stiffness, difficulty with function because of poor digital positioning, and deformity. Physical exam will generally demonstrate ulnar deviation of the digits at the metacarpal phalangeal joints as well as volar subluxation. Patients may present with fusiform swelling of digital joints, described as bogginess.

Flexion deformities can be seen at the PIP joint, or patients may present with hyperextension deformities at the PIP joint called swan-neck deformities. Diagnosis is made by physical exam and radiograph. Radiographs typically show metacarpal-phalangeal subluxation with ulnar deviation deformity of the digits.

Major strides have been made in the medical treatment of rheumatoid arthritis. Newer generation **disease-modifying anti-rheumatic drugs (DMARDs)** have been shown to decrease pain and diminish disease progression in affected joints. Conservative treatment also involves the use of resting splints, especially night, as well as functional splints that can be used during the day.

OSTEOARTHRITIS— THUMB CARPOMETACARPAL (CMC) JOINT

Surgical treatment of thumb CMC joint osteoarthritis includes arthrodesis, arthroscopy, suspension/ligamento-taxis, interposition arthroplasty, or prosthetic joint replacement.^{2,3} Prosthetic joint replacement of the thumb CMC joint has been infrequently used to treat CMC arthritis due to the reported complications of aseptic loosening and soft tissue and foreign body reaction to implants. Newer implants have been recently introduced, but long-term studies are not yet available to see if these implants have diminished previous complication rates.

Currently, the most commonly used surgical procedures to treat thumb CMC osteoarthritis are soft tissue arthroplasty procedures which include resection of the trapezium with or without ligament reconstruction using either the flexor carpi radialis tendon, the extensor carpi radialis longus tendon or the abductor pollicis longus tendon. Alternatively suspensionplasties using tendons or suture materials have been devised to hold the thumb metacarpal out to length. Removing the trapezium allows the base of the thumb metacarpal to articulate against a soft tissue mass/scar with or without ligamentous reconstruction, eliminating painful bone on bone contact. This type of procedure, first popularized by Carroll, Littler, and Eaton^{4,5} in the United States has been used for over 50 years with excellent results. Large prospective randomized series of surgical treatment comparisons have as yet not been able to determine a difference in outcome between these

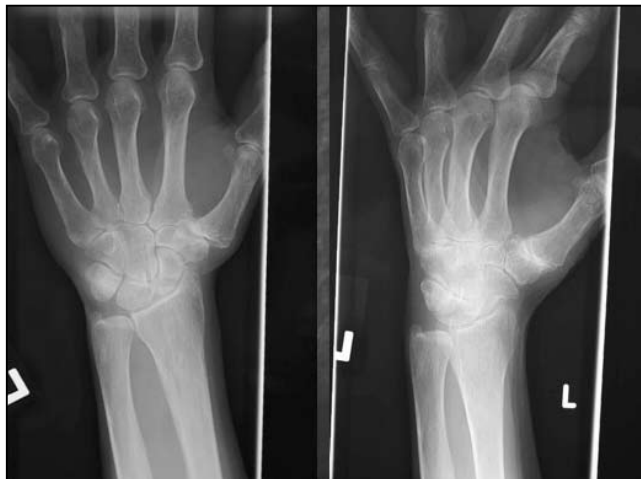

Figure 1. Radiographic appearance of osteoarthritis of the thumb carpometacarpal joint.

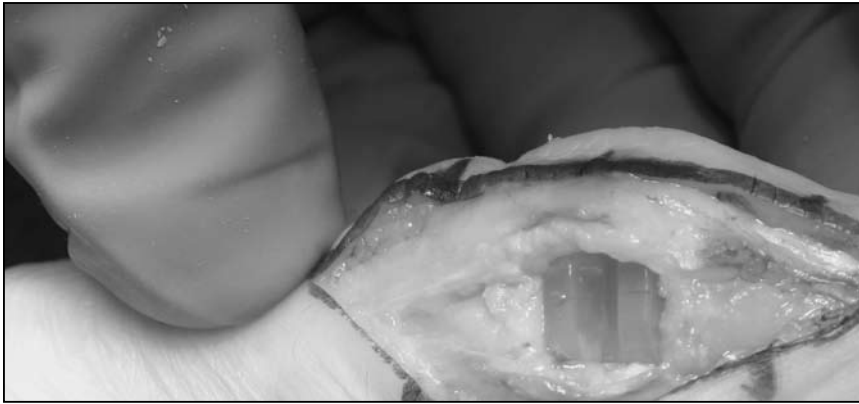


Figure 2. Implant silastic arthroplasty for pip osteoarthritis.

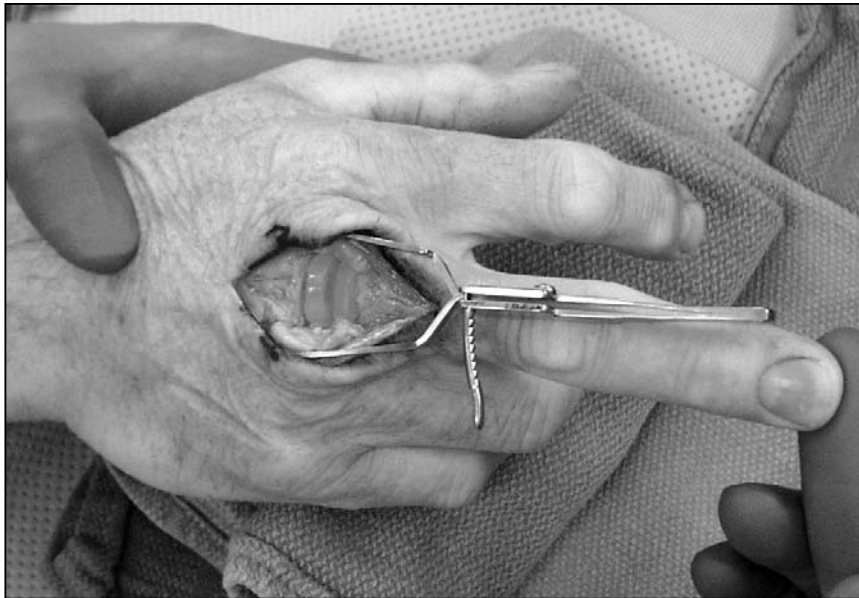

Figure 3 Silastic arthroplasty MCP joint with implant in place.

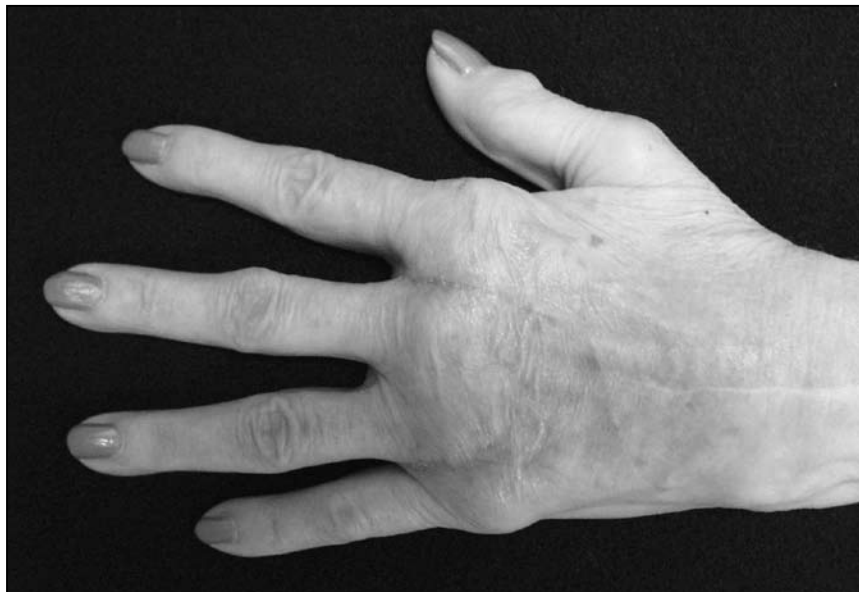

Figure 4 Clinical appearance with silastic arthroplasty in place.

different soft tissue procedures.⁶ Surgery in these patients failing conservative care has given excellent outcomes for pain relief, improved function, and patient satisfaction.

OSTEOARTHRITIS—DISTAL INTERPHALANGEAL JOINT (DIP)/ PROXIMAL INTERPHALANGEAL JOINT (PIP)

DIP joint arthritis may cause severe pain, and may not respond to conservative care including splinting, nonsteroidal anti-inflammatory drugs, or cortisone injection. Long-term follow-up studies of silicone arthroplasty replacement of the DIP joint have not been frequently reported. Wilgis⁷ reviewed 38 joints treated by silicone arthroplasty over a ten year period. In this series less than 10% of the implants needed to be removed. Soft tissue arthroplasty of the DIP may be accomplished by surgically exploring the joint and removing dorsal osteophytes on the proximal portion of the distal phalanx and the distal portion of the middle phalanx. This surgical procedure has not been well studied, but has worked well in selected patients. Long-term relief of severe pain and deformity in this patient population is best provided by DIP joint arthrodesis using screw fixation.

PIP joint osteoarthritis may be treated in the patient failing conservative care with either PIP joint arthrodesis or arthroplasty. Arthroplasty is done in this joint by a dorsal approach, resecting both arthritic sides of the joint, and placing an implant that bridges the joint. (Figure 2) PIP joint silastic arthroplasty has been used for 50 years treating this condition. There has been some concern regarding long-term results with implant failure. A recent study of 70 implants followed for over six years demonstrated 11 implant fractures.⁸ Another study using a different implant appeared to show lower implant failure rates.⁹ Much research has been done on other types of implants including those using Pyro carbon as well as those based on cobalt chrome on polyethylene articulations. Pyrolytic carbon arthroplasty appears to show some similar outcome measures at early follow up compared with silicone implants, but concerns have been raised regarding loosening, squeaking, and rates of dislocation. Metal on polyethylene joint implants have

not been followed long-term, although there has been concern raised regarding the possibility of wear debris.

RHEUMATOID ARTHRITIS— METACARPOPHALANGEAL (MCP) JOINT REPLACEMENT ARTHROPLASTY

Patients with involvement of the MCP joints of the hand with the diagnosis of rheumatoid arthritis are initially treated medically, with the use of supporting splinting, especially at night, being most helpful. When ulnar deviation and subluxation deformities occur, these are best treated with replacement arthroplasty.^{10,11} Surgery is done dorsally, with resection of the involved joint, joint replacement, and soft tissue and tendon stabilization procedures done around and for the affected joint. (Figure 3 and 4) Implants made from silicone are most commonly used to replace all four joints. Hand therapy protocols are instituted after soft tissue healing to improve range of motion. Recent outcome studies by Chung have shown considerable improvement of patient function, patient satisfaction as well as hand appearance at one year after surgical MCP joint replacement when compared with a similar group of patients treated medically.¹²

MCP joint arthroplasty in rheumatoid patients appears to maintain correction of ulnar drift. This requires appropriately stabilized soft tissue, centralization of tendons, and bone resection. Patient followed long term after silicone arthroplasty do appear to have implant fractures over time. Trail retrospectively reviewed 1,000 silicone MCP arthroplasty done over a 17 year period.¹³ Implants fractured at a rate of 42% at ten years and 66% at 17 years. Revision arthroplasty rates were 17% at ten years and 37% at 17 years. Revision surgery has excellent outcomes, and patient satisfaction with this procedure is high. It is hoped that new manufacturing techniques and hinge designs may improve upon these good outcomes.

REFERENCES

1. *Essentials of Musculoskeletal Care*, American Academy of Orthopedic Surgeons, John F Sarwark, MD, editor. 2010;397–427.
2. Jacobs BJ, Verbruggen G, Kaufmann RA. Proximal interphalangeal joint arthritis; *J Hand Surg.* 2010;35A:2107–16.
3. Kapoutsis DV, Dardas A, Day CS. Carpometacarpal and Scaphotrapezotrapezoid Arthritis: Arthroscopy, Arthroplasty, and Arthrodesis. *J Hand Surg.* 2011;36A:354–66.
4. Escott BG, Ronald K, Judd MGP, Bogoch ER. Neuflex and Swanson Metacarpophalangeal implants for rheumatoid arthritis: prospective randomized, controlled clinical trial. *J of Hand Surg.* 2010;35A:44–51.
5. Rizzo M. Metacarpophalangeal joint arthritis. *J Hand Surg.* 2011;36A:345–53.
6. Wilgis EF. Distal interphalangeal joint silicone inter-positional arthroplasty of the hand. *Clin Orthop Relat Res.* 1997 Sep;(342):38–41.
7. Shuler MS, Luria S, Trumble TE. Basal Joint Arthritis of the Thumb. *J AM Acad Orthop Surg.* 2008;16:418–23.
8. Chung KC, Burns PB, Wilgis EF, Burke FD, Regan M, Kim HM, et al. A multicenter clinical trial in rheumatoid arthritis comparing silicone metacarpophalangeal joint arthroplasty with medical treatment. *J Hand Surg.* 2009;34A:815–23.
9. Trail IA, Martin JA, Nuttall D, Stanley JK. Seventeen-year survivorship analysis of Silastic metacarpophalangeal joint replacement. *J Bone Joint Surg.* 2004;86B:1002–6.
10. Barron OA, Glickel SZ, Eaton RG. Basal joint arthritis of the thumb. *J Am Acad Orthop Surg.* 2000;8(5):314–23.
11. Froimson A. Tendon interposition arthroplasty of the trapeziometacarpal joint. *Clin Orthop Relat Res.* 1970;70:191–9.
12. Nylén S, Johnson A, Rosenquist AM. Trapeziectomy and ligament reconstruction for osteoarthritis of the base of the thumb: a prospective study of 100 operations. *J Hand Surg Br.* 1993;18(5):616–9.
13. Takigawa S, Meletiou S, Sauerbier M, Cooney WP. Long-term assessment of Swanson implant arthroplasty in the proximal interphalangeal joint of the hand. *J Hand Surg.* 2004;29A:785–95.
14. Namdari S, Weiss AP. Anatomically neutral silicone small joint arthroplasty for osteoarthritis. *J Hand Surg.* 2009; 34A: 292–300.

Edward Akelman, MD, is Professor and Vice Chairman of Orthopaedics at the Warren Alpert Medical School of Brown University, and the head of the Division of Hand, Upper Extremity and Microvascular Surgery of the Department of Orthopaedics at Rhode Island Hospital.

Arnold-Peter C. Weiss, MD, is a Professor of Orthopaedics and Dean of Admissions at The Warren Alpert Medical School of Brown University, and a staff surgeon in the Division of Hand, Upper Extremity and Microvascular Surgery of the Department of Orthopaedics at Rhode Island Hospital.

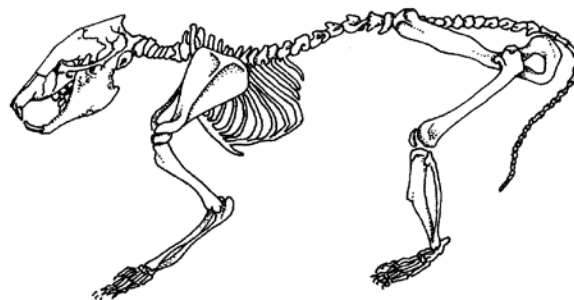Disclosure of Financial Interests

Edward Akelman, MD, does not have any financial interest to disclose.

Peter-Arnold C. Weiss, MD, has financial interest in DePuy, Inc.

CORRESPONDENCE

Edward Akelman, MD
University Orthopedics, Inc.
2 Dudley St., Suite 200
Providence, RI 02905
e-mail: edward_akelman@brown.edu



Cervical Spondylosis, Stenosis, and Rheumatoid Arthritis

Matthew McDonnell, MD, and Phillip Lucas, MD

CERVICAL SPONDYLOSIS/STENOSIS

Cervical spondylosis is common and progresses with increasing age. It is the result of degenerative changes in the cervical spine, including disc degeneration, facet arthropathy, osteophyte formation, ligamentous thickening and loss of cervical lordosis. Spinal stenosis, or narrowing of the spinal canal, may occur as a result of progression of spondylotic changes. Spinal cord or nerve root function may be affected, resulting in symptoms of myelopathy or radiculopathy.

Natural History and Epidemiology

Spinal cord compression resulting from spondylotic changes is usually a slow and progressive process. Many patients have evidence of significant compression on imaging studies but are asymptomatic. Most cases of myelopathy develop in a stepwise fashion described by episodes of exacerbation of symptoms and worsening function followed by long periods of static function. Fewer patients have steady progressive deterioration. With vascular insufficiency, acute onset may occur with devastating, irreversible ischemic changes occurring within the cord.^{1,2}

Approximately 25% of individuals younger than forty years of age, 50% of individuals over forty years of age, and 85% of individuals over sixty years of age have some degree of disc degeneration.¹⁻³

Pathophysiology

The pathoanatomy of cervical spondylosis results from the sequelae of the aging process in the spine, specifically, disc degeneration with hypertrophic osseous and ligamentous changes. Disk desiccation is accompanied by biochemical changes, with a relative increase in the ratio of keratan sulfate to chondroitin sulfate. The loss of elasticity and total disk substance results in a decrease in disk height with annular bulging. This altered biomechanical environment stimulates formation of chondro-osseous spurs at the annular insertion near the end-plates.

The uncovertebral joints hypertrophy, which may lead to foraminal stenosis. The posterior zygoapophyseal joints can also become arthritic, causing foraminal narrowing. The ligamentum flavum thickens and sometimes buckles as a result of the loss of disk height. These degenerative changes can result in cervical stenosis with spinal cord compression. Concomitant straightening of cervical lordosis (or even kyphosis), disk herniations or protrusions often may accentuate the problem because the spinal cord will be stretched over the posterior aspect of the disks and vertebral bodies.

Cervical spondylosis will typically result in stiffening of the spinal motion segments. It is not uncommon for the motion segments one or two levels above the stiff segments to become hypermobile. The resulting instability may lead to dynamic cord compression.^{1,4,5}

Radiculopathy is due to biochemical and biomechanical changes that occur with age as a result of the degenerative cascade and lead to disc herniation or foraminal narrowing. The intervertebral disc gradually loses height, posterior portions of the disc bulge into the spinal canal and the neuroforamina, the ligamentum flavum and facet joint capsule infold, and osteophytes form. All of this leads to decreases in canal and foraminal size. Subluxation and hypermobility between vertebral bodies may occur. The pain that occurs as a result of nerve root compression is thought to be mediated by an inflammatory response as well as nerve root edema and fibrosis.^{6,7}

Clinical Presentations

Axial Neck Pain

Neck pain is an extremely common but nonspecific presenting symptom. It is often associated with stiffness and headaches. The pain or soreness is usually in the parameian neck muscles posteriorly, with radiation toward the occiput or into the shoulder, arm and periscapular regions. The referred pain does not follow a dermatomal distribution. Deep palpation of some of these areas results in reproducible patterns of referred pain. Determining the source of neck pain can be a diagnostic challenge. New pain patterns may develop as a result of postural adaptations and compensatory overuse of normal tissues further confusing the clinical picture. Shoulder pathology sometimes presents with pain referred to the neck. A careful history should be obtained to rule out inflammatory arthritis or an infectious or neoplastic process.^{2,4,8}

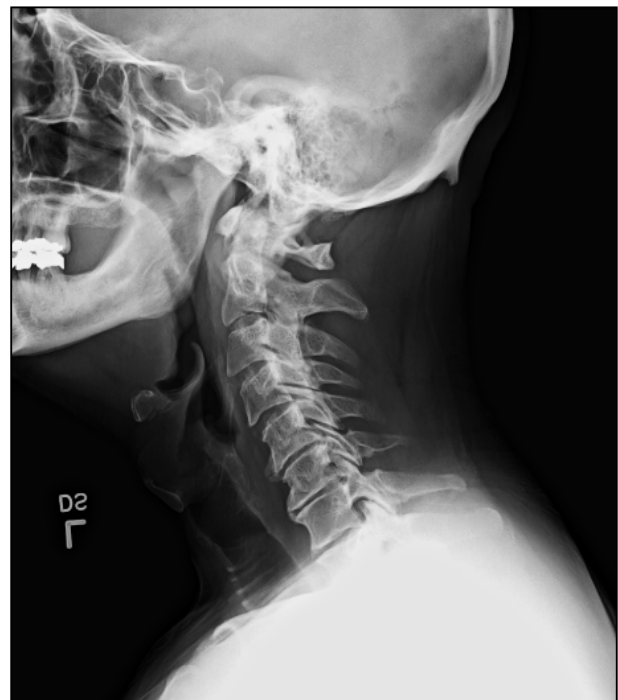

Figure 1: Lateral cervical spine x-rays of a patient with degenerative cervical spondylosis showing disk space narrowing, end-plate sclerosis and osteophytes.

Cervical Radiculopathy

Cervical radiculopathy refers to symptoms in a specific dermatomal distribution in the upper extremity. Severe neck and arm pain is typical, partially alleviated by holding the arm over the head or tilting the head to the contralateral side. Patients may report sensory or motor loss corresponding to the involved nerve root. On physical exam, symptoms are aggravated by extension and lateral rotation of the head (Spurling Maneuver). Sensory deficits, motor deficits, and diminished reflex activity may be elucidated on exam. Care should be taken to differentiate cervical radiculopathy from compressive lesions of nerves of the upper extremity (i.e. carpal tunnel syndrome, cubital tunnel syndrome) and electrodiagnostic studies can often be useful. Additionally, patients with metabolic disorders, such as diabetes, who have neuropathy may be more susceptible to radiculopathy and compressive neuropathy.^{2,8}

Cervical Myelopathy

The patient with cervical spondylotic myelopathy may present with subtle findings that have been present for years or with quadriplegia that developed over the course of a few hours. If the cord compression and myelopathy are either moderate or severe, patients complain of gait and balance abnormalities involving the lower extremities. They also have numbness or paresthesias in their upper extremities. Fine motor control is usually affected as well, and they will note changes in their handwriting or ability to manipulate buttons or zippers. Arm weakness is common. Leg weakness can occur, and patients may notice problems moving their body weight, such as is necessary when rising out of a chair or going up stairs. The proximal motor groups of the legs are more involved than the distal groups. Changes in bowel or bladder function can occur in extremely severe cases of myelopathy. On physical examination, the findings that establish the diagnosis are brisk reflexes, clonus, or pathological reflexes confirming an upper-motor-neuron lesion.^{1,9}

Diagnosis

Plain radiographs are an important part of the diagnostic workup, and **anterior-posterior (AP)**, lateral, and flexion-extension views of the cervical spine should

be obtained in essentially all patients with neck pain or neurologic symptoms. Typical radiographic manifestations of cervical spondylosis include disk-space narrowing, end-plate sclerosis, and osteophytic changes at the end-plates, uncovertebral joints, and facet joints. (Figure 1) The AP view allows identification of cervical ribs and scoliotic deformity. The lateral view demonstrates the degree of disk narrowing, the size of end-plate osteophytes, the size of the spinal canal, and overall sagittal alignment which may influence the choice of surgical procedure. Flexion-extension views are critical to diagnose instability, which may not be evident on a neutral lateral view. Oblique views can be used for visualizing foraminal narrowing, which is typically due to uncovertebral joint spurs.

Magnetic resonance imaging (MRI), while not indicated for every patient with neck pain, is the next step in the evaluation of the patient with a presumed diagnosis of spondylosis with myelopathy or radiculopathy. Persistent neck or arm pain of several months duration, neurologic findings, or a worsening symptomatic picture warrants MRI. If evidence of myelopathy is present on exam, MR imaging is indicated to assess for disk herniation, hypertrophy, buckling of the ligamentum flavum and the degree of cord compression. One of the strengths of MR imaging is the ability to visualize the spinal cord, its size, shape, quality (pathologic changes) and degree of compression.^{10,11}

Although MR imaging provides optimal visualization of soft tissues, CT-myelography offers better definition of bone spurs or and **ossified posterior longitudinal ligament (OPLL)**. The exact degree of cord deformation in the transverse plane is more sharply visualized with CT-myelography as well. This modality is also useful when MRI is contraindicated.

Lastly, electrodiagnostic studies are sometimes used. For patients with cervical radiculopathy, electromyographic-nerve conduction studies may be useful in considering the differential diagnosis of carpal tunnel syndrome, ulnar cubital tunnel syndrome, or thoracic outlet syndrome. Electrodiagnostic modalities may also help elucidate the confusing clinical presentations of amyotrophic lateral sclerosis, multiple sclerosis, and severe peripheral neuropathy.¹

Treatment

Axial Neck Pain

Nonoperative treatment is the standard for discogenic and axial neck pain. Nonsteroidal anti-inflammatory agents, narcotic analgesics, corticosteroids, muscle relaxants, and antidepressants are commonly used to relieve neck pain and radiculopathy. A short period of rest and the use of a soft collar with the neck in mild flexion may sometimes alleviate acute pain and spasm. Physical therapy, including isometric exercises, active range-of-motion exercises, aerobic conditioning, and resistive exercises, has been found to be helpful for patients with chronic neck pain.¹² In one study, nonoperative management resulted in complete resolution

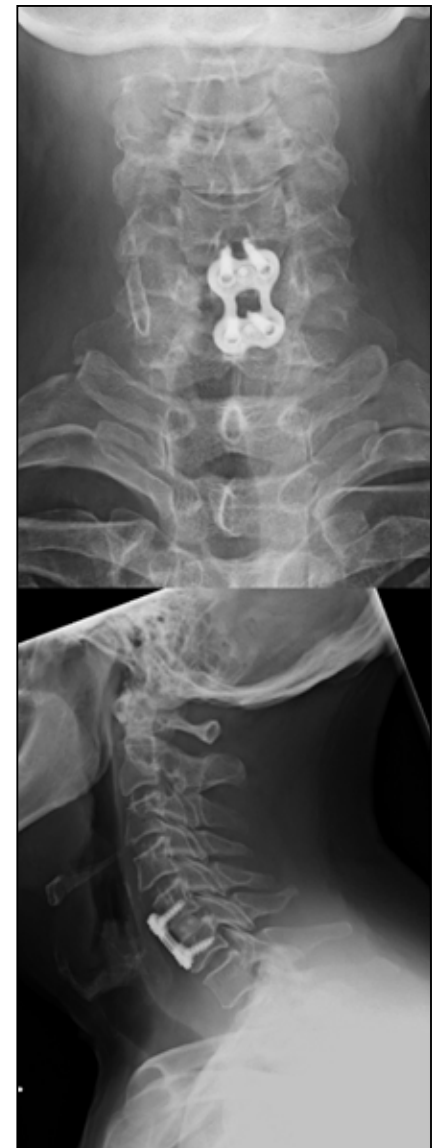

Figure 2: AP (a) and lateral (b) views of a patient who had an anterior cervical decompression and fusion at C5-C6

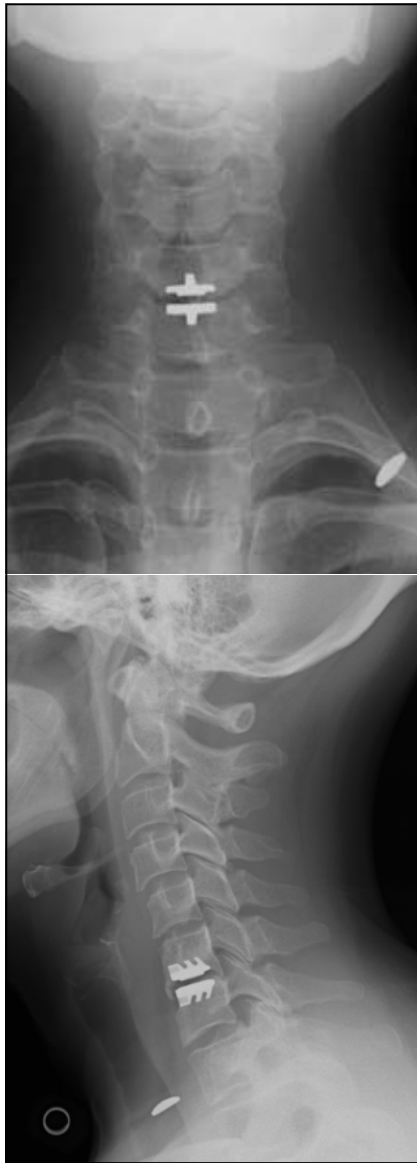

Figure 3: AP (a) and lateral view (b) of a patient who had a total cervical disc arthroplasty at C6-C7.

of symptoms in 43% of the patients and partial resolution in 25%, whereas 32% had continued moderate or severe pain.¹² In rare cases, some patients who fail conservative management may improve with surgery for discogenic axial neck pain.

Radiculopathy

Cervical radiculopathy is first treated with conservative, nonoperative measures as described above. Additionally, some authors have reported that epidural injections may be of short-term benefit to patients with radiculopathy.^{13,14}

Surgery is an option for patients with persistent cervical radiculopathy and disabling radicular pain following failure

of nonoperative measures. These patients should have neuroimaging studies demonstrating a pathological condition that correlates with clinical findings and physical exam. Surgery is also an option for patients with a progressive motor deficit or a disabling motor deficit from the radiculopathy.¹⁵ Surgical treatment options include **anterior cervical discectomy and fusion (ACDF)** (Figures 2a and 2b), total disc arthroplasty (Figures 3a and 3b), or posterior decompression with fusion.

Myelopathy

Treatment of myelopathy is generally surgical. Mild cases of myelopathy, usually consisting of mild upper extremity symptoms, may respond to nonoperative treatment but rarely resolves completely. In one prospective randomized study patients with mild-to-moderate nonprogressive or slowly progressive myelopathy were found to have similar outcomes after either nonoperative or operative treatment¹⁶. Another study reports that trial of nonoperative treatment did not decrease the potential for ultimate recovery of patients with mild myelopathy.¹⁷

Patients with severe or progressive myelopathy are candidates for surgical intervention. A number of factors such as the degree of neurologic dysfunction, patient disability, findings on radiographs and magnetic resonance imaging, duration of symptoms, and presence of comorbidities are considered in the decision regarding when to proceed with surgery.

Surgical treatment options include anterior decompression utilizing either discectomy and fusion (for single level disease) or corpectomy with strut graft fusion (for multilevel disease). Posterior decompressive procedures also can be used to treat cervical myelopathy. These procedures include laminoplasty (a canal expanding procedure that maintains stability posteriorly) (Figure 4a and 4b) or laminectomy with instrumentation and fusion.

RHEUMATOID ARTHRITIS OF THE CERVICAL SPINE

Rheumatoid arthritis of the cervical spine is not as common as degenerative arthritis but up to 90% of patients with the diagnosis of rheumatoid arthritis have radiographic changes within the cervical spine.¹⁸ Many of these patients have

mild symptoms of pain. Some may be even symptomatic while others may go on to develop severe pain and significant neurologic deficit.

Cervical spine involvement may be overlooked in spite of the fact that after the hands and feet, cervical spine is the most common site of disease involving rheumatoid arthritis.¹⁹ The involvement of the cervical spine may be difficult to detect due to systemic complaints or lack of clear neurologic deficit on physical exam. It is therefore imperative that the treating physician be well aware of the natural history as well as the clinical presentation in deciding what treatment options are available for patients with rheumatoid arthritis.

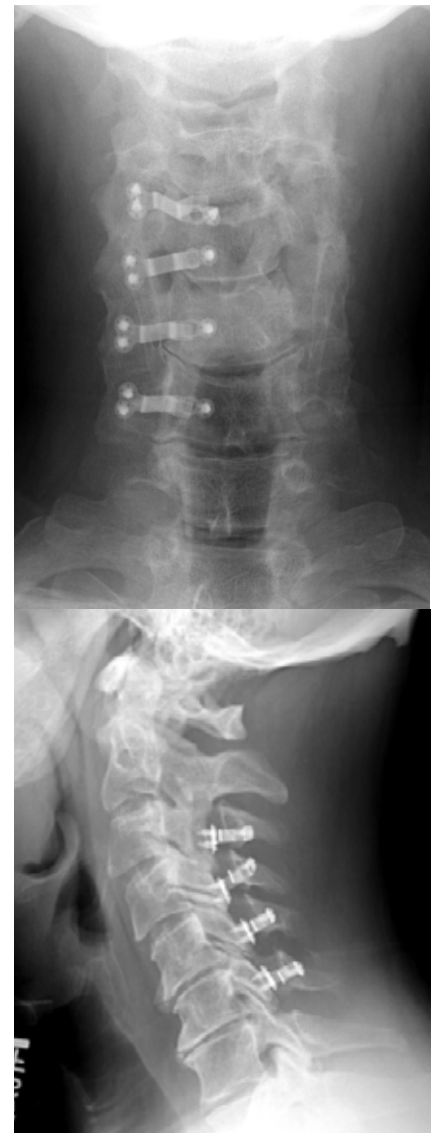

Figure 4: AP (a) and lateral (b) cervical spine films of a patient who had laminoplasty performed for cervical myelopathy.

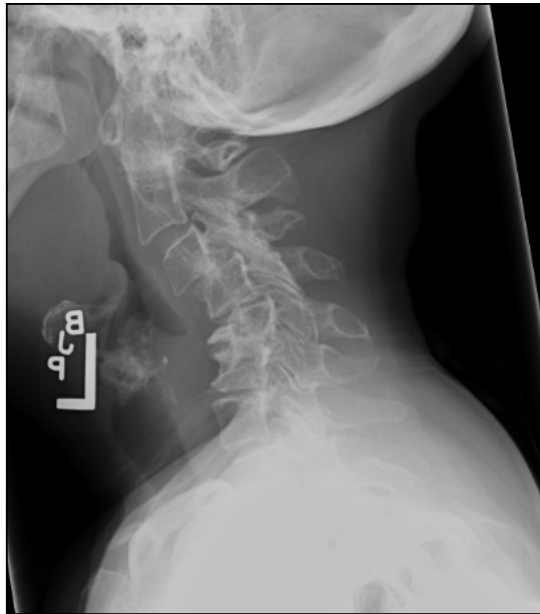

Figure 5: Patient with rheumatoid arthritis and subaxial subluxation.

Pathophysiology

Rheumatoid arthritis is a systemic disease characterized by inflammation and eventual destruction of the synovial joints. The cervical spine has 22 synovial joints and the inflammatory process may mirror that which occurs in synovial joints throughout the body.¹⁸ The course of the disease in any patient is unpredictable. It may be very progressive. It may be characterized by intermittent flare-ups and remissions. In the cervical spine rheumatoid arthritis may lead to instability, subluxation and spinal cord compression. Three characteristic patterns of instability have been described. The most common area of involvement is the atlanto-axial or C1-C2 level. Synovitis results in eventual destruction of the transverse ligament as well as bone erosion of the odontoid process. Atlanto-axial subluxation occurs in up to 49% of patients.²⁰ Sub-axial subluxation is the second most common type and it is due to destruction of the facet joints below the C2 level. (Figure 5) It results in the characteristic staircase deformity and occurs in approximately 30% of patients with rheumatoid arthritis.²¹ The third type of subluxation is atlanto-axial impaction with vertical subluxation of the axis. It occurs as C1, C2 and the occiput settle due to erosion of the joints. It can lead to brain stem compression as the odontoid enters the foramen magnum. This occurs in 12-30% of rheumatoid patients.²¹

Clinical Presentation

Neck pain is the most common presenting symptom in patients with rheumatoid arthritis. It can be present in up to 80% of the patients.¹⁸ Some patients with atlanto-axial subluxation can have a clunking sensation during neck extension with reduction of atlanto-axial subluxation. This has been labeled a positive sharp-purser test.²² Additionally, patients may complain of stiffness, crepitation and painful range of motion.

Depending upon the location of the pathological process patients may also present with paresthesia in the upper extremity as well as weakness involving both upper and lower extremities. Objective neurologic signs have been

found to be present in seven to 34% of patients.¹⁸ If significant compression of the spinal cord occurs myelopathy will develop causing significant weakness in addition to gait disturbance. Subluxation may also cause occlusion of vertebral arteries and vascular insufficiency to the spinal cord and brain stem as well as the cerebellum. Patients may present with cranial nerve palsy, paraplegia and even sudden death.²³

The classification system of Ranawat is commonly used to characterize the neurologic status of patients with rheumatoid arthritis.

Diagnostic Imaging

Even asymptomatic patients with known systemic rheumatoid arthritis should have periodic radiographs with flexion/extension views. Early detection of subluxation and close follow-up prevents the development of serious neurologic complications.

If there is concern about the upper cervical spine with regard to the possibility of bone erosion a CT scan can be very beneficial. If the clinical history and exam reveals neurologic deficit then an MRI of the cervical spine is the diagnostic study of choice.

Treatment

Non-surgical Treatment

While up to 90% of patients with rheumatoid arthritis will have some involvement of the cervical spine only about ten percent will become symptomatic enough to warrant surgical intervention. Patients with early cervical disease, intermittent pain and without radiographic instability or myelopathy can benefit from early aggressive medical treatment. This includes the use of non-steroidal anti-inflammatory medications, mild analgesics and **disease modifying anti-rheumatic drugs (DMARD)**.²⁶ In addition, the use of soft collars are appropriate and patients seem to benefit greatly from a comprehensive program of patient education, physical therapy with specific focus on isometric strengthening of neck muscles and postural training.

Classification System of Ranawat²⁴

Grade I	No neurologic deficit
Grade II	Subjective weakness, hyperreflexia, dysethesia
Grade III	Subjective weakness and long tract signs a.) Ambulatory b.) Quadriparetic non-ambulatory

Indications for radiographs of cervical spine in rheumatoid arthritis patients²⁵

1. Prolonged cervical symptoms greater than 6 months
2. Neurologic signs or symptoms
3. Scheduled operative procedure requiring endotracheal intubation
4. Rapid progressive destruction of carpal or tarsal bones
5. Rapid overall functional deterioration.

Surgical Treatment

As with any surgery it is imperative that a thorough pre-operative assessment be carried out in what is typically a very frail patient population. Serious consideration should be given to surgery in patients with progressive neurologic deficit as a result of spinal cord compression due to spondylosis. In addition surgery for patients experiencing severe unremitting pain unresponsive to medication are surgical candidates. Relative indications for surgery include patients who show radiographic risk factors of impending neurologic injury, particularly when the space available for the spinal cord is 14 mm or less due to spondylosis.

Goals of surgical treatment in rheumatoid arthritis of the cervical spine are to decompress the spinal cord, achieve spinal stability through fusion across the unstable segment, and to prevent irreversible neurologic deficit and to avoid catastrophic functional decline.^{27,28}

Surgical treatment of patients with rheumatoid arthritis of the cervical spine can be successful. Over the past decade outcomes have improved considerably as a result of earlier diagnosis of myelopathy and more aggressive medical management.^{29,30}

Patients with rheumatoid arthritis have an overall higher complication rate than the general population. Complications include infection, instrument failure and lack of solid fusion in up to 25% of the patients. The peri-operative mortality rate is five to ten percent.³⁰

Summary

The majority of patients with rheumatoid arthritis involving the cervical spine can be managed non-operatively. These patients should be monitored closely by the treating physician for the development of neurologic symptoms or spondylosis on radiographs. Non-surgical treatment in the majority of patients has a definite role. Several studies now suggest early surgical intervention in patients with progressive instability and neurologic deficit is indicated to prevent significant morbidity and mortality in these patients.³¹

REFERENCES

1. Emery SE. Cervical Spondylotic Myelopathy: Diagnosis and Treatment. *J Am Acad Orthop Surg.* 2001;9(6):376–88.
2. Lees F, Turner JWA. Natural history and prognosis of cervical spondylosis. *BMJ.* 1963;2:1607–10.
3. Lee MJ, Cassinelli EH, Riew KD. Prevalence of cervical spine stenosis: Anatomic study in cadavers. *J Bone Joint Surg (Am).* 2007;89(2):376–80.
4. Bohlman HH. Cervical spondylosis and myelopathy. *Instr Course Lect.* 1995;44: 81–97.
5. Wang B, Liu H, Wang H, Zhou D. Segmental instability in cervical spondylotic myelopathy with severe disc degeneration. *Spine.* 2006;31: 1327–31.
6. Chabot MC, Montgomery DM. The pathophysiology of axial and radicular neck pain. *Semin Spine Surg.* 1995;7:2–8.72.
7. Cooper RG, Freemont AJ, Hoyland JA, Jenkins JP, West CG, Illingworth KJ, Jayson MI. Herniated intervertebral disc-associated periradicular fibrosis and vascular abnormalities occur without inflammatory cell infiltration. *Spine.* 1995;20:591–8.
8. Rao RD, Currier BL, Albert TJ, Bono CM, Marawar SV, Poelstra KA, Eck JC. Degenerative cervical spondylosis: clinical syndromes, pathogenesis, and management. *J Bone Joint Surg Am.* 2007;89:1360–78.
9. Clarke E, Robinson PK. Cervical myelopathy: A complication of cervical spondylosis. *Brain.* 1956;79:483–510.
10. Lehto JJ, Terti MO, Komu ME, Paajanen HE, Tuominen J, Kormano MJ. Age-related MRI changes at 0.1 T in cervical discs in asymptomatic subjects. *Neuroradiology.* 1994;36:49–53.3649
11. Matsumoto M, Fujimura Y, Suzuki N, Nishi Y, Nakamura M, Yabe Y, Shiga H. MRI of cervical intervertebral discs in asymptomatic subjects. *J Bone Joint Surg (Br).* 1998;80:19–24.8019
12. Chiu TT, Lam TH, Hedley AJ. A randomized controlled trial on the efficacy of exercise for patients with chronic neck pain. *Spine.* 2005;30:E1–7.30E1.
13. Gore DR, Sopic SB, Gardner GM, Murray MP. Neck pain: a long-term follow-up of 205 patients. *Spine.* 1987;12:1–5.
14. Cicala RS, Thoni K, Angel JJ. Long-term results of cervical epidural steroid injections. *Clin J Pain.* 1989;5:143–5
15. Albert TJ, Murrell SE. Surgical management of cervical radiculopathy. *J Am Acad Orthop Surg.* 1999;7:368–76.
16. Kadanka Z, Mares M, Bednanik J, Smrcka V, Krbec M, Stejskal L, Chaloupka R, et al. Approaches to spondylotic cervical myelopathy: conservative versus surgical results in a 3-year follow-up study. *Spine.* 2002;27:2205–11.
17. Matsumoto M, Chiba K, Ishikawa M, Maruiwa H, Fujimura Y, Toyama Y. Relationships between outcomes of conservative treatment and magnetic resonance imaging findings in patients with mild cervical myelopathy caused by soft disc herniations. *Spine.* 2001;26:1592–8.
18. Rawlins BA, Jerardie FP, Boachie Adjei. Rheumatoid arthritis of the cervical spine. *Rheumatoid Disease.* Clinics of North America, 1998;524:55–65.
19. Crockard HA. Surgical management of cervical rheumatoid problems. *Spine.* 1995;20:2584–90.
20. Morizono Y, Sakou T, Kawaida H. Upper cervical spine involvement in rheumatoid arthritis. *Spine.* 1987;12:721–5.
21. Neva MH, Kaarela K, Kauppi M. Prevalence of radiographic changes in the cervical spine. A cross-sectional study after 20 years from presentation of rheumatoid arthritis. *J Rheum.* 2000;27:90–3.
22. Sharp J, Purser D, W. Spontaneous atlanto-axial dislocation in ankylosing spondylitis and rheumatoid arthritis. *Ann Rheum Dis.* 1961;20:47–50.
23. Zeidman SM, Ducker TB. Rheumatoid arthritis; neuroanatomy, compression and grading of deficit. *Spine.* 1994;19:2259–66.
24. Ranawat CS, O'Leary P, Pellicci P. Cervical spine fusion in rheumatoid arthritis. *J Bone Joint Surg Am.* 1979;61:1003–10.
25. Kim PA, Hilibrand AS. Rheumatoid arthritis in the cervical spine. *J Am Acad Orthop Surg.* 2005;13:463–74.
26. Hamilton JD, Gordon MM, McInnes JB, Johnston RA, Madhok R, Capell EJ. Improved medical and surgical management of the cervical spine disease in patients with rheumatoid arthritis over ten years. *Ann Rheum Dis.* 2000;59:434–8.
27. Boden SD. Rheumatoid arthritis of the cervical spine: surgical decision making based on predictors of paralysis and recovery. *Spine.* 1994;19:2275–80.
28. Boden SD, Dodge LD, Bohlman HH, Rechter GR. Rheumatoid arthritis of the cervical spine. Long term analysis with predictors of paralysis and recovery. *J Bone Joint Surg Am.* 1993;75:1282–97.
29. Clark DR, Goetz DD, Menezes AH. Arthrodesis of the cervical spine in rheumatoid arthritis. *J Bone Joint Surg Am.* 1989;71:381–92.
30. Poppelman WC, Kraus DR, Donaldson WF, Agarwal A. Cervical spine surgery in rheumatoid arthritis: Improvement of neurologic deficit after cervical spine fusion. *Spine.* 1993;18:2375–79.
31. Reiter MF, Boden SD. Inflammatory disorders of the cervical spine. *Spine.* 1998;23, 2755–2766.

Matthew McDonnell, MD, is a Chief Resident in the Department of Orthopaedic Surgery at the Warren Alpert Medical School of Brown University and Rhode Island Hospital.

Phillip Lucas, MD, is a Clinical Associate Professor in the Department of Orthopaedic Surgery at the Warren Alpert Medical School of Brown University, and an Attending Surgeon at Rhode Island Hospital.

Disclosure of Financial Interests

The authors and/or their spouses/significant others have no financial interests to disclose.

CORRESPONDENCE

Matthew McDonnell, MD
2 Dudley Street
Providence, RI 02903
matthew_mcdonnell@brown.edu

Elbow Arthritis and Total Elbow Replacement

Lee A. Kaback, MD, Andrew Green, MD, and Theodore A. Blaine, MD

ARTHRITIC INVOLVEMENT OF THE ELBOW IS RELATIVELY UNCOMMON.

However, because of the critical role that the elbow plays in hand and upper extremity function arthritis can be functionally disabling. The most common etiologies of elbow arthritis are primary degenerative arthritis (osteoarthritis), rheumatoid and inflammatory arthritis, and post traumatic arthritis. Other less common conditions include hemophilic arthropathy, synovial chondromatosis, and post infectious arthropathy. Treatment is dependent on the extent of pathologic involvement and predicated on relieving pain and restoring function.

RELEVANT ANATOMY

The elbow joint is comprised of complex articular anatomy and associated ligamentous and musculotendinous structures and the elbow is biomechanically critical to upper extremity function.¹ The elbow is considered to be a trochoginglymoid joint because it has both hinge and rotational motion. The articular geometry is very constrained and critically important to joint stability. In addition the medial and lateral ligament complexes play an important role in elbow stability and function.

Even minor trauma or transient disease involvement can result in prolonged, limited, if not permanent, painful motion. Although the elbow is not commonly considered a weight-bearing joint, static loading forces can equal three times body weight, which increase to 6 times with dynamic loading.^{1,2}

PRIMARY DEGENERATIVE ARTHRITIS

Primary degenerative arthritis (osteoarthritis (OA)) of the elbow is a rare condition, affecting fewer than two percent of the population.³ It is most commonly seen in men at a ratio of about four to one²⁻⁵ and typically affects individuals who are involved in heavy use such as manual labor and weight lifting.^{4,5} The dominant extremity is involved in 80 to 90 percent of patients, and bilateral involvement is present in about 25 to 60 percent. Elbow OA is characterized by pain, limited motion, mechanical symptoms, and weakness. Loss of terminal elbow extension and impingement-type pain at terminal extension and flexion are common in the earlier stages of the disease process. Classically, a patient will report pain when carrying heavy objects at the side of the body with the elbow in extension. In the later stages, the elbow progresses to a greater degree of motion loss and pain in the mid-arc of motion. Unlike other joints, osteoarthritis of the elbow is characterized by relative preservation of the articular cartilage joint surface with maintenance of joint space, but with hypertrophic osteophyte formation and capsular contracture.

The extent of the radiographic findings usually correlates with the patient's symptoms. Osteophyte formation on the tip of the olecranon and in the olecranon fossa leads to pain and limitation of elbow extension, while osteophytes on the coronoid and in the coronoid and radial fossae leads to pain and limitation of elbow flexion. (Figure 1) Secondary changes include osteophytes at the margin of the radial head and loose bodies. Occasionally the radiohumeral joint is selectively involved.⁶ Because of excessive osteophyte formation in the region of the cubital tunnel ulnar nerve irritation is observed in at least ten percent of these patients. CT

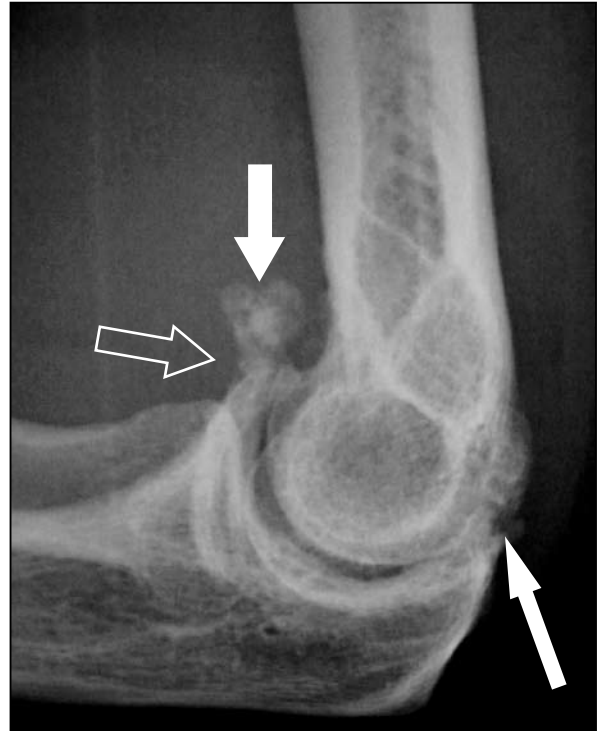

Figure 1. Lateral radiograph in a patient with elbow osteoarthritis. Osteophytes are present both on the coronoid (open arrow) and olecranon (narrow arrow) limiting both flexion and extension. There is a large loose body in the anterior joint space (filled arrow).

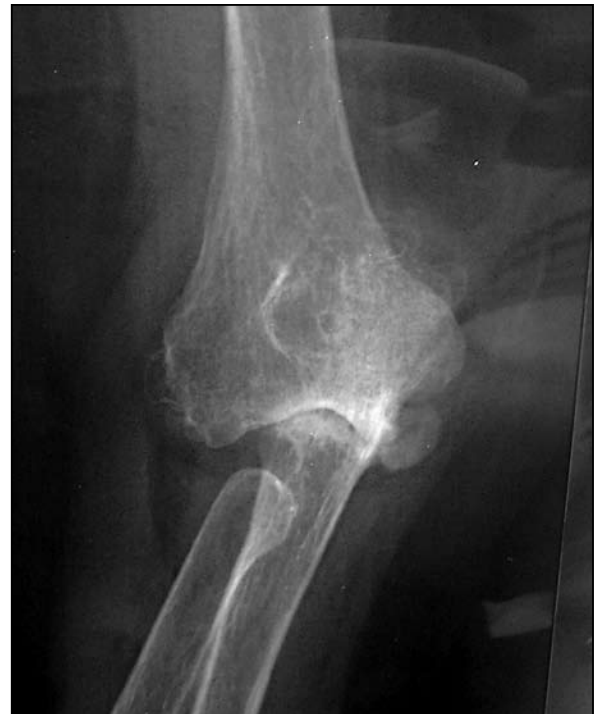

Figure 2. Anteroposterior radiograph of the right elbow in a patient with Grade IV rheumatoid arthritis.

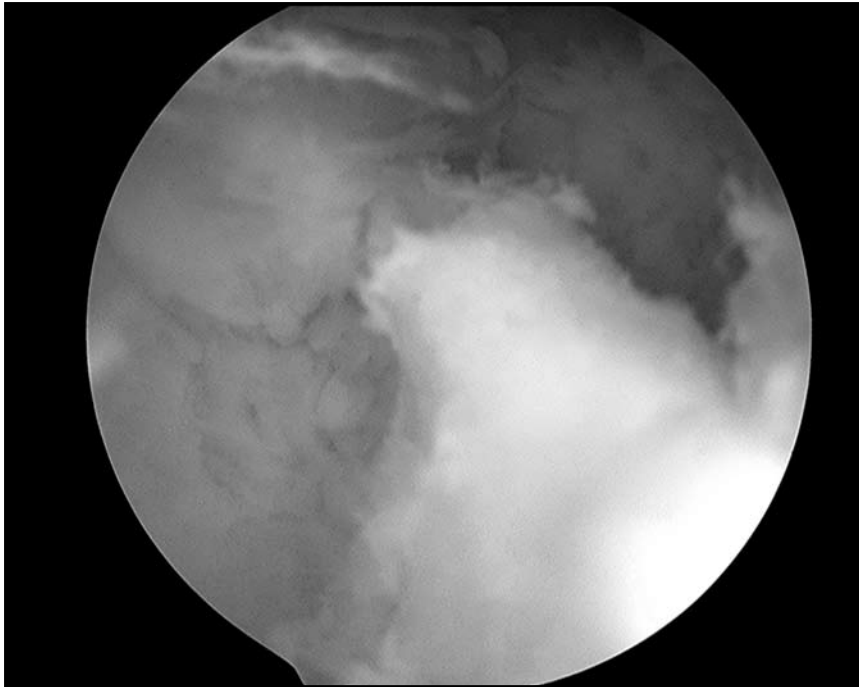


Figure 3. Intraoperative arthroscopy photo in a patient with osteoarthritis showing a large coronoid osteophyte impinging in the anterior elbow joint.




Figure 4. Intraoperative photo showing multiple loose bodies which have been removed from a patient with elbow OA.

scans are often helpful in these patients for delineating the pathology and location of osteophytes and loose bodies.

RHEUMATOID ARTHRITIS

Rheumatoid arthritis is a systemic inflammatory disease that is characterized by polyarticular involvement. Rheumatoid arthritis, in contrast to primary

degenerative arthritis of the elbow, is characterized by more severe articular surface involvement and joint destruction. Between 20 and 50 percent of patients with rheumatoid arthritis demonstrate elbow involvement, usually within five years of disease onset. Isolated presentation of RA of the elbow occurs in only about five percent of patients.⁷

Rheumatoid arthritis of the elbow is staged or graded according to the extent of pathologic involvement and reflects soft tissue, joint surface, and bony involvement. A radiographic and clinical system for the classification of rheumatoid arthritis was developed by the Mayo Clinic. Grade I signifies normal radiographic findings except for osteopenia with mild synovitis, Grade II: loss of joint space, Grade III: loss of joint space and joint architecture, Grade IV: extensive articular damage with loss of subchondral bone and subluxation or ankylosis of the joint.⁸ (Figure 2) Unlike OA, advanced imaging modalities including computed tomography or magnetic resonance imaging scans are usually not needed to diagnose or treat rheumatoid arthritis. However, in early cases of rheumatoid involvement MRI is useful to determine the extent of synovitis which can be treated with synovectomy.

The earliest presentation is usually the result of synovitis and is characterized by pain, mild limitation of motion, and joint effusion and swelling. Progressive disease advancement results in loss of articular cartilage, peri-articular soft tissue destruction, and bony destruction, eventually leading to complete joint destruction with bone loss and instability. The recent use of disease modifying pharmaceuticals has substantially reduced the incidence of advanced rheumatoid involvement of the elbow. The extent of involvement of the shoulder and wrist should be considered when determining the treatment of patients with rheumatoid arthritis of the elbow.

POST TRAUMATIC ARTHRITIS

Post-traumatic arthritis of the elbow is most commonly a sequela of comminuted displaced intra-articular fractures of the distal humerus. These fractures are extremely challenging to treat. For this reason, elbow replacement has been advocated as an alternative to open reduction and internal fixation in elderly low demand individuals.⁹ Overall, post-traumatic elbow arthritis is less common than primary degenerative and rheumatoid arthritis. These patients often have limited motion secondary to soft tissue contracture and heterotopic ossification. However, the typical patient is younger with greater physical and functional demands, as well as expectations. Conse-

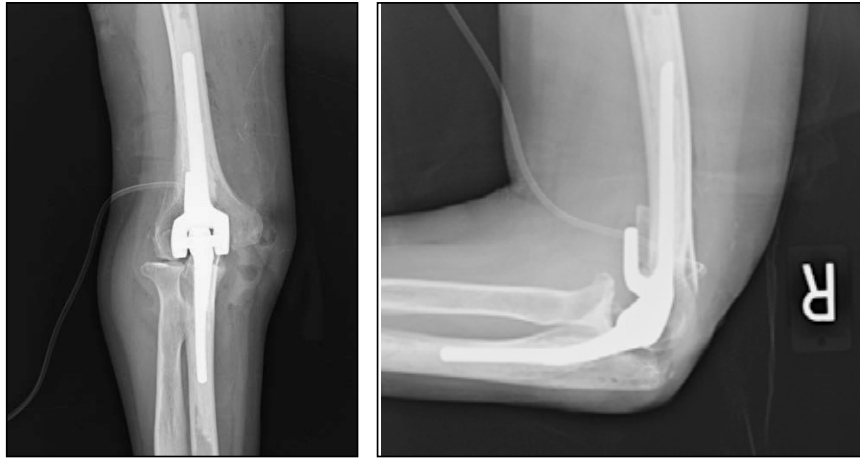

Figure 5A (left) and B (right). Postoperative radiographs of the right elbow in a patient after total elbow arthroplasty for endstage rheumatoid arthritis.

quently, the risk of failure of total elbow arthroplasty is higher and the survivorship lower when compared to patients with rheumatoid arthritis, and alternative treatments should be considered prior to considering joint replacement.

TREATMENT

In the early stages of all etiologies of elbow arthritis most patients can be treated with nonoperative modalities. These include oral non-steroidal anti-inflammatory medications and activity modification. Some patients may benefit from intra-articular injections of corticosteroids or hyaluronans.¹⁰ Physical therapy should emphasize pain control measures (avoidance of activities that place stress on the elbow, regular periods of rest, and application of heat or cold), stretching and range of motion exercises to encourage maintenance of mobility, and careful gentle strengthening exercises. Hinged elbow braces may be used to provide comfort during flexion and extension while limiting painful varus and valgus stresses. Turnbuckle braces or static progressive splints may be used to restore loss of motion.

If these non-operative modalities fail to relieve the patient's symptoms, operative treatment options including arthroscopic, open non-arthroplasty, and elbow arthroplasty can be considered. Each has specific indications and technical considerations that relate to the underlying diagnosis.

In past years open non-arthroplasty surgery had a substantial role in the treatment of primary degenerative arthritis and rheumatoid arthritis of the elbow. Open debridement and removal of hypertrophic

spurring with capsular release was often performed to treat primary degenerative osteoarthritis. The Outerbridge-Kashiwagi procedure prevents impingement of osteophytes by making a hole in the distal humerus. A number of studies reported high rates of satisfactory outcomes with pain relief and functional improvement.¹¹⁻¹³ Similarly, open synovectomy with or without radial head excision was a mainstay in the management of rheumatoid arthritis. An even greater number of studies reported successful outcomes with pain relief and improved range of motion even in patients with moderately severe rheumatoid arthritis.¹⁴⁻¹⁵

More recently, arthroscopic surgery has assumed a prominent role in the management of elbow arthritis. Arthroscopic surgery is minimally invasive and facilitates extensive intra-articular surgery while avoiding the morbidity of the equivalent open procedures. Arthroscopic debridement of the elbow for primary osteoarthritis or grade I or II rheumatoid arthritis has demonstrated successful outcomes for pain relief, restoration of motion, and functional improvement.¹⁶⁻¹⁹ (Figure 3) This procedure allows for removal of loose bodies, synovectomy, debridement and capsular release, and removal of prominent osteophytes. (Figure 4) Elbow arthroscopy however is technically difficult and should only be performed by experienced surgeons to avoid injury to key neurovascular structures. Where arthroscopy is not possible, open debridement is a safe and effective debridement procedure to remove extensive osteophytes and release capsular contractures.²⁰ Concomitant ulnar nerve decompression or transposition

is performed if there is associated ulnar neuropathy or elbow flexion limited to 90 degrees or less.

In rare cases of open debridement and where a prosthesis is contraindicated, non-prosthetic arthroplasty with an interposition material (cutis, tendon graft, etc.) can be performed to resurface the joint. The efficacy of this procedure is debated and there is a significant risk of complications.²¹

Total elbow arthroplasty (TEA) is a reliable procedure for the treatment of elbow arthritis when other interventions have failed. Pain is the most common indication for total elbow arthroplasty (TEA); most patients requiring TEA will have pain throughout the arc of motion. Although there are many total elbow replacement designs available, they are generally classified as linked (hinged) semi-constrained or unlinked. The former are required in patients with poor quality elbow ligaments and periarticular soft tissues and are commonly used in patients with advanced rheumatoid arthritis. The latter are unconstrained, require intact ligaments, and are typically used in more mildly involved rheumatoid elbows, primary degenerative arthritis, and some post-traumatic arthritis cases. (Figures 5A and B) Until recently, rheumatoid arthritis was by far the most common indication for total elbow arthroplasty.

Total elbow arthroplasty is ideally suited for lower demand patients. This describes the typical patient with rheumatoid arthritis of the elbow. Excessive use, as might be expected of younger active patients, is associated with earlier implant loosening and failure. Patients considering TEA must be willing to accept post-operative restrictions, including: no lifting more than 10 pounds at any event, and no repetitive lifting of more than two pounds.²² Rehabilitation following TEA is focused initially on soft tissue healing. Depending on the surgical approach, triceps protection including avoiding active extension against resistance is important in the early post-operative period. Most patients are able to regain an excellent range of elbow motion after surgery, and most patients are able to perform activities of daily living within four to six weeks.

Survivorship analysis studies of total elbow arthroplasty for the treatment of rheumatoid arthritis demonstrate 92.4 percent survival of implants at ten years.²³

Surgical attention to every detail

*Lease a fully furnished short-term corporate suite
(limited quantity available)
or Purchase from the
low \$300's.*



The Residences Providence

(401) 598-8282 www.residencesprovidence.com

One West Exchange Street – Providence, Rhode Island 02903-1038

INDUSTRY EXPERTISE. PERSONAL SERVICE. A HEALTHIER BOTTOM LINE.

Expect it all.



HEALTHCARE FINANCIAL SERVICES

We take your practice personally.

Our local business bankers know the healthcare industry and will work closely with you to understand the specific needs of your practice. With up to 100% EHR and Healthcare IT financing, and your choice of cash management services, you'll be able to minimize administrative tasks, optimize cash flow, and ultimately, maximize your profits. Call Jace D'Amico at 203.316.5075 to learn more.



WebsterBank.com/ExpectIt

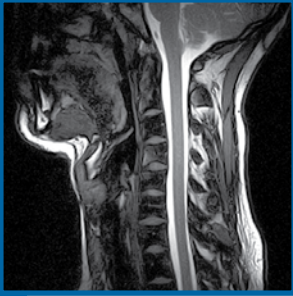


All credit products and pricing are subject to the normal credit approval process. Some applications may require further consideration and/or supplemental information. Certain terms and conditions may apply. SBA guaranteed products may also be subject to additional terms, conditions and fees. Requires a Webster business checking account which must be opened prior to loan closing and which must be used for auto-deduct of payment. The Webster Symbol and Webster Bank are registered in the U.S. Patent and Trademark Office.



THE IMAGING INSTITUTE

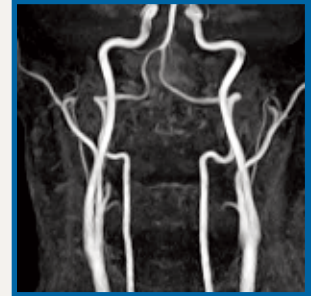OPEN MRI • MEDICAL IMAGING



High Field MRI

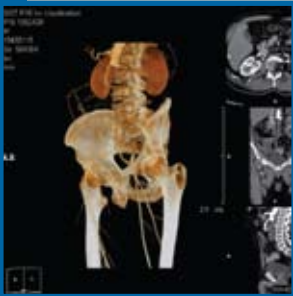- Offering both 1.5T High Field & Higher Field OPEN MRI Systems

- Advanced CT with multi-slice technology, 3D reconstruction



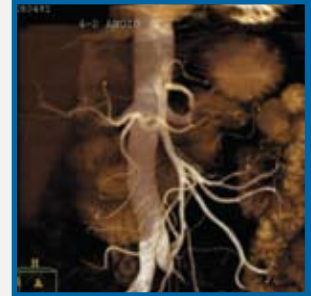MRA

- Digital Ultrasound with enhanced 3D/4D technology

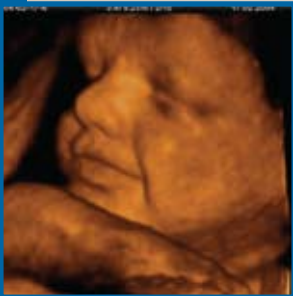

CT • 3D CT

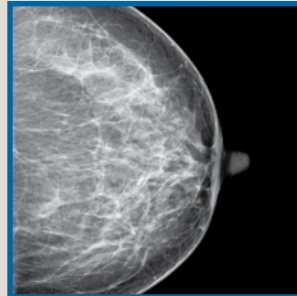
- Digital Mammography with CAD (computer assisted diagnosis)



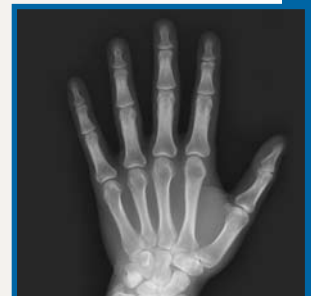CTA



3D Ultrasound

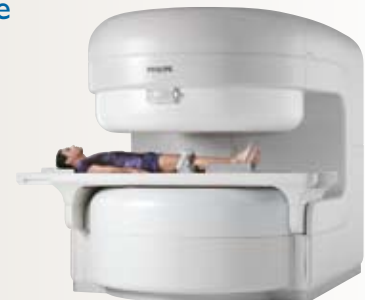

Digital Mammography



Digital X-Ray & DEXA

- Electronic Medical Record (EMR) Interfaces now available
- Preauthorization Department for obtaining all insurance preauthorizations
- Fellowship, sub-specialty trained radiologists
- Friendly, efficient staff and convenient, beautiful office settings
- Transportation Service for patients



Higher Field OPEN MRI

WARWICK

250 Toll Gate Rd.
TEL 401.921.2900

CRANSTON

1301 Reservoir Ave.
TEL 401.490.0040

CRANSTON

1500 Pontiac Ave.
TEL 401.228.7901

N. PROVIDENCE

1500 Mineral Spring
TEL 401.533.9300

E. PROVIDENCE

450 Vets. Mem. Pkwy. #8
TEL 401.431.0080

In general, the survivorship is comparable to total hip replacement, and outcome studies demonstrate that the success rate of total elbow arthroplasty for rheumatoid arthritis approaches that following total knee arthroplasty.^{24,25} In contrast, the survivorship of total elbow arthroplasty in patients with primary degenerative and post-traumatic arthritis is substantially shorter and careful consideration should be given when considering treatment of these patients.²⁶ These patients are typically younger, more active and have solitary joint involvement with greater expectations for functional use.

As with all joint arthroplasty surgery, total elbow arthroplasty is associated with complications. Complications can be generally grouped as either intra or peri-operative (directly related to the surgical procedure) or late. The most common intra- or peri-operative complications are ulnar neuropathy, triceps insufficiency and weakness, and infection. The most common late complications or problems are aseptic loosening, implant failure, and peri-prosthetic fracture. Infection and periprosthetic fractures are especially problematic and often necessitate multiple surgical procedures.²⁷⁻³⁰ Fortunately, these complications are not common.

SUMMARY

Elbow arthritis is a relatively uncommon condition that can be successfully managed with non-operative and operative methods. The extent of pathologic involvement and severity of pain and dysfunction are the most important factors in selecting treatment. Arthroscopic, open, and arthroplasty surgery options provide successful outcomes in most cases.

REFERENCES:

- Morrey BF, Askew LJ, Chao EY. A biomechanical study of normal functional elbow motion. *J Bone Joint Surgery Am.* 1981;63-A(6):872-7.
- Morrey BF. Applied anatomy and biomechanics of the elbow joint. Instructional Course Lectures, American Academy of Orthopaedic Surgeons, Rosemont, IL 1986;35:59-68.
- Stanley D. Prevalence and Etiology of Symptomatic Elbow Osteoarthritis. *J Shoulder Elbow Surg.* 1994;3:386-9.
- Morrey B. Primary arthritis of the elbow treated by ulno-humeral arthroplasty. *J Bone Joint Surgery Br.* 1992;74B:409.
- Doherty M. Primary osteoarthritis of the elbow. *Ann Rheum.* 1989;48:473.

- Delal S. Radiographic changes at the elbow in primary osteoarthritis: a comparison with normal aging of the elbow joint. *J Shoulder Elbow Surg.* 2007;16:358.
- Inglis A. Septic and non-traumatic conditions of the elbow: Rheumatoid arthritis. *The Elbow and its Disorders*, ed 2. 1993:751-66.
- Morrey BF, Adams RA. Semiconstrained arthroplasty for the treatment of rheumatoid arthritis of the elbow. *J Bone Joint Surgery Am.* 1992;74-A(4):479-90.
- McKee MD, Veillette CJ, Hall JA, et al. A multicenter, prospective, randomized, controlled trial of open reduction—internal fixation versus total elbow arthroplasty for displaced intra-articular distal humeral fractures in elderly patients. *J Shoulder Elbow Surg.* 2009;18(1):3-12.
- van Brakel RW. Intra-articular injection of hyaluronic acid is not effective for the treatment of post-traumatic osteoarthritis of the elbow. *Arthroscopy.* 2006;22:1199-203.
- Minami N. Outerbridge-Kashiwagi's Method for arthroplasty of osteoarthritis of the elbow. 44 Elbows followed for 8-16 years. *J Orthop Sci.* 1996;1:11.
- Morrey BF. Primary degenerative arthritis of the elbow. Treatment by ulnohumeral arthroplasty. *J Bone Joint Surgery Am.* 1992;74-A(3):409-13.
- Tashjian RZ, Wolf J, Ritter M, Weiss A, Green A. Functional outcomes and general health status following ulnohumeral arthroplasty for primary degenerative arthritis of elbow. *J Bone Joint Surgery Am.* 2006;15: 357-66.
- Gendi NST, Axon JMC, Carr AJ, et al. Synovectomy of the elbow and radial head excision in rheumatoid arthritis. Predictive factors and long-term outcome. *J Bone Joint Surgery Br.* 1997;79B:918-23.
- Mäenpää HM, Kuusela PP, Kaarela K, et al. Reoperation rate after elbow synovectomy in rheumatoid arthritis. *J Bone Joint Surgery Am.* 2003;12:480-3.
- Morrey BF. Arthroscopy of the elbow. Instructional Course Lectures, American Academy of Orthopaedic Surgeons, Rosemont, IL, 1986:35:102-107.
- O'Driscoll SW, Morrey BF. Arthroscopy of the elbow. Diagnostic and therapeutic benefits and hazards. *J Bone Joint Surgery Am.* 1992;74-A(1):84-94.
- Lee BP, Morrey BF. Arthroscopic synovectomy of the elbow for rheumatoid arthritis. A prospective study. *J Bone Joint Surgery Am.* 1997;79-A(5):770-2.
- Horiuchi K. Arthroscopic synovectomy of the elbow in rheumatoid arthritis. *J Bone Joint Surgery Am.* 2002;84-A:342-7.
- Morrey BF. Nonreplacement reconstruction of the elbow joint. Instructional Course Lectures, American Academy of Orthopaedic Surgeons, Rosemont, IL, 51:63-67, 2002.
- Cheng SL, Morrey BF. Treatment of the mobile, painful arthritic elbow by distraction interposition arthroplasty. *J Bone Joint Surgery Br.* 2000 Mar;82-B(2):233-8.
- Morrey BF, Askew LJ, An KN. Strength function after elbow arthroplasty. *Clinical Orthop Related Research.* 1988;234:43-50.
- Gill DR, Morrey BF. The Coonrad-Morrey total elbow arthroplasty in patients who have rheumatoid arthritis. A ten to fifteen-year follow-up study. *J Bone Joint Surgery Am.* 1998;80-A(9):1327-35.
- Little CP. Total elbow arthroplasty: A systematic review of the literature in the English language. *J Bone Joint Surgery Am.* 2005;87-A:437-44.
- van der Lugt JC, Rozing PM. Systematic review of primary total elbow prostheses used for the rheumatoid elbow. *Clinical Rheumatology.* 2004;23(4):291-8.
- Morrey BF, Adams RA, Bryan RS. Total replacement for post-traumatic arthritis of the elbow. *J Bone Joint Surgery Am.* 1991;73-A(4):607-12.
- Voloshin I, Schippert DW, Kakar S, Kaye EK, Morrey BF. Complications of total elbow replacement: A systematic review. *J Shoulder Elbow Surg.* 2011;20(1):158-68.
- Morrey BF, Bryan RS. Complications of total elbow arthroplasty. *Clinical Orthop Related Research.* 1982;170:204-12.
- Trancik T. Capitellectomy total elbow arthroplasty. 2 to 8 years experience. *Clinical Orthop Related Research.* 1987;223:175.
- Morrey BF, Bryan RS. Infection after total elbow arthroplasty. *J Bone Joint Surgery Am.* 1983;65-A(3):330-8.

Lee A. Kaback, MD, currently works in private practice in Albany, NY, specializing in shoulder and elbow reconstruction.

Andrew Green, MD, is an Associate Professor of Orthopedic Surgery and Chief of Division of Shoulder and Elbow Surgery at the Warren Alpert Medical School of Brown University, and Practices at University Orthopedics, Inc.

Theodore A. Blaine, MD, is an Associate Professor at the Yale University School of Medicine, and Chief of Shoulder and Elbow Surgery at Yale Orthopaedics and Rehabilitation.

Disclosure of Financial Interests

Lee A. Kaback, MD, and Andrew Green, MD, have no financial interests to disclose.

Theodore Blaine, MD, is a consultant and on the speakers' bureau for Zimmer Corp, and receives grant research support from Tomier Corp.

CORRESPONDENCE

Theodore A. Blaine, MD
Yale University Department of
Orthopaedics and Rehabilitation
Yale University School of Medicine
phone: 203-737-2348
e-mail: theodore.blaine@yale.edu

Andrew Green, MD
University Orthopedics, Inc
2 Dudley Street, Suite 200
Providence, RI 02905
e-mail: agreen@universityorthopedics.com

Total Wrist Replacement

Arnold-Peter C. Weiss, MD, and Edward Akelman, MD

INTRODUCTION

Wrist arthritis is a common problem seen secondary to previous trauma, rheumatoid arthritis, or osteoarthritic degenerative changes in the general population. While the majority of these patients can be treated satisfactorily with nonsteroidal anti-inflammatories and wrist splinting, a specific subgroup becomes painful enough that some form of surgical treatment is required. If the wrist arthritis is limited to only one or two portions of the wrist joint, limited procedures such as a proximal row carpectomy or limited intercarpal fusion can be performed to provide pain relief, wrist stability, and a reasonable arc of motion for overall function. If the wrist degenerative arthritis involves the entire radiocarpal joint, then the classic option has always been a total wrist fusion. While total wrist fusion is an extremely predictable procedure which provides good pain relief and strength, by definition complete loss of motion of the wrist occurs with the exception of pronation/supination. Attempts at total wrist joint replacement, such as is frequently seen in the hips and knees, have been tried for many decades. The initial implants were fraught with either dislocation of the implant themselves or loosening of the carpal component due to the insufficient bone stock present for fixation.¹⁻³ Most total wrist arthroplasties which were performed were utilized in rheumatoid arthritic patients who have a relatively lower demand from a functional basis, thereby decreasing the stresses and forces imparted to the total wrist during activities of daily living. In the last decade, significant improvements in the design of total wrist implants and the instruments available to successfully implant these have become available and

have opened up the ability to use this treatment option in patients with rheumatoid arthritis or osteoarthritis of the wrist.⁴⁻⁸ All the total wrist implants utilized in the United States are approved by the FDA for use with bone cement; however, many of these implants are porous coated and frequent use of these devices in an off-label fashion for bony ingrowth occurs.

IMPLANT DESIGN

Essentially, all of the total wrist new generation implants currently available involve a well-designed concave radial component which has an intramedullary stem, frequently porous coated, and some offset to the articular surface to provide greater stability. The carpal component most often utilizes a central stem with porous coating for fixation in the capitate and third metacarpal and two screws



Figure 1. The Universal 2 wrist implant (Integra LifeSciences, Plainsboro, NJ).

that are utilized through the metal plate of the carpal component for fixation in the carpus itself. A polyethylene convex insert is utilized to attach to the carpal component and articulates with the radial component, providing a functional arc of motion of approximately thirty to thirty-five degrees in both extension and flexion. (Figure 1) Currently, the majority of these implants are placed in an uncemented

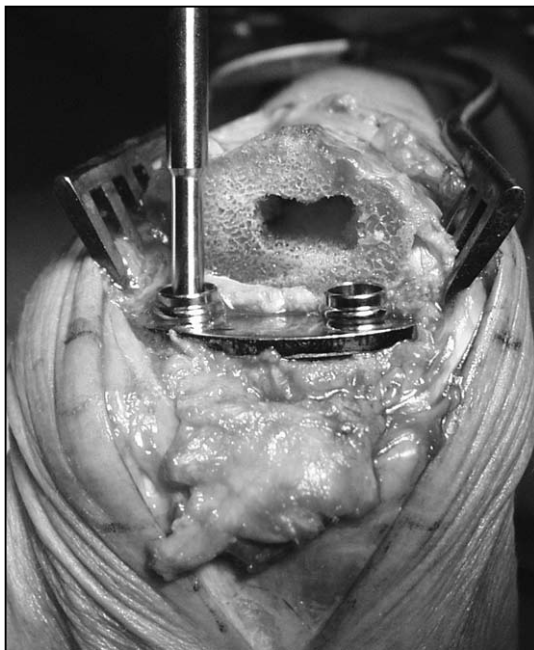


Figure 2. Intra-operative fixation of the carpal component.

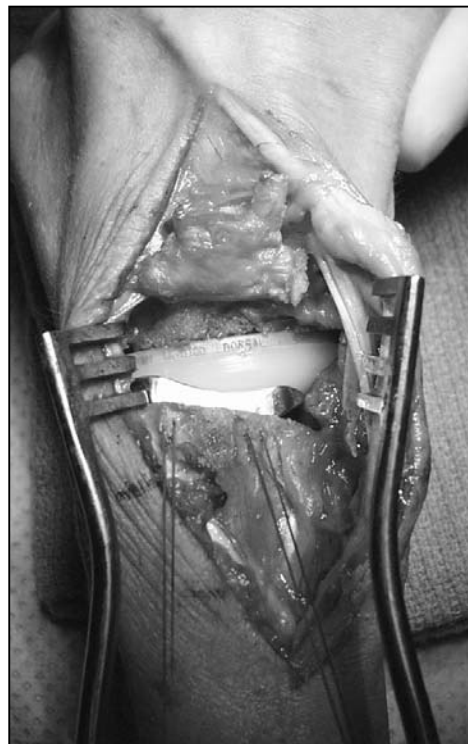

Figure 3. Intra-operative image of a well-aligned total wrist implant.

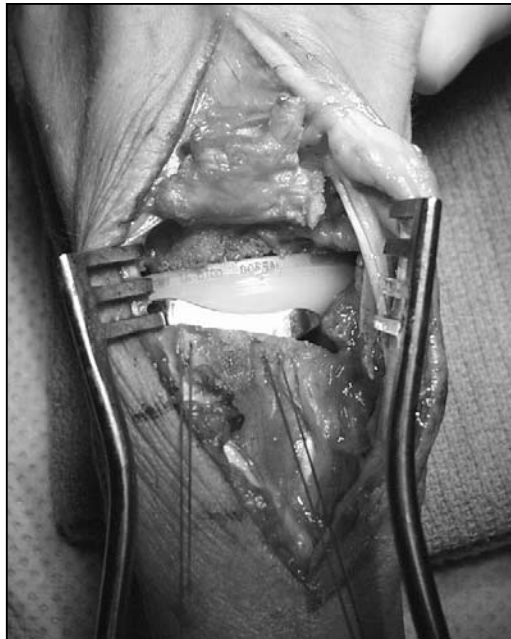

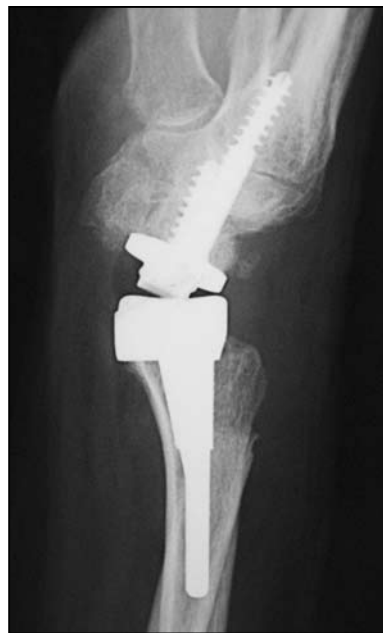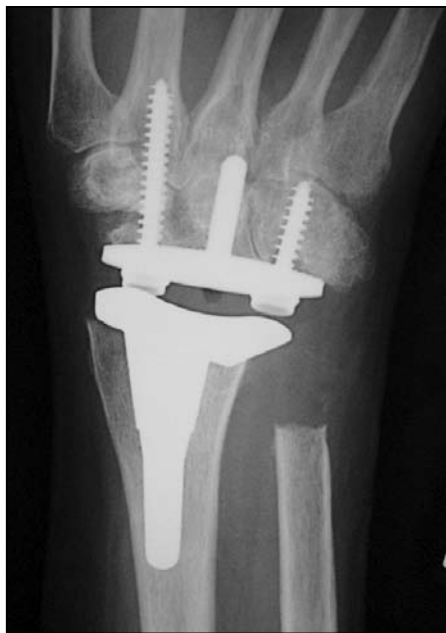Figure 3. Intra-operative image of a well-aligned total wrist implant.

fashion to allow bony ingrowth to occur in both the carpal and radial components providing a theoretically greater chance to avoid implant loosening following bony ingrowth. The surgical technique for implanting these devices is in many ways very similar to that utilized in both total hip and total knee replacements. (Figure 2) Instruments with set jigs are used to produce precise bone cuts, allowing a much more predictable alignment of the implant components than was previously afforded with older generation designs. (Figure 3) Nevertheless, there is still an inherent “fiddle factor” in accomplishing a well-aligned total wrist implant placement as compared to hips and knees due

to the much smaller architecture of the radius and carpal bones.

CLINICAL RESULTS

We have performed over fifty total wrist replacements in patients with both rheumatoid and osteoarthritis in an uncemented fashion utilizing the newest generation designs with excellent results. The initial patients in this cohort are now up to nine years out from their primary procedure. While the majority of these patients have rheumatoid arthritis, the success of the new generation implants has allowed these to be utilized in low to medium demand osteoarthritics as well. Of our current cohort of patients, only one had a dislocation of the component, which was successfully treated by closed relocation and cast immobilization for one month. In addition, a few patients have developed carpal implant loosening after five years which required revision of the carpal implant to reconstitute the device in a functional manner. No revisions of the radial component have been performed. Pain relief at the wrist has been uniformly excellent and the average range of motion in these patients stabilized at approximately seventy degrees in an extension/flexion plane. Follow up radiographs of these patients indicate excellent bone incorporation into the porous coated radial component and reasonably good bony incorporation into the carpal component although some radiolucent lines without clinical evidence of loosening are noted. (Figures 4a & 4b) Following these radiolucent lines over time does not appear to indicate a worsening problem with implant stability.



Figures 4a and 4b. Postero-anterior (a) and lateral (b) radiographs of a total wrist implant.

DISCUSSION

Uncemented total wrist arthroplasty appears to be an excellent alternative to total wrist fusion for well-select patients

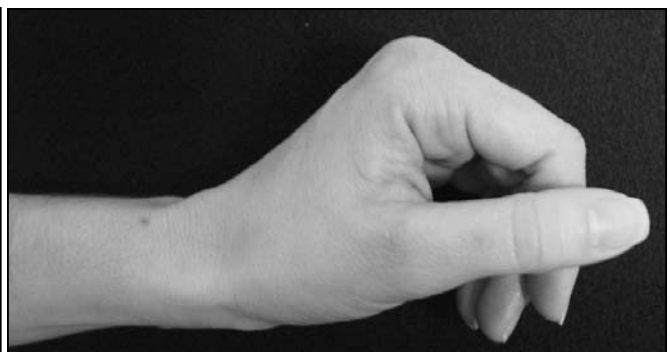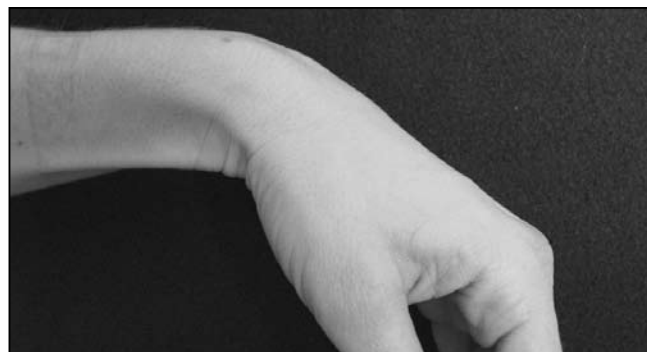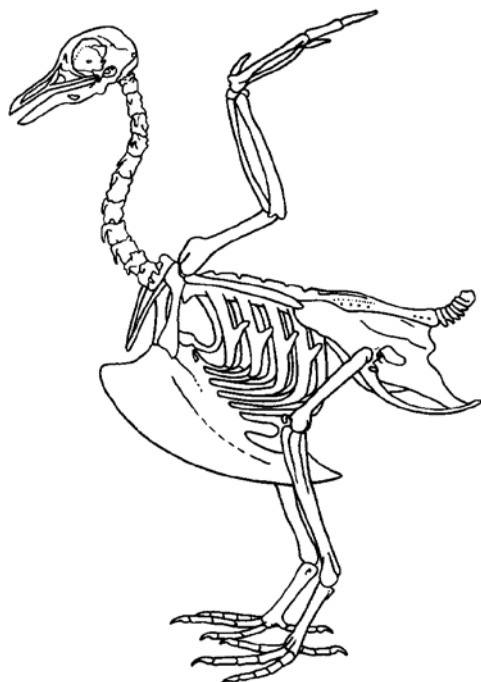


Figure 5. Extension (a) and flexion (b) 3 months following total wrist arthroplasty.

suffering either rheumatoid arthritis or osteoarthritis mostly of a post-traumatic nature. Newer implant designs have eliminated many of the detrimental characteristics of older designs and have excellent inherent stability. While there is a fairly steep learning curve to the implantation of these implants due to less precise instrumentation, the instrumentation sets have been improving over time and the predictability of alignment and cuts has improved as well. The dislocation rate is extremely low and the loosening rate also quite low over a five- to seven-year follow up interval. Most patients in our series have been advised not to lift greater than ten pounds in the hand which contains the total wrist implant from a safety perspective. While this is a fairly arbitrary number and there's really no data on how much patients

can lift with a total wrist implant on a long term basis, we have felt this to be a reasonable weight limit. Nevertheless, we are aware of several patients who lift significantly greater forces without any adverse sequelae in their long term follow up. The overall range of motion of these patients is approximately fifty percent of their normal wrist and this allows almost all activities of daily living to be accomplished without difficulty. (Figures 5a & 5b) The pain relief following this procedure is quite predictable and rivals that associated with other joint replacements having a longer history.

It is our opinion that total wrist replacement is a viable option for patients having complete degenerative changes of the radiocarpal joint and can provide excellent outcomes on a relatively long term basis with improved overall function.



REFERENCES

1. Ward CM, Kuhl T, Adams BD. Five to ten-year outcomes of the universal total wrist arthroplasty in patients with rheumatoid arthritis. *J Bone Joint Surg Am.* 2011 May;93(10):914-9.
2. Adams BD. Complications of wrist arthroplasty. *Hand Clin.* 2010 May;26(2):213-20.
3. Ferreres A, Lluch A, Del Valle M. Universal total wrist arthroplasty: midterm follow-up study. *J Hand Surg Am.* 2011 Jun;36(6):967-73.
4. Kamal R, Weiss APC. Total Wrist Arthroplasty for the Patient with Non-rheumatoid Arthritis. *J Hand Surg Am.* 2011 Jun;36(6):1071-2. Epub 2011 Apr 12.
5. Trieb K. Treatment of the wrist in rheumatoid arthritis. *J Hand Surg Am.* 2008 Jan;33(1):113-23.
6. Adams BD. Total wrist arthroplasty. *Tech Hand Up Extrem Surg.* 2004 Sep;8(3):130-7.
7. Anderson MC, Adams BD. Total wrist arthroplasty. *Hand Clin.* 2005 Nov;21(4):621-30.
8. Johnson ST, Patel A, Calfee RB, Weiss APC. Pisi-form impingement after total wrist arthroplasty. *J Hand Surg Am.* 2007 Mar;32(3):334-6.

Arnold-Peter C. Weiss, MD, is a Professor of Orthopaedics and Dean of Admissions at The Warren Alpert Medical School of Brown University, and a staff surgeon in the Division of Hand, Upper Extremity and Microvascular Surgery of the Department of Orthopaedics at Rhode Island Hospital.

Edward Akelman, MD, is Professor and Vice Chairman of Orthopaedics at the Warren Alpert Medical School of Brown University, and the head of the Division of Hand, Upper Extremity and Microvascular Surgery of the Department of Orthopaedics at Rhode Island Hospital.

Disclosure of Financial Interests

Edward Akelman, MD, does not have any financial interest to disclose.

Peter-Arnold C. Weiss, MD, has financial interest in DePuy, Inc.

CORRESPONDENCE

Arnold-Peter C. Weiss, MD
University Orthopedics, Inc.
2 Dudley Street, Suite 200
Providence, RI 02905
e-mail: apcweiss@brown.edu

Glenohumeral Arthritis and Total Shoulder Replacement

Lee A. Kaback, MD, Andrew Green, MD, and Theodore A. Blaine, MD

INTRODUCTION

Although the shoulder is the second most commonly reported site of chronic joint pain after the knee (30.6 vs 63.4%), clinically significant arthritis of the glenohumeral joint is relatively uncommon.¹ The shoulder is the third most common large joint to require surgical reconstruction, after the knee and hip; shoulder arthroplasty accounting for three percent and hip and knee accounting for 96 percent of all inpatient arthroplasty procedures performed in 2006. From 1998 to 2008 there was a 2.5 times increase (from 19,000 to 47,000) in the number of shoulder arthroplasties performed in the United States with more than two thirds performed on patients older than age 65.² Approximately two thirds of shoulder replacements are performed on females.

Primary glenohumeral osteoarthritis is the most common etiology followed by rotator cuff tear arthropathy, post-traumatic arthritis, avascular necrosis and rheumatoid arthritis. There are a variety of non-operative and operative treatment modalities available, ranging from activity modification and nonsteroidal anti-inflammatory medications to surgical reconstruction with shoulder replacement. Contemporary shoulder arthroplasty designs offer options for management of advanced arthritis that have proven to provide predictably successful outcomes with improvement in pain and function.

ANATOMY AND PATHOPHYSIOLOGY

The glenohumeral joint functions as a ball and socket. It normally consists of a congruent humeral head and glenoid

that articulate through a smooth and well-lubricated cartilage surface. In contrast to the hip joint, the glenohumeral joint has very little intrinsic skeletal stability and is highly dependent upon the surrounding soft tissues (labrum, capsule, ligaments, and rotator cuff) for stability. Primary glenohumeral osteoarthritis is characterized by gradual articular cartilage loss typically beginning on the posterior glenoid and central aspect of the humeral head with osteophytes forming around the anatomic neck of the humerus. (Figure 1) Limitation of shoulder motion results from articular deformity and capsular contracture. (Figure 2) In some cases there can be dramatic internal rotation contracture, eccentric posterior glenoid erosion and posterior subluxation of the humeral head. While there is usually minimal involvement of the rotator cuff in patients with primary glenohumeral osteoarthritis, rotator cuff tear arthropathy is thought to be the result of chronic massive rotator cuff tearing with altered glenohumeral kinematics and joint nutrition.³ Rheumatoid arthritis is a systemic inflammatory disease that affects all of the periarticular tissues including the articular cartilage, bone and soft tissues. Rheumatoid involvement of the shoulder results in gradually worsening joint destruction with bony erosion as well as rotator cuff tearing and degeneration. The prevalence of advanced rheumatoid involvement of the shoulder has been substantially reduced by disease modifying pharmaceuticals. Post-traumatic glenohumeral arthritis is a relatively uncommon sequelae of proximal humerus fractures and is the result of articular incongruity, fracture nonunion, or post-traumatic

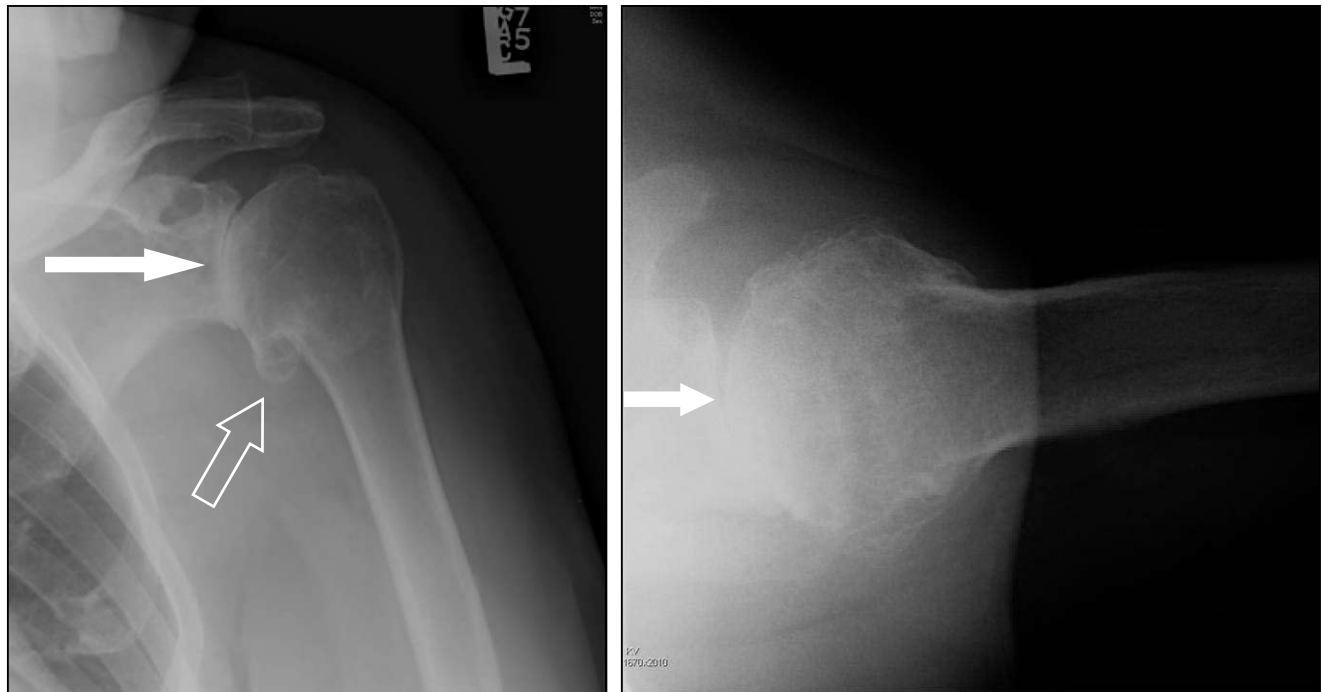


Figure 1a (left) and b (right). (a) True anterior posterior view of a left shoulder with advanced glenohumeral osteoarthritis. Note the joint space narrowing (solid arrow) and inferior humeral neck osteophytes that are characteristic of this condition. (b) Axillary lateral view of the same left shoulder demonstrating joint space narrowing (solid arrow).

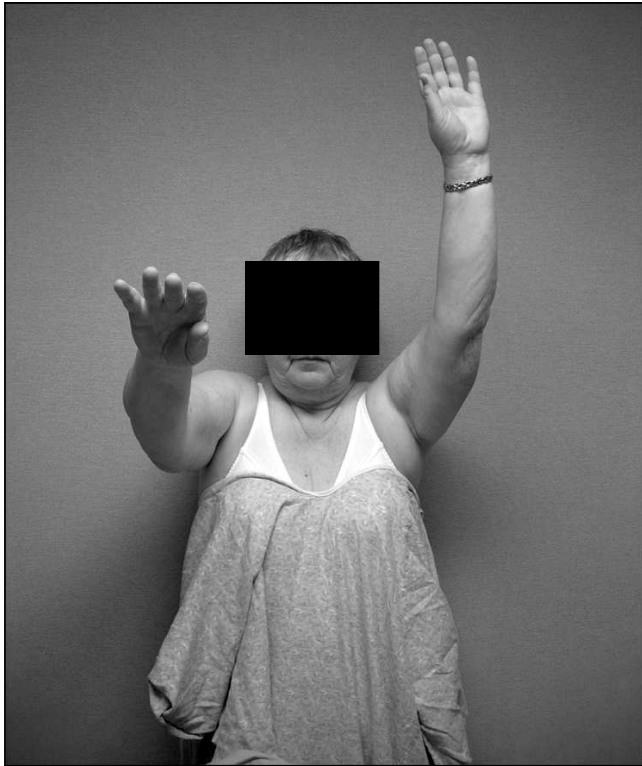

Figure 2. This is a 66 year old patient with glenohumeral osteoarthritis of the right shoulder. Note the limitation of shoulder elevation typical of osteoarthritis.

avascular necrosis, and is more commonly associated with open reduction and internal fixation of severe displaced fractures.

PATIENT EVALUATION

Patients with shoulder pain are evaluated with a thorough history and physical examination. Standard radiographic views used to assess glenohumeral arthritis include a true anteroposterior view, and axillary lateral view. (Figure 1) Both of these projections clearly demonstrate the joint space compared to typical routine shoulder radiographs. The key features include decreased glenohumeral joint space, osteophytes, subluxation, and bony deformity. In most cases, advanced imaging is not required to determine the diagnosis of glenohumeral arthritis. However, ultrasound, MRI or CT arthrogram should be obtained if there is a question about the integrity of the rotator cuff and surgery is being considered. In addition to the presence of a tendon tear, the quality of the rotator cuff musculature can be assessed for atrophy and fatty degeneration which are indicators of the chronicity of the pathology as well as function. A diagnosis of chronic large and massive rotator cuff tear can usually be established based upon the findings of a physical examination with spinati atrophy and rotator cuff weakness, and plain radiographs. (Figure 3) **Computed tomographic (CT)** scans are obtained to evaluate the anatomy of the glenoid, bony erosion and wear, in preparation for shoulder replacement surgery.⁴

TREATMENT

Treatment for glenohumeral arthritis begins with non-operative management including oral non-steroidal anti-inflammatory and analgesic medications, range of motion and

strengthening exercises, corticosteroid injections, and activity modifications. The use of viscosupplementation is controversial and currently not FDA approved for use in the shoulder. Recent reports suggest that there might be some beneficial effect and further study is required to definitively establish efficacy.⁵ When non-operative treatment fails to provide adequate symptomatic relief various surgical options including arthroscopy, hemiarthroplasty (humeral head replacement), and total shoulder arthroplasty can be considered. Options of historical interest include shoulder arthrodesis and resection arthroplasty which reserved for salvage of severe post-arthroplasty infections or shoulder paralysis.

Arthroscopic debridement may be considered in some patients who are not candidates for shoulder replacement.⁶ These include younger patients and patients with less severe disease. Arthroscopic procedures allow for removal of loose bodies, capsular release, synovectomy, and debridement of loose flaps of cartilage. Some patients will have improvement of symptoms; however these results deteriorate with time. Patients with advanced glenohumeral arthritis are not good candidates for arthroscopy which can exacerbate their symptoms.

The indications for shoulder arthroplasty include severe proximal humerus fractures, glenohumeral osteoarthritis, post-traumatic arthritis, rotator cuff tear arthropathy, avascular necrosis, capsulorrhaphy arthropathy, inflammatory arthritis, and failed previous shoulder arthroplasty. The first modern shoulder replacement design was developed by Dr Neer in the 1950s to treat severe displaced proximal humerus fractures.⁷ The initial design was a metallic humeral head replacement. An all polyethylene glenoid component was subsequently introduced because arthritic patients treated with humeral head replacement tended to have inadequate

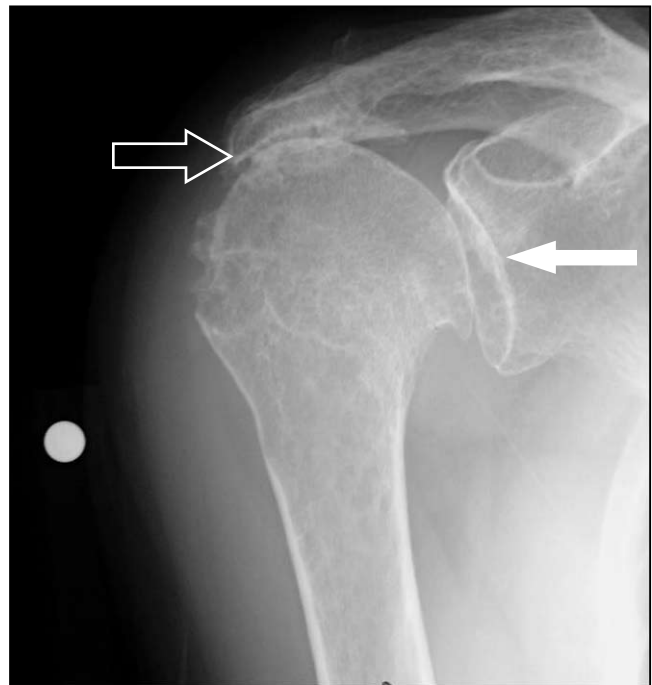


Figure 3. This is a true anterior posterior plain radiograph of a right shoulder with rotator cuff tear arthropathy. Note the elevation of the humeral head relative to the glenoid (solid arrow) as well as the narrowing of the acromiohumeral space (open arrow). These findings are characteristic of a chronic massive rotator cuff tear.

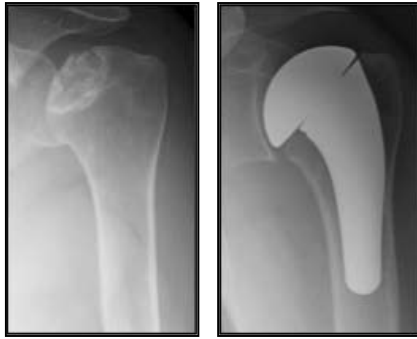

Figure 4a (left) and b (right). Pre (a) and postoperative (b) anterior posterior plain radiographs of a patient with avascular necrosis and humeral head collapse without glenoid involvement treated with humeral head replacement (hemiarthroplasty).

pain relief. Further advances led to implant systems that emphasize anatomic reconstruction of the glenohumeral joint. More recently, reverse total shoulder replacement designs were developed to treat patients with rotator cuff deficiency.

HEMIARTHROPLASTY (HUMERAL HEAD RESURFACING AND REPLACEMENT)

Humeral head replacement is primarily used to treat patients who have isolated articular involvement of the

humerus. Patients with early stage avascular necrosis and post-traumatic arthritis may have relatively normal glenoid articular surface and can be treated with a humeral head replacement or humeral resurfacing implant.^{8,9} (Figure 4) There are occasional patients with primary glenohumeral osteoarthritis who have either minimal involvement of the glenoid or who desire a vigorous lifestyle for whom a hemiarthroplasty is appropriate.¹⁰ This can be combined with biologic tissue resurfacing of the glenoid or concentric glenoid reaming. However, several studies have demonstrated that total shoulder replacement yields more reliable pain relief compared to humeral head replacement (ball replacement) for osteoarthritis.¹¹⁻¹³ Although there is a definite tendency to consider humeral head replacement in younger patients with glenohumeral arthritis and convert to a total shoulder in the future if needed, the revision surgery is more difficult and complicated than primary total shoulder replacement.¹⁴

Rotator cuff tear arthropathy was traditionally treated with humeral hemiarthroplasty. However, the outcomes were very variable and the recent advent of reverse total shoulder replacement has provided more predictable and durable

results.¹⁵ Humeral head replacement is also preferred over anatomic total shoulder replacement for rheumatoid patients when there is rotator cuff disease or glenoid erosion.¹⁶

Resurfacing (stemless) humeral head replacement may be considered in some patients where the bone of the humeral head will support a stemless prosthesis. (Figure 5) One potential advantage of this prosthesis design is that it preserves the humeral bone in the event that a revision replacement is required in the future. In general, these designs are indicated for younger patients who wish to continue an active lifestyle and some older patients where possible conversion to an alternate prosthesis (e.g., reverse shoulder replacement) may be required.²²

ANATOMIC TOTAL SHOULDER REPLACEMENT

The goal of anatomic total shoulder replacement is to restore normal bony anatomy and shoulder kinematics while replacing both the humeral and glenoid articular surfaces and is indicated when there is both humeral and glenoid arthritis with an intact and functioning rotator cuff. (Figure 6) This is the preferred treatment for advanced glenohumeral os-

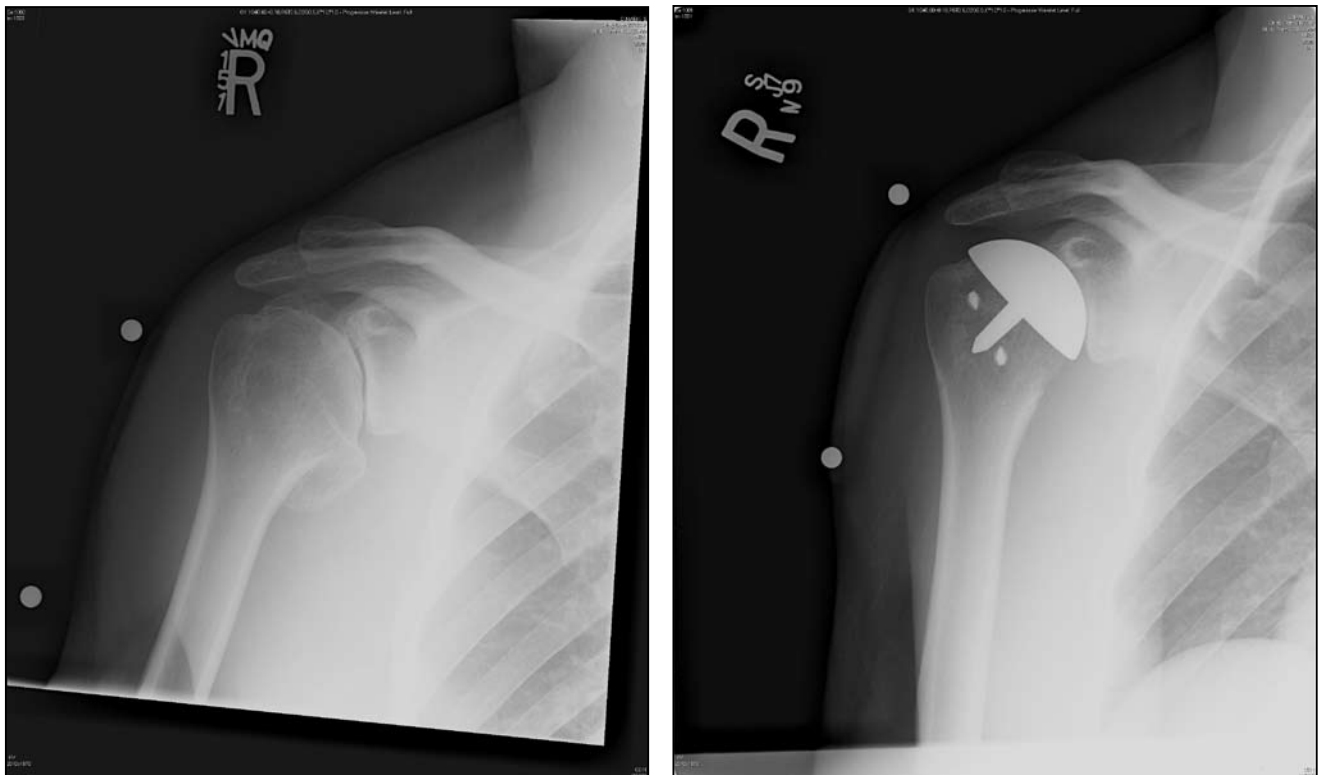


Figure 5a (left) and b (right). (a) True anterior posterior plain radiograph of a 43 year active male with pain who failed previous arthroscopic surgery. (b) Post-operative radiograph after humeral resurfacing.

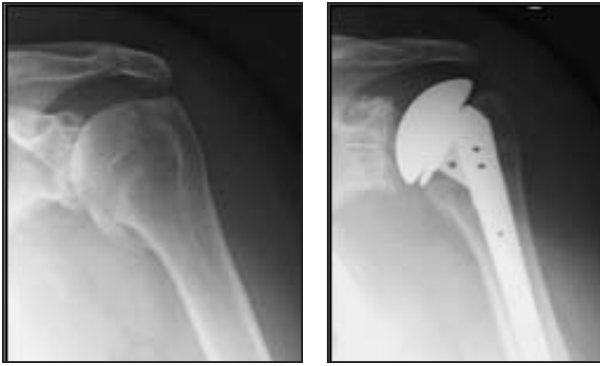

Figure 6a (left) and b (right). Pre (a) and post-operative (b) plain radiographs of a 78 year old female with advanced glenohumeral osteoarthritis who was treated with an anatomic total shoulder replacement.

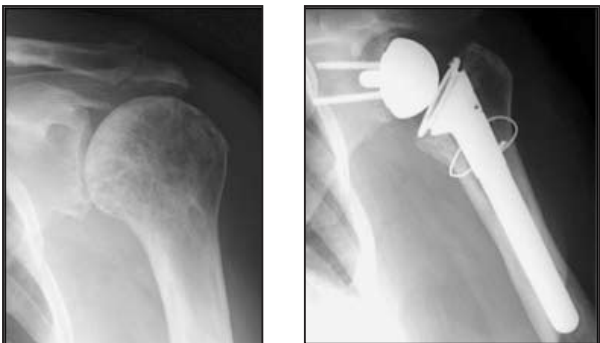


Figure 7a (left) and b (right). (a) True anterior posterior plain radiograph of a patient with rotator cuff tear arthropathy. (b) Post-operative radiograph after reverse total shoulder replacement.

teoarthritis.¹⁷ Total shoulder replacement in the presence of rotator cuff tearing is associated with early glenoid implant loosening and failure. Total shoulder replacement is also indicated in cases of rheumatoid arthritis with a good rotator cuff, avascular necrosis and post-traumatic arthritis with glenoid involvement. Patients with rheumatoid arthritis and an intact rotator cuff have better outcomes and lower revision rate after total shoulder replacement compared to humeral head replacement.¹⁶ Over 95% of patients will achieve satisfactory results, with improvements in pain relief, range of motion, and function. The survival of total shoulder replacement is comparable to the hip, with 85% of prosthesis remaining intact at 20 years.¹⁸ Surgeon experience is important; recent studies have shown that the complication rate after total shoulder replacement is reduced when performed by surgeons and at centers with greater volume of shoulder replacements.¹⁹⁻²¹

REVERSE SHOULDER REPLACEMENT

Reverse total shoulder replacement was designed for use in patients with rotator cuff insufficiency. This includes patients with chronic massive unreparable rotator cuffs with or without glenohumeral arthritis, rheumatoid arthritis and rotator cuff tearing, some patients with severe proximal humerus fractures, and cases requiring revision of a failed previous anatomic shoulder replacement.²²⁻²⁶ In patients with rotator cuff deficiency, total shoulder replacement is

prone to early failure of the glenoid prosthesis. In these patients, hemiarthroplasty or reverse shoulder arthroplasty are a more appropriate surgical procedures. This revolutionary shoulder arthroplasty was first approved for use in the United States by the FDA in 2004. It was reported that approximately 2000 reverse total shoulder arthroplasties were performed in the U.S. in 2004 and that market analysis predicts that this number will increase to 30,000 in 2012.

Reverse total shoulder replacement “reverses” the normal relationships in the shoulder, replacing the native glenoid socket with a ball (glenosphere) and converting the native humeral head (ball) to a humeral socket. (Figure 4) The increased constraint of this construct allows for the intact deltoid muscle to raise the arm even in the absence of a rotator cuff. This increased constraint however, also limits the amount of stress which this prosthesis will endure, and therefore reverse total shoulder arthroplasty is typically reserved for older patients with lower functional demands.³⁰ Reverse shoulder provides dramatic improvements in pain and function in patients with the combination of glenohumeral arthritis and rotator cuff disease.

POST-OPERATIVE COURSE AND REHABILITATION

Patients having shoulder replacement surgery will typically require one to two days in the hospital. Many patients have almost immediate improvements in pain. Physical therapy begins immediately and the program is tailored to the type of prosthesis used. In cases of anatomic shoulder replacement, passive range of motion exercises begin immediately after surgery. Active use and range of motion begins after six weeks. Strengthening is avoided for the first six weeks to prevent injury to the healing subscapularis tendon. Patients wear a sling to protect this repair for four to six weeks. Patients are able to resume their usual daily activities after three months. For reverse total shoulder replacement is associated with an increased risk of post-operative dislocation is increased. Therefore physical therapy is often more limited during the first six weeks post-operatively. Rehabilitation exercises are continued for at least six months to achieve an optimal outcome.

SUMMARY

Shoulder replacement surgery is a reliable procedure that provides predictable results in patients with all types of glenohumeral arthritis. When performed by an experienced surgeon for the right indications, and with appropriate physical therapy, dramatic improvements in pain and function are seen in the majority of patients. With the recent availability of the reverse prosthesis, even patients with rotator cuff deficiency may have pain relief and restoration of shoulder function after reverse shoulder arthroplasty.

Discussion of off-label usage

Viscosupplementation, hyaluronans are mentioned. Product not listed.

REFERENCES

1. *The Burden of Musculoskeletal Disease in the United States: Prevalence, Societal and Economic Cost.* American Academy of Orthopaedic Surgeons Rosemont, IL. 2008.
2. Kim SH, Wise BL, Zhang Y, Szabo RM. Increasing Incidence of Shoulder Arthroplasty in the United States. *J Bone Joint Surg Am.* 2011;93-A:2249-54
3. Neer CS 2nd, Craig EV, Fukuda H. Cuff-tear arthropathy. *J Bone Joint Surg Am.* 1983;65-A:1232-44.
4. Nyffeler RW, Jost B, Pfirrmann CWA, Gerber C. Measurement of glenoid version: Conventional radiographs versus computed tomography scans. *J Shoulder Elbow Surg.* 2003;12:493-6.

5. Blaine T, Moskowitz R, Udell J, et al. Treatment of persistent shoulder pain with sodium hyaluronate: a randomized, controlled trial. A multicenter study. *J Bone Joint Surg Am.* 2008;90-A:970–9.
6. Weinstein DM, Bucchieri JS, Pollock RG, Flatow EL, Bigliani LU. Arthroscopic debridement of the shoulder for osteoarthritis. *Arthroscopy.* 2000;16(5):471–76.
7. Neer CS, 2nd. Replacement arthroplasty for glenohumeral osteoarthritis. *J Shoulder Elbow Surg.* 1974;56-A(1):1–13.
8. Hattrup SJ, Cofield RH. Osteonecrosis of the humeral head: results of replacement. *J Shoulder Elbow Surg.* 2000;9:177–82.
9. Smith RG, Sperling JW, Cofield RH, et al. Shoulder hemiarthroplasty for steroid-associated osteonecrosis. *J Shoulder Elbow Surg.* 2008;17(5):685–8.
10. Bailie DS, Llinas PJ, Ellenbecker TS. Cementless Humeral Resurfacing Arthroplasty in Active Patients Less Than Fifty-five Years of Age. *J Bone Joint Surg Am.* 2008; 90-A; 110–7.
11. Gartsman GM, Roddey TS, Hammerman SM. Shoulder arthroplasty with or without resurfacing of the glenoid in patients who have osteoarthritis. *J Bone Joint Surg Am.* 2000;82-A:26–34.
12. Lo IK, Litchfield RB, Griffin S, et al. Quality-of-life outcome following hemiarthroplasty or total shoulder arthroplasty in patients with osteoarthritis. A prospective, randomized trial. *J Bone Joint Surg Am.* 2005;87-A:2178–85.
13. Bryant D, Litchfield R, Sandow M, et al. A comparison of pain, strength, range of motion, and functional outcomes after hemiarthroplasty and total shoulder arthroplasty in patients with osteoarthritis of the shoulder. A systematic review and meta-analysis. *J Bone Joint Surg Am.* 2005;87-A:1947–56.
14. Bartelt R, Sperling JW, Schleck CD, Cofield RH. Shoulder arthroplasty in patients aged fifty-five years or younger with osteoarthritis. *J Shoulder Elbow Surg.* 2011;20(1):123–30.
15. Sanchez-Sotelo J, Cofield RH, Rowland CM. Shoulder hemiarthroplasty for glenohumeral arthritis associated with severe rotator cuff deficiency. *J Bone Joint Surg Am.* 2001;83-A(12):1814–22.
16. Sperling JW, Cofield RH, Schleck CD, Harnsen WS. Total shoulder arthroplasty versus hemiarthroplasty for rheumatoid arthritis of the shoulder: Results of 303 consecutive cases. *J Shoulder Elbow Surg.* 2007;16:683–90.
17. Bishop JY, Flatow EL. Humeral head replacement versus total shoulder arthroplasty: Clinical outcomes—A review. *J Shoulder Elbow Surg.* 2005;14:1415–6S.
18. Deshmukh AV, Koris M, Zurakowski D, Thornhill TS. Total shoulder arthroplasty: long-term survivorship, functional outcome, and quality of life. *J Shoulder Elbow Surg.* 2005;14(5):471–9.
19. Hammond JW, Queale WS, Kim TK, McFarland EG. Surgeon experience and clinical and economic outcomes for shoulder arthroplasty. *J Bone Joint Surg Am.* 2003;85-A:2318–24.
20. Jain N, Pietrobon R, Hocker S, et al. The relationship between surgeon and hospital volume and outcomes for shoulder arthroplasty. *J Bone Joint Surg Am.* 2004;86-A:496–505.
21. Izquierdo R, Voloshin I, Edwards S, et al. Treatment of glenohumeral osteoarthritis: AAOS clinical practice guideline. *J Amer Acad Orthop Surgs.* 2010;18(6):375–82.
22. Cuff D, Pupello D, Virani N, Levy J, Frankle M. Reverse shoulder arthroplasty for the treatment of rotator cuff deficiency. *J Bone Joint Surg Am.* 2008;90:1244–51.
23. Gerber C, Pennington SD, Nyffeler RW. Reverse total shoulder arthroplasty. *Journal American Academy of Orthopaedic Surgeons* 2009;17(5):284–95.
24. Matsen FA, 3rd, Boileau P, Walch G, Gerber C, Bicknell. The reverse total shoulder arthroplasty. *J Bone Joint Surg Am.* 2007;89-A:660–7.
25. Mulieri P, Dunning P, Klein S, et al. Reverse shoulder arthroplasty for the treatment of irreparable rotator cuff tear without glenohumeral arthritis. *J Bone Joint Surg Am.* 2010;92-A:2544–56.
26. Walker M, Willis MP, Brooks JP, et al. The use of the reverse shoulder arthroplasty for treatment of failed total shoulder arthroplasty. *J Shoulder Elbow Surg.* 2012;21:514–22.

Lee A. Kaback, MD, currently works in private practice in Albany, NY, specializing in shoulder and elbow reconstruction.

Andrew Green, MD, is an Associate Professor of Orthopedic Surgery and Chief of Division of Shoulder and Elbow Surgery at the Warren Alpert Medical School of Brown University, and Practices at University Orthopedics, Inc.

Theodore A. Blaine, MD, is an Associate Professor at the Yale University School of Medicine, and Chief of Shoulder and Elbow Surgery at Yale Orthopaedics and Rehabilitation.

Disclosure of Financial Interests

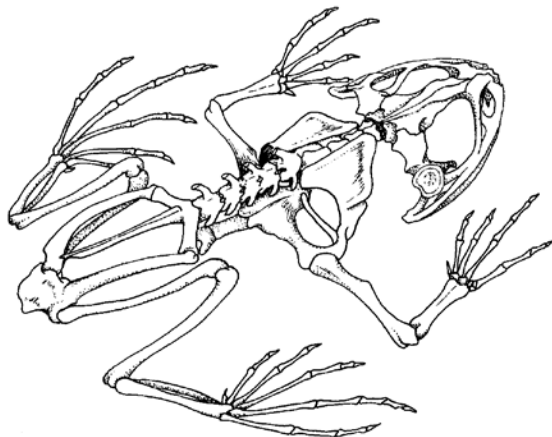Lee A. Kaback, MD, and Andrew Green, MD, have no financial interests to disclose.

Theodore Blaine, MD, is a consultant and on the speakers' bureau for Zimmer Corp. and receives grant research support from Tomier Corp.

CORRESPONDENCE

Theodore A. Blaine, MD
 Yale University Department of
 Orthopaedics and Rehabilitation
 Yale University School of Medicine
 phone: 203-737-2348
 e-mail: theodore.blaine@yale.edu

Andrew Green, MD
 University Orthopedics, Inc
 2 Dudley Street, Suite 200
 Providence, RI 02905
 e-mail: agreen@universityorthopedics.com



Diagnosis and Management of Heel and Plantar Foot Pain

Gregory A. Sawyer, MD, Craig R. Lareau, MD, and Jon A. Mukand, MD, PhD

INTRODUCTION

Heel pain is a common complaint encountered by primary care physicians. Misdiagnosis is not uncommon because of the intricate anatomy of the heel, where many structures lie in close proximity to one another. While there are traumatic (high-energy), infectious, oncologic, vascular and systemic causes of heel pain, this article will focus on the most common ones: repetitive microtrauma and compression of structures within confined spaces. Pathologic causes can be broadly categorized as degenerative, neurologic, or traumatic.

PLANTAR FASCIITIS

The plantar fascia is an aponeurosis of collagen fibers that originate from the anteromedial calcaneus, course distally on the plantar foot, and divide into five insertions on the proximal phalanx of each digit.¹ The fascia helps maintain the arch of the foot and serves a dynamic function during the gait cycle.¹ The most common cause of heel pain, plantar fasciitis is due to inflammation at the calcaneal origin,^{1,2} resulting in fascial degeneration and microtears.¹

Approximately two million people, typically 40 to 60 years old, are treated annually in the United States for plantar heel pain.^{1,3} Their pain is typically worse with the first steps in the morning and after prolonged standing. It is usually stabbing, non-radiating, and not associated with neurologic symptoms.² Risk factors for plantar fasciitis include running, flat foot deformity (pes planus), professions requiring prolonged standing, obesity, and limited ankle dorsiflexion.¹

Patients generally have focal tenderness over the plantar-medial calcaneus¹ that worsens with passive toe dorsiflexion and a calf raise. Tightness of the Achilles tendon is common. Imaging is not required for the diagnosis and is recommended only for patients who fail conservative management.

Nonsurgical treatment—successful in greater than 90% of cases—should be

attempted for at least six months and may require up to 18 months.¹ Conservative measures include **non-steroidal anti-inflammatory drugs (NSAIDs)**, stretching exercises, physical therapy, orthoses (night splints, cast immobilization), cortisone injections, and extracorporeal shock wave therapy, all with varying success.^{1,2} If conservative therapy fails, surgery may be considered. Plantar fascial release, either open or endoscopic, is the procedure of choice, with success rates of 70-90%.²

HEEL PAD SYNDROME

The heel pad beneath the calcaneus consists of adipose tissue within fibrous septae and allows repetitive load bearing. It is less elastic in elderly and diabetic patients, which leads to inflammation and edema. Diabetic plantar tissue is stiffer than healthy tissue and has a lower capacity to withstand compressive and shear stresses. Heel pad atrophy is often contributory. This diagnosis is more common in obese patients due to higher loads.⁴

Achilles tendon disorders include a spectrum from chronic degenerative injuries to acute tendon ruptures.

Frequently misdiagnosed as plantar fasciitis, heel pad syndrome is characterized by deep, non-radiating pain involving the weight-bearing portion of the calcaneus. Symptoms worsen with walking barefoot or on hard surfaces and are relieved in the absence of heel pressure. Typically, there is tenderness over the plantar aspect of the calcaneal tuberosity. Swelling is variably present and, unlike plantar fasciitis, pain does not occur with passive motion of the ankle or toes.

Treatment consists of NSAIDs and shoes with adequate heel padding. Corticosteroid injections are contraindicated as they can cause atrophy of the plantar fat.⁵ Surgery cannot restore the normal architecture of the heel pad. In addition, the plantar skin is prone to wound-healing problems.

ACHILLES TENDON DYSFUNCTION

Achilles tendon disorders include a spectrum from chronic degenerative injuries to acute tendon ruptures. The strongest and thickest tendon in the human body, it is the insertion of the gastrocnemius and soleus muscles onto the posterior calcaneal tuberosity.⁶ “Achilles tendinitis” is a misnomer as the tendon itself does not undergo inflammation.⁷ The tendon’s blood supply is provided by a paratenon, a single layer of cells encasing the structure,⁷ as well as by the musculotendinous junction.⁸ Plain radiographs can identify both calcific tendinous changes and Haglund deformities (discussed below). Ultrasound is safe, quick and effective but variable operator skills may limit its use in the community.⁷ MRI provides the most detailed information about the Achilles tendon and surrounding soft tissue and bony structures.⁷ One classification scheme divides Achilles tendon dysfunction into three categories: peritendinitis, tendinosis, and peritendinitis with tendinosis.⁹

Peritendinitis, also referred to as paratenonitis, is inflammation of the surrounding paratenon.⁷ Common in athletes due to poor-fitting shoes, it involves focal swelling, diffuse discomfort, and tenderness to palpation. Conservative therapy includes proper shoes, activity modification, rest, and NSAIDs.⁷ Surgery involves excision of the thickened paratenon, but is rarely required.¹⁰

Achilles tendinosis is a degenerative process related to aging and repetitive microtrauma and microtearing.⁷ Degeneration usually occurs in the hypovascular zone of the tendon, two to six centimeters proximal to the calcaneal insertion.⁷ Classically seen in middle-aged men with

increased activity levels, tendinosis occurs gradually. Patients present with pain and nodular thickening of the middle-third of the tendon.⁸ Sharp pain may indicate a partial tendon tear. If detected before tendon rupture, treatment is conservative: activity modification, orthotics, and physical therapy for eccentric strengthening and range of motion exercises.⁷ Corticosteroid injections may further weaken and rupture the tendon, so they are contraindicated.⁸ Surgery is needed in 25% of cases, for debridement of the degenerative portion of the tendon.⁷

RETROCALCANEAL BURSITIS & HAGLUND DEFORMITY

The retrocalcaneal bursa is located between the posterosuperior aspect of the calcaneal tuberosity and the Achilles tendon. A Haglund deformity is a prominence of the postero-superior lateral calcaneus. Due to these close anatomic relationships, retrocalcaneal bursitis can be associated with a Haglund deformity and insertional Achilles tendonitis.¹¹

Retrocalcaneal bursitis causes pain anterior to the Achilles tendon, just proximal to its insertion. In contrast, Haglund deformity tends to cause pain superolateral to the Achilles insertion. The most common cause is irritation caused by the shoe counter. It is seen in

athletes, particularly those involved with uphill running, because ankle dorsiflexion compresses the bursa between the Achilles tendon and calcaneus. One should be wary of a systemic diagnosis, such as inflammatory arthritis, in a patient with bilateral symptoms.

Patients with retrocalcaneal bursitis typically have boggiess along the medial and lateral aspects of the Achilles tendon.¹² Tenderness with the two-finger squeeze test (medial and lateral pressure anterior to the Achilles tendon above the calcaneus) is a classic finding.⁷ Pain may occur with passive ankle dorsiflexion and resisted ankle plantarflexion as these motions decrease the space available for the bursa.¹²

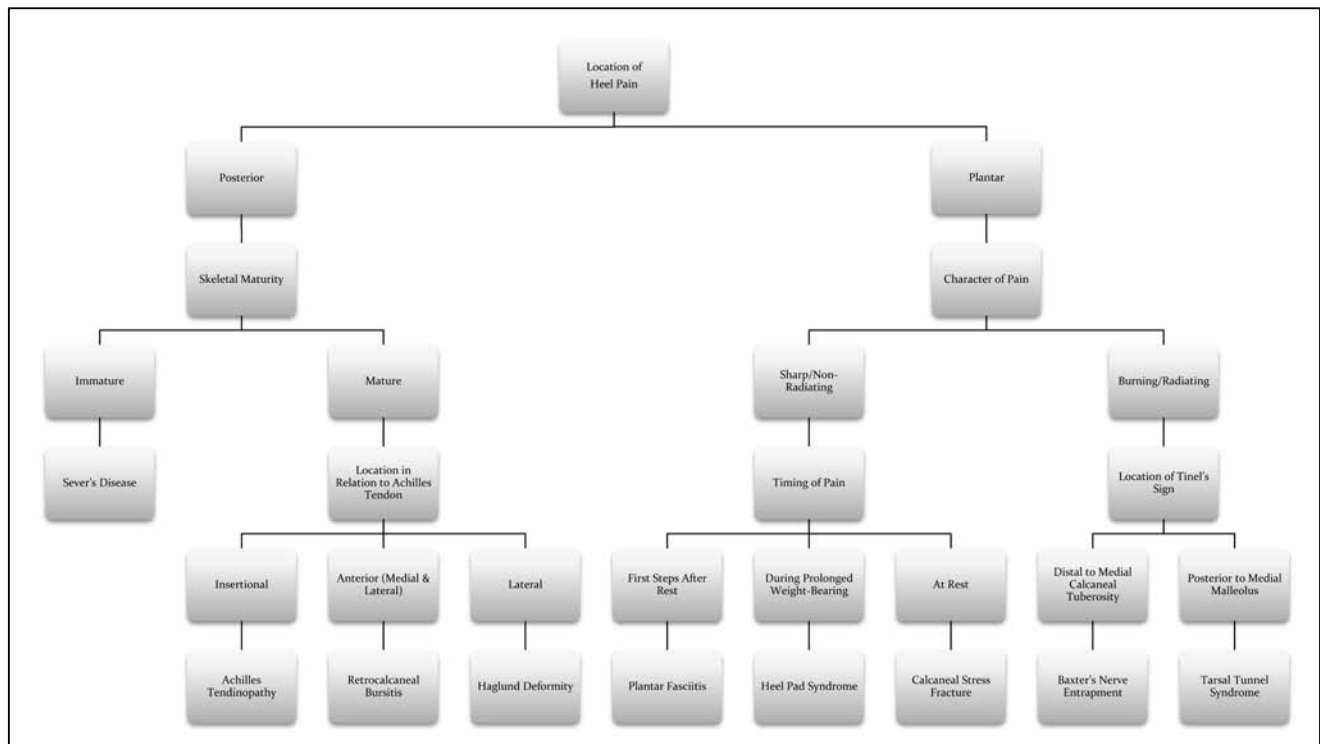
Conservative treatment includes ice, activity modification, open-heeled shoes and NSAIDs. Corticosteroid injections should be avoided in the posterior heel as they increase the risk of Achilles tendon degeneration and rupture.¹³ Surgical procedures involve some combination of resection of the calcaneal prominence, retrocalcaneal bursectomy, and Achilles tendon debridement. Surgery is not always curative. In one series, symptoms were completely relieved in only 69.4% of patients and 14.3% became worse due to infection, sural nerve injury or painful scar formation.¹⁴

TARSAL TUNNEL SYNDROME

The tarsal tunnel is a fibro-osseous space formed by the flexor retinaculum of the ankle, posterior and distal to the medial malleolus. Often compared to carpal tunnel syndrome, it is an entrapment neuropathy of the tibial nerve resulting in pain and paresthesias at the plantar aspect of the foot.¹⁵ The tarsal tunnel also contains the posterior tibial tendon, flexor digitorum longus tendon, flexor hallucis longus tendon, and the posterior tibial artery and vein. The most frequent causes of this neuropathy include trauma, space-occupying lesions, and foot deformity.¹⁵

Complaints are often non-specific and poorly localized, making the diagnosis difficult. Pain and paresthesias are intermittent or constant, and frequently associated with proximal or distal radiation. Symptoms worsen with prolonged standing and exercise and are relieved by elevation and rest. Night pain is also a relatively common complaint. Physical examination is often non-specific, but decreased sensation over the plantar foot and a positive Tinel's sign (paresthesias with percussion over the nerve) are pathognomic.¹⁵ Weakness is not common, but when present, indicates severe compression.¹⁵

Weight-bearing radiographs evaluate foot deformity and traumatic injuries and



Heel pain flowchart.

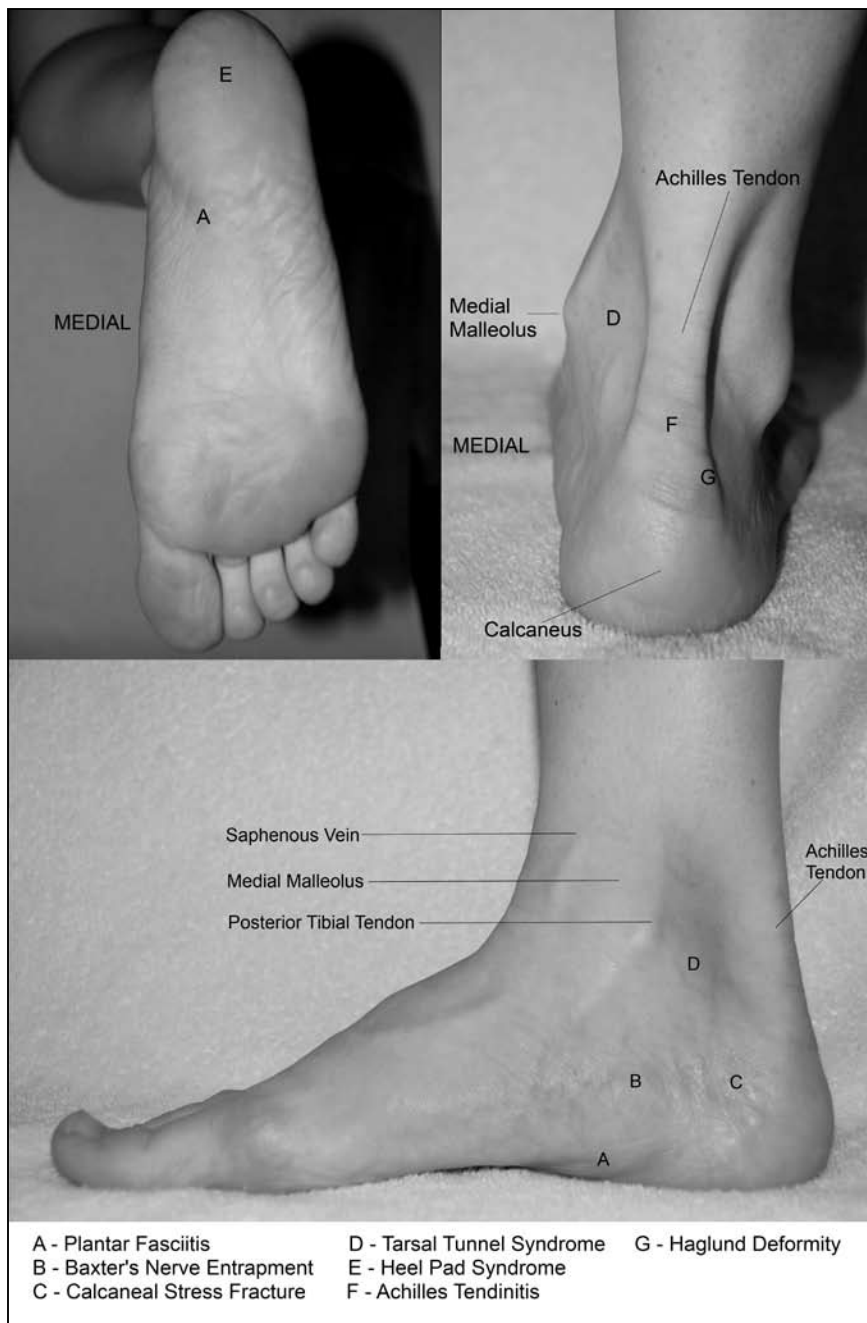


Figure 1. Heel pain anatomy.

MRI scans may reveal compressive soft tissue masses.¹⁵ Tibial motor and sensory nerve studies (latencies, amplitudes, conduction velocities) are critical in the diagnosis and accurate in 90% of cases.¹⁶

Treatment depends on the specific cause of the symptoms. For space-occupying lesions, surgery is often required but can be treacherous due to the close proximity to the neurovascular bundle.¹⁵ Patients with pes planus deformity that stretches the tibial nerve may benefit from custom orthotics.¹⁵ Inflammatory tenosynovitis causing tibial nerve com-

pression may benefit from NSAIDs, rest, and immobilization in a walking boot or cast. Local corticosteroid injections may decrease inflammation, with careful avoidance of intra-tendinous and intra-vascular injections.¹⁵

BAXTER'S NERVE ENTRAPMENT

Baxter's nerve is the first branch of the lateral plantar nerve. It courses deep to the abductor hallucis and **flexor digitorum brevis (FDB)** and superficial to the quadratus plantae along the medial calcaneus. This mixed nerve innervates

the quadratus plantae, FDB, and **abductor digiti quinti (ADQ)**; it also supplies sensation to the calcaneal periosteum, the long plantar ligament, and the lateral plantar skin.¹⁷ Compression occurs deep to the abductor hallucis where the nerve turns and courses laterally. Patients complain of medial heel pain four to five cm anterior to the posterior aspect of the heel, or just distal to the medial calcaneal tuberosity.¹⁸ Burning pain can radiate into the tarsal tunnel (posteromedial ankle) or distally toward the plantar lateral foot.

Hindfoot valgus, or pronation, and ankle plantarflexion (Achilles tendon contracture) can increase nerve compression. A recent cadaver study demonstrated that pressure in the lateral plantar tunnel is highest in pronation and plantarflexion.¹⁹ Tinel's sign is positive if paresthesias are reproduced with tapping over the nerve beneath the abductor hallucis muscle. In chronic cases, patients may have diminished sensation in the lateral plantar foot.¹⁸ In cases of bilateral neurologic findings, spinal pathology and systemic diseases must be ruled out.

As this is primarily a clinical diagnosis, imaging is not helpful. Non-specific atrophy of the ADQ is present in 6.3% of all patients who have an MRI.²⁰ Electrodiagnostic studies confirm the diagnosis and localize compression in the lateral plantar tunnel or more proximally in the tarsal tunnel, which would affect both the medial and lateral plantar nerves.¹⁸ Rest, ice and NSAIDs should be tried for at least six months. Surgical decompression involves releasing the nerve throughout its course along the medial heel by dissecting the fascia overlying the FDB and quadratus plantae.²¹

CALCANEAL STRESS FRACTURE

The calcaneus consists primarily of less dense cancellous bone, which is susceptible to fractures. After the metatarsals, the calcaneus is the most common location for a stress fracture in the foot.²² It can occur in athletes participating in sports with repetitive axial loading as well as elderly patients with osteopenia. It is typically an overuse injury that coincides with an athlete changing to a more strenuous exercise regimen. Diffuse heel pain (medial and lateral) worsens with weight-bearing and may progress to being present at rest.

The hallmark is a positive calcaneal squeeze test, or pain with compressing the medial and lateral calcaneus.²³ Depending on the acuity of the injury, there may be swelling and ecchymosis. Radiographs (lateral view) may demonstrate an altered trabecular pattern, but are frequently interpreted as normal. Sclerosis perpendicular to the orientation of the trabeculae indicates a healing fracture.²⁴ Persistent pain may necessitate an MRI or bone scan to detect an occult fracture. The former is preferable since it also evaluates soft tissue structures that can cause heel pain.²⁴

If history and physical examination suggest a calcaneal stress fracture but the diagnosis has not been confirmed, patients should decrease their activity level. If symptoms persist and/or the diagnosis is evident on imaging, patients should not bear weight and are placed in a short leg cast. Particularly in the high-level athlete, this treatment should be continued until tenderness resolves.

SEVER'S DISEASE

Calcaneal apophysitis, or Sever's disease, is a common cause of heel pain in the pediatric athlete.²⁵ The calcaneal apophysis is the site of insertion of the Achilles tendon. Causative theories include traction and compression of the growth plate, but there is no consensus.²⁵ Patients have posterior heel pain that increases with activity. Examination reveals tenderness at the Achilles tendon insertion, heel cord tightness, and limited ankle dorsiflexion. Diagnosis is primarily clinical and the mainstay of treatment is conservative therapy with rest and NSAIDs. Severe cases may require a short period of immobilization. Both rehabilitation and preventative measures include gascrocnemius/soleus stretching and strengthening.²⁵

CONCLUSION

Heel pain is a fairly common condition due to a variety of etiologies. The appropriate diagnosis and treatment can be difficult because of various bones, nerves and connective tissues confined to small spaces and subjected to weight bearing. An algorithm (Figure 1) offers a logical diagnostic approach and Figure

2 describes the anatomical locations of various etiologies. Regardless of the cause, however, conservative therapies should be attempted for a reasonable period of time before any surgical intervention.

REFERENCES

1. Neufeld SK, Cerrato R. Plantar fasciitis: evaluation and treatment. *J Am Acad Orthop Surg.* Jun 2008;16(6):338-346.
2. League AC. Current concepts review: plantar fasciitis. *Foot Ankle Int.* Mar 2008;29(3):358-366.
3. Buchbinder R. Clinical practice. Plantar fasciitis. *N Engl J Med.* May 20 2004;350(21):2159-2166.
4. Prichasuk S. The heel pad in plantar heel pain. *J Bone Joint Surg Br.* Jan 1994;76(1):140-142.
5. Brinks A, Koes BW, Volkers AC, Verhaar JA, Bierma-Zeinstra SM. Adverse effects of extra-articular corticosteroid injections: a systematic review. *BMC Musculoskelet Disord.* 2010;11:206.
6. Mazzone MF, McCue T. Common conditions of the achilles tendon. *Am Fam Physician.* May 1 2002;65(9):1805-1810.
7. Reddy SS, Pedowitz DI, Parekh SG, Omar IM, Wapner KL. Surgical treatment for chronic disease and disorders of the achilles tendon. *J Am Acad Orthop Surg.* Jan 2009;17(1):3-14.
8. Heckman DS, Gluck GS, Parekh SG. Tendon disorders of the foot and ankle, part 2: achilles tendon disorders. *Am J Sports Med.* Jun 2009;37(6):1223-1234.
9. Puddu G, Ippolito E, Postacchini F. A classification of Achilles tendon disease. *Am J Sports Med.* Jul-Aug 1976;4(4):145-150.
10. Saltzman CL, Tearse DS. Achilles tendon injuries. *J Am Acad Orthop Surg.* Sep-Oct 1998;6(5):316-325.
11. Stephens MM. Haglund's deformity and retrocalcaneal bursitis. *Orthop Clin North Am.* Jan 1994;25(1):41-46.
12. Leitz Z, Sella EJ, Aversa JM. Endoscopic decompression of the retrocalcaneal space. *J Bone Joint Surg Am.* Aug 2003;85-A(8):1488-1496.
13. Hugate R, Pennypacker J, Saunders M, Juliano P. The effects of intratendinous and retrocalcaneal intrabursal injections of corticosteroid on the biomechanical properties of rabbit Achilles tendons. *J Bone Joint Surg Am.* Apr 2004;86-A(4):794-801.
14. Schneider W, Niehus W, Knahr K. Haglund's syndrome: disappointing results following surgery -- a clinical and radiographic analysis. *Foot Ankle Int.* Jan 2000;21(1):26-30.
15. Lau JT, Daniels TR. Tarsal tunnel syndrome: a review of the literature. *Foot Ankle Int.* Mar 1999;20(3):201-209.
16. Galardi G, Amadio S, Maderna L, et al. Electrophysiologic studies in tarsal tunnel syndrome. Diagnostic reliability of motor distal latency, mixed nerve and sensory nerve conduction studies. *Am J Phys Med Rehabil.* Jun 1994;73(3):193-198.
17. Rondhuis JJ, Huson A. The first branch of the lateral plantar nerve and heel pain. *Acta Morphol Neerl Scand.* 1986;24(4):269-279.

18. Schon LC, Glennon TP, Baxter DE. Heel pain syndrome: electrodiagnostic support for nerve entrapment. *Foot Ankle.* Mar-Apr 1993;14(3):129-135.
19. Barker AR, Rosson GD, Dellon AL. Pressure changes in the medial and lateral plantar and tarsal tunnels related to ankle position: a cadaver study. *Foot Ankle Int.* Feb 2007;28(2):250-254.
20. Recht MP, Grooff P, Ilaslan H, Recht HS, Sferra J, Donley BG. Selective atrophy of the abductor digiti quinti: an MRI study. *AJR Am J Roentgenol.* Sep 2007;189(3):W123-127.
21. Fuhrmann RA, Frober R. Release of the lateral plantar nerve in case of entrapment. *Oper Orthop Traumatol.* Jul 2010;22(3):335-343.
22. Narvaez JA, Narvaez J, Ortega R, Aguilera C, Sanchez A, Andia E. Painful heel: MR imaging findings. *Radiographics.* Mar-Apr 2000;20(2):333-352.
23. Guhl JF, Parisien JS. *Foot and ankle arthroscopy.* New York: Springer; 2004.
24. Spitz DJ, Newberg AH. Imaging of stress fractures in the athlete. *Radiol Clin North Am.* Mar 2002;40(2):313-331.
25. Ogden JA, Ganey TM, Hill JD, Jaakkola JI. Sever's injury: a stress fracture of the immature calcaneal metaphysis. *J Pediatr Orthop.* Sep-Oct 2004;24(5):488-492.

Gregory A. Sawyer MD, is a chief resident in the Department of Orthopaedic Surgery at the Warren Alpert Medical School of Brown University. He is planning to sub-specialize in sports medicine.

Craig R. Lareau MD, is a senior resident in the Department of Orthopaedic Surgery at the Warren Alpert Medical School of Brown University. He is planning to sub-specialize in foot and ankle.

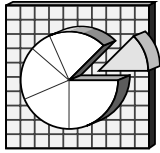
Jon A. Mukand, MD, PhD, is Medical Director, Southern New England Rehabilitation Center; Clinical Assistant Professor at The Warren Alpert Medical School of Brown University; and the author of The Man with the Bionic Brain and Other Victories over Paralysis.

Disclosure of Financial Interests

The authors and/or their spouses/significant others have no financial interests to disclose.

CORRESPONDENCE

Jon A. Mukand, MD, PhD
Southern New England Rehabilitation Center
200 High Service Avenue
North Providence, RI 02904
phone: (401) 456-3801
e-mail: jmukand@chartercare.org



Analysis of Blood Lead Screening Data (2008–2011) for Refugee Children in Rhode Island

Edwina Williams, Robert Vanderslice, PhD, and Carrie Bridges Feliz, MPH

MANY REFUGEE CHILDREN ARRIVE TO THE UNITED STATES WITH elevated blood lead levels (BLLs) compared to U.S. born children. Immigrant and refugee children are at high risk for lead poisoning due to previous lead exposure in their country of origin, malnutrition and iron deficiency. Upon arrival to Rhode Island most refugees are initially placed in housing units in the Providence area located near essential services at Rhode Island Hospital, the International Institute of RI, and the Diocese of Providence. However, housing units in these Providence neighborhoods are at high risk for lead hazards, thereby putting refugees at high risk for lead poisoning.

A study from New Hampshire published in 2004, found that of the 242 refugee children who were resettled in that state during October 1, 2003 – September 30, 2004, 92 received two blood lead level tests, one upon arriving to the United States and the second, 3–6 months after the initial screening. While most children had BLLs below ten micrograms per deciliter ($<10 \mu\text{g}/\text{dL}$) at the initial screening, 37 (40%) of the 92 children who had two screenings had BLLs $>10 \mu\text{g}/\text{dL}$ at the second screening, suggesting that the children experienced lead exposures in the US. Further investigation revealed environmental exposures to lead as well as a lack of awareness among refugee families on the sources and hazards of lead exposure.¹

Based on the results of the New Hampshire study and subsequent recommendations from the Centers for Disease Control and Prevention (CDC), the Rhode Island Department of Health (HEALTH) issued lead screening guidelines specific to the pediatric refugee population in 2006. The HEALTH guidelines require that refugee children up to the age of 16 years receive a health screening within 30 days of their arrival that includes a BLL test. Children whose initial lead screening results in a BLL $<10 \mu\text{g}/\text{dL}$ should have a repeat test 3–6 months later. Children with a BLL of $10 \mu\text{g}/\text{dL}$ or greater at any testing point are classified as having elevated BLLs. Children whose initial lead screening results in a BLL between $10 - 19 \mu\text{g}/\text{dL}$ should have a repeat test within three months (90 days) and receive lead education and/or non-medical case management by a lead center as recommended. Children who have an initial BLL test of $20 \mu\text{g}/\text{dL}$ or greater are considered “significantly lead poisoned” and should receive additional medical evaluation and treatment immediately.²

A previous analysis of blood lead screening data performed by Sunil Hebbbar found that between 2004 and 2008, refugees experienced more lead exposures compared to other Providence children. For this period, annual prevalence rates ranged from 14 to 40% for refugee children; prevalence rates for Providence for the same period ranged from four to nine percent.³

Since the initial analysis was performed, many changes have occurred which have impacted the lead exposures of the refugee

population. For example, the housing and foreclosure crisis has reduced the availability of safe and healthy housing; increased the cost to maintain rental units, and increased attention on the placement of newly arrived refugees.

This report provides an updated analysis of the prevalence of lead poisoning among refugee children in Rhode Island from 2008 to 2011, addresses concerns about lead-safe housing placements for refugee children, and offers a recommendation to lower the lead level of concern from $10 \mu\text{g}/\text{dL}$ to $5 \mu\text{g}/\text{dL}$.

METHODS

The HEALTH Lab analyzed blood lead screening samples for 257 refugee children from 2008 to 2011. To address the concerns of refugees being placed in housing units with lead hazards that are contributing to their exposure, screening histories were examined in detail for 20 of the 257 children for whom an increase in BLLs of at least $2 \mu\text{g}/\text{dL}$ was observed between two screening tests.

RESULTS

The following results were obtained for the 257 refugee children who had blood lead screenings from 2008 to 2011: Blood lead levels ranged from zero to $28 \mu\text{g}/\text{dL}$, with an average of all samples of $5 \mu\text{g}/\text{dL}$. 23 children (9%) had at least one sample at or above $10 \mu\text{g}/\text{dL}$; and 5 children (2%) had a sample of $15 \mu\text{g}/\text{dL}$ or greater.

Of the 23 refugee children whose BLLs were above $10 \mu\text{g}/\text{dL}$, 12% were children under the age of six years as compared to 3.4% of all Providence children under the age of six years who had elevated BLL during the same time period.⁴ Four of the 23 children experienced an increase in BLLs after their initial screening. Two children experienced this increase after moving from

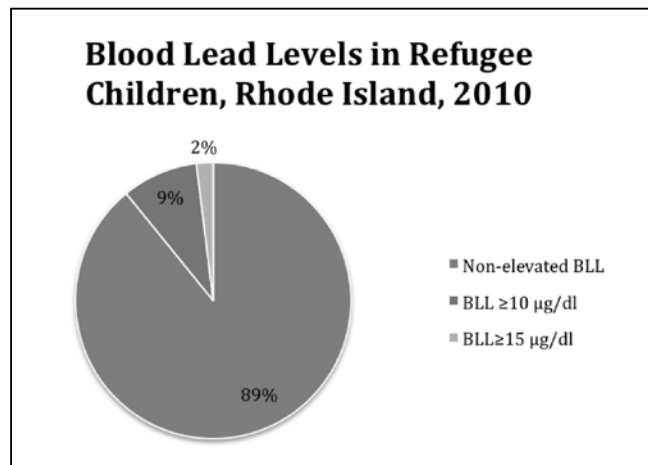


Figure 1.

Increase in Blood Lead Level in Refugee Children at Initial Placement, Rhode Island, 2010

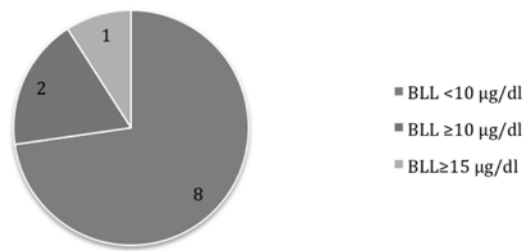


Figure 2.

their initial housing placement to a second location; whereas the remaining two children experienced BLL increases from nine to 12 µg/dL and four to 11 µg/dL, respectively, while remaining at their initial housing placement. The remaining 19 children with elevated BLLs of 10 µg/dL or greater did not experience an increase in their BLL after their initial screening.

After examining the screening histories for the 22 children who experienced a 2 µg/dL or more increase in BLLs between two screens, 11 of these children had relocated to a secondary housing placement since their initial screening test. The blood lead level increase was likely associated with exposures at the second address and not at the address of the initial placement. However, the remaining 11 children experienced an increase in their BLLs while remaining at their initial housing placement. Three children experienced a BLL increase above 10 µg/dL; one from 20 to 25 µg/dL, and the other two results were previously reported. The remaining eight children experienced an increase in BLLs but the results of the screening test remained below 10 µg/dL.

DISCUSSION

The 2008-2011 screening data do not provide evidence that current housing placements in Rhode Island are contributing to a widespread lead poisoning problem in the refugee community. Most refugee children arrive in the U.S. with blood lead levels below 10 µg/dL and maintain low blood lead levels during childhood. Children with initial screening results that were elevated all experienced declines in blood lead levels over time. For children who experienced an increase in blood lead levels while remaining at their initial housing placements, these increases may be due to the normal fluctuation and accuracy of the laboratory test. The lack of evidence of a widespread problem is not equivalent to an endorsement of the most recent housing placements, however. Most families with children were placed in housing without a Certificate of Conformance for lead. It is likely that placing families in housing with fewer hazards would result in lower blood lead levels than those observed to date.

The need to improve housing placements for refugees is demonstrated by the most recent recommendation of the CDC Advisory Committee on Childhood Lead Poisoning Prevention. The Committee recommended that the lead level of concern be lowered from 10 to 5 µg/dL. Notably, almost 40% of refugee

children (100 of 257 screened from 2008 to 2011) fall into the 5 to 9 µg/dL range of concern.

Addressing the health of housing for refugee children will require the following:

- Quarterly notification by refugee resettlement agencies to HEALTH of housing placements for recently resettled refugees.
- A commitment to placing refugees in safe housing, which includes ensuring that no family with children under the age of six is placed in a unit with lead hazards, as determined by: a valid certificate of conformance or lead safe certificate for the housing placement; placement in a unit built after 1978; or visual confirmation by the resettlement agency that the paint is intact, that the soil adjacent to the house is covered, that the landlord has been informed of the requirements to comply with the lead standards, and that a dust sample test result has been obtained that is within standards for obtaining a Certificate of Conformance.
- Maintaining open and transparent communication between refugee resettlement agencies, the R.I. Department of Health, the State Coordinator for Refugee Resettlement, and the U.S. Department of State, which contracts directly with resettlement agencies for reception and placement.

REFERENCES

1. Kellenberg J, DePentima R, et al. Elevated blood lead levels in refugee children— New Hampshire, 2003-2004. *MMWR*. 2005;54:42-6.
2. Rhode Island Department of Health Lead Screening and Referral Guidelines for Refugees. Childhood Lead Poisoning Prevention Program. Rhode Island Department of Health. January 2006. <http://www.health.ri.gov/publications/brochures/provider/LeadScreeningAndReferralGuidelinesForRefugees.pdf>.
3. Hebbbar S, Vanderslice R, Simon PR, Vallejo ML. Blood Levels in Refugee Children in Rhode Island. *MH/RI*. 2010;93:254-5
4. Childhood Lead Poisoning Prevention Program. Providence, RI: Rhode Island Department of Health.

Edwina Williams is a Masters student at the Warren Alpert Medical School, Program in Public Health, Brown University.

Robert Vanderslice, PhD, is the Team Lead for Healthy Homes and Environment, Division of Community Family Health and Equity, Rhode Island Department of Health.

Carrie Bridges Feliz, MPH, is the Team Lead for Health Disparities and Access to Care, Division of Community, Family Health and Equity, Rhode Island Department of Health.

Disclosure of Financial Interests

The authors and/or their spouses/significant others have no financial interests to disclose.

CORRESPONDENCE

Edwina Williams
Brown University
Box G-S121, 2nd Flr.
Providence, RI 02912
e-mail: edwina_williams@brown.edu



Physician's Lexicon

A Lexical Bridge of Psighs

THE ENGLISH LANGUAGE, AS THE GRATEFUL recipient of a flood of words from older languages – its heterogenous rhetorical ancestry – has, of necessity, been obliged to accept certain sounds which seem to be, at first hearing, alien to it. Consider, for example, the numerous Greek words that begin with the letter *psi*- (the 23rd in the Greek alphabet), generating sounds for which there is no single equivalent in the English alphabet.

The Greek verb, *psallein*, defining the act of plucking, gave rise to the noun *psalmos*, meaning a song accompanied by the plucking of a harp. The verb also generated the English word, psaltery as well as psalm and psalmody. The anatomic term, psalterium (the third stomach of ruminants) was so named because of its mucosal surface's alleged resemblance to the pages of a book of psalms.

The Greek root, *psammo*- means sand and has given rise to medical terms such as psammoma (an archaic word for meningioma) and its adjective, psammomatous.

The Greek root, *pseudo*-, meaning false or erroneous, is incorporated into scores of medical words including pseudobulbar, pseudarthrosis, pseudocyst, pseudopod and pseudopregnancy; as well as non-medical terms such as pseudonym, pseudograph and pseudocarp (false fruit).

Psittakos, the Greek noun for the parrot, has entered the medical domain as the disease, psittacosis (parrot fever caused by *Chlamydia psittaci*.)

The Greek root, *psilo*-, meaning naked, deprived of hair or made smooth, generates such obscure medical terms as psilosis (baldness) and its adjective, psilotic.


The Greek, *psora*, meaning an itch produces medical terms such as psoriasis,

psoriatic and Psoralea (a genus of plants in the pea family.)

Psyche was a maiden, in Greek mythology, much beloved by Eros; and as such she was personified in legend as the symbol of the uncontaminated soul. Scores of varied medical terms have since arisen from the pagan image of Psyche thus causing its underlying meaning to broaden, embracing such concepts as the mind, spirit, breath, even the soul. An avalanche of words have since arisen, derived from Psyche, including psychiatry, psychodelic, psychometrics and psychotherapy.

A psychrometer, an instrument to measure atmospheric moisture, however, is derived from the Greek, *psychros*, meaning cold, which in turn is related etymologically to the Greek, *cryos*, also meaning cold (as in cryogenics).

– STANLEY M. ARONSON, MD



RHODE ISLAND DEPARTMENT OF HEALTH
MICHAEL FINE, MD
DIRECTOR OF HEALTH

VITAL STATISTICS

EDITED BY COLLEEN FONTANA, STATE REGISTRAR

Rhode Island Monthly Vital Statistics Report Provisional Occurrence Data from the Division of Vital Records

Underlying Cause of Death	Reporting Period			
	April 2011	12 Months Ending with April 2011		
	Number (a)	Number (a)	Rates (b)	YPLL (c)
Diseases of the Heart	187	2,357	223.8	3,487.0
Malignant Neoplasms	177	2,301	218.5	5,846.5
Cerebrovascular Diseases	39	445	42.3	754.5
Injuries (Accidents/Suicide/Homicide)	54	634	60.2	9,648.0
COPD	42	547	51.9	422.5

Vital Events	Reporting Period		
	October 2011	12 Months Ending with October 2011	
	Number	Number	Rates
Live Births	965	11,792	11.2*
Deaths	757	9,883	9.4*
Infant Deaths	(8)	(78)	6.6#
Neonatal Deaths	(5)	(65)	5.5#
Marriages	696	6,160	5.8*
Divorces	308	3,324	3.2*
Induced Terminations	326	4,078	345.8#
Spontaneous Fetal Deaths	46	685	58.1#
Under 20 weeks gestation	(37)	(593)	60.0#
20+ weeks gestation	(9)	(90)	7.6#

(a) Cause of death statistics were derived from the underlying cause of death reported by physicians on death certificates.


(b) Rates per 100,000 estimated population of 1,053,209. (www.census.gov)

(c) Years of Potential Life Lost (YPLL).

Note: Totals represent vital events that occurred in Rhode Island for the reporting periods listed above. Monthly provisional totals should be analyzed with caution because the numbers may be small and subject to seasonal variation.

* Rates per 1,000 estimated population

Rates per 1,000 live births



NINETY YEARS AGO, APRIL, 1922

Herman C. Bumpus, MD, of the Mayo Clinic presents an article on the relation of focal infection to diseases of the urinary tract. He identifies the presence of oral sepsis in a large percentage of patients with urinary tract infections and suggests the possibility that such sepsis might be the focus from which the urinary infection originated. However, the presence of colon bacillus in most chronic urinary infections and the absence in cultures from tonsils or abscessed teeth makes it difficult to explain the relationship. He mentions that the proximity of the colon to the kidneys and the apparently direct lymphatic connection suggests urinary infections originate in the colon rather than in the mouth.

An editorial criticizes the use of mail-delivered advertisements—particularly ones which contain phrases such as “Just a moment of your valuable time...” or “Read this and save money.” The author derides the glut of advertising and the ever-increasing volume taking up the physician’s valuable time. “How much can a doctor read?” The editorial suggests that advertisers instead consider making use of local medical journals to ply their trade.

An “Associate-at-Large”, known as F. T. R., writes his colleagues in Rhode Island from the deck of the *S.S. Adriatic*. The piece replete with colorful descriptions of various sights and peoples from his travels. On January 24, he writes: “‘See Naples and die,’ someone said, and I don’t wonder at it. It is the dirtiest city of a progressive race that I ever saw—some of the Chinese cities would put it to shame. Never again will I eat Neapolitan spaghetti. I have seen it made and I am not fussy, either.”

A short piece discusses the state of scarlet fever, noting specific statistics for reported cases in the United States and its mortality rates. He also notes of more mild strains being reported despite popular thought that more severe cases were more infectious.

FIFTY YEARS AGO, APRIL, 1962

Arseno C. Pascual, MD, John R. Stuart, MD, and Waldo O. Hoey, MD, present a piece discussing pneumatosis intestinalis—commonly known as gas cysts of the intestines, but also called pneumatosis cystoides intestinalis, pneumatosis coli and emphysema of the intestines. They discuss the original theories of neoplastic and bacterial etiologies, as well as later chemical theories and pH levels of the intestinal wall. The mechanical theory, at the time of writing, becomes the generally accepted most plausible etiology in which intestinal gas penetrates the gastrointestinal mucosa through a defect, either large or small, then dissects submucosally, subserosally, or into the mesentery.

In a piece entitled “Jungle Hospital,” Meyer Saklad, MD, writes a vivid piece on his visit to a 28-bed hospital located in the Andes mountains of Peru which serves the local tribespeople.

He describes the small staff of four, its facilities, routines, and patient population. There are numerous obstacles to overcome including trust issues, hygiene, cultural differences, nutrition, equipment, medical supplies, and difficulty of terrain. Dr. Meyer gives high praise to the staff and mission of the hospital and is thankful for the opportunity he has been provided in spreading the word regarding such.

A report is given on the Medical Education Loan Guarantee Program of the American Medical Association. Medical students, interns and residents have a new financial support available to them. A loan plan which has been under consideration within the American Medical Association for a number of months has now been accepted by the Board of Directors of the American Medical Association Education and Research Foundation as one of the programs of the Foundation. The loan plan will assist students who need financial help at any stage of their medical education—including first-year medical students.

TWENTY-FIVE YEARS AGO, APRIL, 1987

In an editorial, Seebert J. Goldowsky, MD, writes more on the subject of tobacco noting recent developments in the war on smoking. Berkeley, California and Cambridge, Massachusetts, both university towns, have adopted highly restrictive ordinances limiting smoking in public places. Similar legislation had just become effective in New York state. While much remains to be done on both the local and national scenes, the current trend in smoking restriction appears to be moving in the right direction.

Virginia Attanasio, PhD, Joanne L. Fowler, PhD, Michael J. Follick, PhD, and Richard J. Perry, MD, discuss issues in the management of recurrent headaches—particularly non-pharmacological treatments. After reviewing classifications and medical treatments, the authors focus on non-pharmacological intervention strategies such as relaxation training, biofeedback, and cognitive coping skills.

Francis B. Sargent, MD, examines the beginnings of the “Malpractice Crisis in Rhode Island” beginning with an event in 1953 in which an otologist was sued by a patient, and in which another otologist testified for the plaintiff who was then awarded \$25,000. Following this was a shake up in the insurance community over matters of malpractice policies. A similar situation occurred a few years later. Insurance companies offered group plans, but retained the right to cancel individual doctors within the group. As premiums rose over the next decade, medical societies and physicians balked at some of the policy arrangements being offered by certain insurance companies and cancelled.

Rhode Island Medical Society Bicentennial Observances in 2012



Bicentennial Gala at Newport's Rosecliff Mansion, Saturday evening, April 21, 2012

A festive black tie (optional) evening of dinner and dancing will commemorate the Rhode Island Medical Society's founding, which took place at the Old State House in Providence on April 22, 1812.

Dr. Amos Throop portrait, ca. 1795, by Ralph Earl

Having spent most of 2011 at the Williamstown Art Conservation Institute, RIMS' luminous portrait of its first president, Dr. Amos Throop (1736-1814), by the noted American portraitist Ralph Earl, (who painted leading figures on both sides of the Atlantic, including King George III), is now in optimal condition for its return to Providence and its first public display.

Publication of *Medical Odysseys*

Join us on December 15, 2011 at the Hay Library to meet the authors and get your copy of RIMS' recently published collection of historical essays and commentaries by Dr. Stanley Aronson, Dr. Joseph Friedman, and editor Mary Korr. Contributions benefit RIMS' Bicentennial Observances.

Public Symposium on Neurobiology and Society

In the fall of 2012, in cooperation with the Brown Institute for Brain Sciences and the Warren Alpert School of Medicine at Brown University, the Medical Society will co-sponsor a series of public lectures on the broad ramifications of recent advances in neuroscience.

Inaugural presentation of the RIMS Dr. Amos Throop Prize, May 26, 2012

The Medical Society will endow a new prize to be presented annually to graduating seniors at the Warren Alpert School of Medicine at Brown University who have demonstrated interest, aptitude and engagement in public policy relating to health care and in the role of organized medicine in advocating for patients. The prize will be named for the Society's first president, Dr. Amos Throop, a Revolutionary War veteran and a Federalist who served three terms in the General Assembly.

Naval War College Museum: New England Lobster Bake

The NORCAL Mutual Insurance Company plans to host a summer outing for Rhode Island Medical Society members on the scenic grounds of the War College Museum on Coaster's Harbor Island in Newport.

Exhibit of 16th and 17th century medical books and instruments from the RIMS collection at Hay Library

The Rhode Island Medical Society donated its fifty-five thousand volume collection of books and antique medical instruments to Brown University in 1987. A commemorative exhibit is planned in 2012.

New History of RIMS

A new history of the Rhode Island Medical Society is under the pen of the current executive director of the Society. The last comprehensive history of RIMS was published in 1966.

NUMBERS THAT WORK **AS HARD AS YOU DO**

22,800 CALLERS ASSISTED IN 2011	1 PHONE CALL IS ALL IT TAKES		CREDENTIALING LETTERS ISSUED	25,000
	24/7 PHONE ACCESS TO LIVE EXPERTS			

What is great service? For NORCAL Mutual insureds, just 1 phone call is all it takes for great service. That means calling during business hours and immediately reaching a live, knowledgeable, friendly expert. After hours, it means promptly receiving a call back from a professional qualified to help with your issue. No automated telephone tango. Questions are answered and issues resolved — quickly. We're on call 24 hours a day, every day of the year. Great service brings you peace of mind. To purchase your NORCAL Mutual coverage call RIMS Insurance Brokerage at 401-272-1050. **Great service 24/7. Hard-working numbers you can count on.**



CALL 1-800-652-1051 OR VISIT NORCALMUTUAL.COM

Proud to be endorsed by the Rhode Island Medical Society.



*Our passion protects
your practice*