Marilyn Barry Brooks, MD, is a Diagnostic Radiology Resident at the Warren Alpert Medical School of Brown University.

Don C. Yoo, MD, is Assistant Professor of Diagnostic Imaging (Clinical) at the Warren Alpert Medical School of Brown University.

Michael Chaump, MD, is a Pathology Resident, The Warren Alpert Medical School of Brown University.

Richard B. Noto, MD, is Associate Professor of Diagnostic Imaging (Clinical), The Warren Alpert Medical School of Brown University.

Disclosure of Financial Interests

The authors and/or significant others have no financial interests to disclose.

Correspondence

Marilyn Barry-Brooks, MD
Department of Diagnostic Imaging
Rhode Island Hospital
593 Eddy Street
Providence, RI 02903
e-mail: mbarry@lifespan.org

Recurrence of Lung Cancer After Radiofrequency Ablation Detected by PET/CT and Contrast Enhanced CT Scan

Albert A. Scappaticci, MD, PhD, and Don C. Yoo, MD

82-year-old female with a history of cough for three months had a CT of the chest which revealed a 1.5 cm right upper lobe pulmonary nodule. (Figure 1) The patient underwent a CT guided percutaneous biopsy which on histology was consistent with adenocarcinoma of the lung. The patient then underwent a **positron emission tomography/computed tomography** (**PET/CT**) scan (Figure 2) with **18F-fluorodeoxyglucose** (**F-18 FDG**) for staging which showed intense uptake in the right upper lobe adenocarcinoma without evidence of metastatic disease. The patient was not a surgical candidate due to poor pulmonary reserve and subsequently underwent percutaneous **radiofrequency ablation** (**RFA**) of the right upper lobe adenocarcinoma. After RFA, a follow-up PET/CT (Figure 3) six months later showed curvilinear activity around the ablation site with slightly more intense activity anteriorly. A contrast-enhanced CT scan (Figure 4) showed focal enhancement in the anterior aspect of the ablation cavity corresponding to the area of more focal intense activity seen on the follow-up PET/CT. Percutaneous CT guided biopsy of this region confirmed suspicion of residual or recurrent adenocarcinoma. The patient was retreated with RFA. (Figure 5) Repeat CT scan (Figure 6) performed at four months after reablation showed no evidence of residual tumor (not shown).

Figure 1. Noncontrast CT image show a spiculated 1.5 cm lung nodule in the right upper lobe (arrow).

Discussion

Radiofrequency ablation of lung cancer is an important treatment option for patients who are medically inoperable with proven safety and efficacy. RF abla-



Figure 2. Preablation Axial CT (A), PET (B), and fused PET/CT (C) images show intense uptake in the right upper lobe nodule (arrows) which was histologically proven to represent an adenocarcinoma.



Figure 3. Axial CT (A), PET (B), and fused PET/CT (C) performed 6 months after RFA images show curvilinear activity around the ablation site with slightly more intense activity anteriorly (arrows).

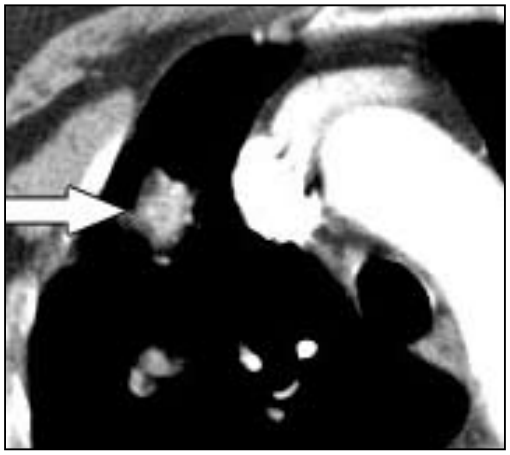

Figure 4. Contrast enhanced CT image performed 3 months after the postablation PET/CT scan shows focal enhancement in the anterior aspect of the ablation cavity (arrow) corresponding to the area of more focal intense activity seen on the prior PET/CT. This area on biopsy showed recurrence of adenocarcinoma.

Figure 5. Noncontrast CT image shows a radiofrequency probe within the area of recurrence of adenocarcinoma.

tion of stage I **non-small cell lung cancer (NSCLC)** has a 78% one year survival and 27% five year survival as compared with 50% one year survival in patients undergoing observation alone.[1] Currently contrast enhanced CT imaging and more recently PET imaging with F18-FDG have been used to evaluate treatment success. With the increase in patients undergoing thermal ablation, appropriate imaging follow-up is needed in order to evaluate treatment response since early detection of residual tumor and recurrence can stratify patients into groups who may benefit from reablation or other therapy

PET/CT using F18-FDG is a molecular imaging modality that utilizes the radioisotope 18F coupled to glucose. When administered intravenously the radioisotope is transported into all cells of the body which actively use glucose. Cancer cells are typically more metabolically active than the native cells of the body and molecular imaging takes advantage of this differential.

PET-CT has become an invaluable modality in assessing for recurrence of patients treated with image guided percutaneous ablation of lung cancer. Recent articles demonstrate the important role of PET in following this patient population. In a recent retrospective five-year study which followed 68 patients with 94 pulmonary lesions, including metastases and primary lung cancers, researchers reviewed 18F-FDG PET/CT scans performed before and after RFA and were able to determine several indicators that could help predict local recurrence. Among pre-RFA scans, lesion size and type of tumor (primary or metastases) were factors in determining potential for local recurrence. In this study pulmonary metastases recurred less often than treated primary lung cancers and tumors smaller than three cm responded better to RFA. PET/CT scans conducted after RFA showed a variety of different uptake patterns in the ablation sites. Discretely increased focal activity along the periphery of the ablation cavity especially if this focus corresponded to the location of the original tumor was considered an unfavorable appearance and suspicious for recurrence.[2]

The optimal timing of obtaining the initial PET/CT after ablation is still being determined. In a recent prospective study of 34 lung lesions (five lesions representing primary lung cancer, 29 lesions representing metastases) follow-up post-ablation PET/CT scans were performed at one day, one month and three months after RFA. The authors concluded that PET/CT at three months after RFA may be a good time for the initial study to limit the false positive results from inflammatory uptake which occurred more frequently on the PET/CT scans performed at one day and one month after RFA.[3] More research will be necessary to determine the optimal imaging time of the initial PET/CT scan after RFA and the optimal image times for additional surveillance PET/CT scans.

CT scans performed prior to and after administration of IV contrast are also important for follow-up of patients after RFA. More recently CT densitometry evaluation for focal enhancement at the ablation site at multiple timepoints have been used for to improve the accuracy on CT for detecting recurrence.[4]

The findings in this case show the complementary role of PET/CT and contrast enhanced CT scans in the detection of cancer recurrence post treatment. The initial follow-up PET/CT scan in this patient demonstrated periphery activity with more intense uptake anteriorly which on a follow-up CT scan showed focal enhancement highly suspicious for recurrent disease which resulted in reablation of the area of recurrence. Follow-up of lung cancers after RFA with PET/CT scans and contrast enhanced CT scans can increase the accuracy of early recurrence detection allowing for reablation or other treatment leading to improved patient outcomes.

References

1. Simon CJ, Dupuy DE, DiPetrillo TA, et al. Pulmonary radiofrequency ablation: longterm safety and efficacy in 153 patients. *Radiology*. 2007;243(1):268–75.
2. Singnurkar A, Solomon SB, Gönen M, et al. 18F-FDG PET/CT for the prediction and detection of local recurrence after radiofrequency ablation of malignant lung lesions. *J Nucl Med*. 2010;51:1833-40.
3. Deandreis D, Leboulleux S, Dromain C, et al. Role of FDG PET/CT and chest CT in the follow-up of lung lesions treated with radiofrequency ablation. *Radiology*. 2011;258:270–6.
4. Suh RD. Unresectable pulmonary malignancies: CT-guided percutaneous radiofrequency ablation—preliminary results. *Radiology*. 2003;229(3):821–9.

Albert A. Scappaticci, MD,PhD is a Diagnostic Radiology Resident, The Warren Alpert Medical School of Brown University.

Don C. Yoo, MD, is Assistant Professor of Diagnostic Imaging (Clinical), The Warren Alpert Medical School of Brown University.

Disclosure of Financial Interests

The authors and/or significant others have no financial interests to disclose.

Correspondence

Albert A. Scappaticci, MD, PhD
Department of Diagnostic Imaging
Rhode Island Hospital
593 Eddy Street
Providence, RI 02903
e-mail: ascappaticci@lifespan.org