Parotid Gland Pleomorphic Adenoma with Floret-Like Tyrosine-Rich Crystals

RALPH N. SAMS, MD; SHAMLAL MANGRAY, MBBS

A 53-year-old man had fine needle biopsy of a left parotid mass showing "cellular components with mucoid material consistent with pleomorphic adenoma." The gland was removed, revealing a 2.9 x 2.4 x 2.0 cm well circumscribed tan-grey opaque mass with a myxoid appearance on cut surface (Figure 1). The frozen section slides demonstrated mixed epithelial and myxoid areas. The extensive myxoid stroma contained characteristic red to pink crystalloid deposits arranged in floret-like patterns (Figure 2). The intraoperative consult diagnosis was "myxoid lesion suggestive of mixed tumor on representative section."

Figure 1

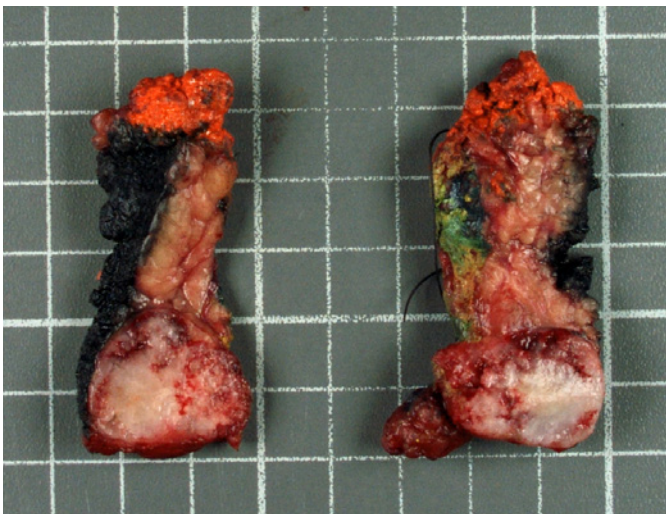

Pleomorphic adenomas, also known as benign mixed tumors, are the most common tumors of the parotid gland. They have variable morphologic features with matrices that can be cartilaginous or myxoid. The characteristic floret-like crystals present in the parotid are an uncommon finding and are more often present in pleomorphic adenomas (benign mixed tumor) than any other tumor of the parotid gland, and are generally found in the myxoid areas. They are reported to have a frequency of 1.5-21% but we have found them to be much more infrequent.

The crystalloids seen in this case are tyrosine-rich crystalloids. They are refractile with light microscopy and some may contain a dominant component of arginine rather than tyrosine. They are thought to result from the precipitation on stromal collagen of products secreted by neoplastic myoepithelial cells. Two other types of crystals have been described in pleomorphic adenomas. The most common are eosinophilic, needle-shaped crystals that may diminish when tissue undergoes routine processing and fixation. The third type resembles calcium oxalate crystals.

Figure 2

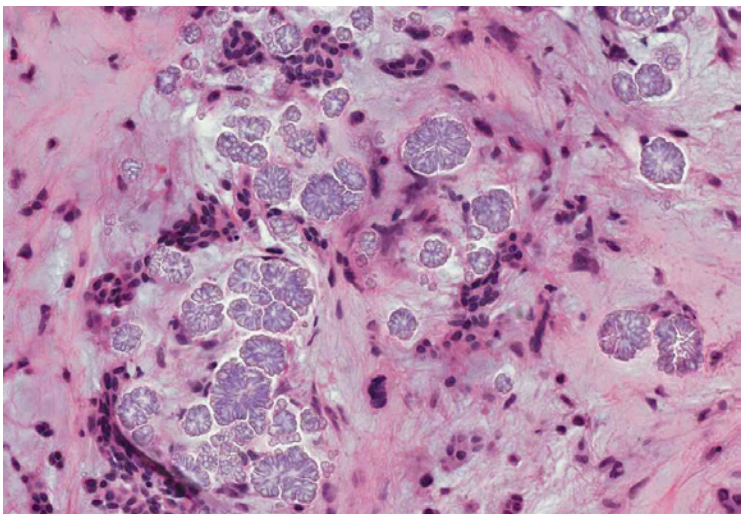

References

1. Ellis GL, Auclair PL. *Tumors of the Salivary Glands, AFIP Atlas of Tumor Pathology.* Washington, DC: American Registry of Pathology; 2008.

Authors' Affiliation

Department of Pathology
Rhode Island Hospital/ The Warren Alpert Medical School of Brown University

Disclosures

The authors have no relevant financial disclosures.

Correspondence

Ralph N. Sams, MD
Department of Pathology
593 Eddy Street, APC-12
Providence RI 02903