Essentials of Anterior Cruciate Ligament Rupture Management

STEPHEN A. KLINGE, MD; GREGORY A. SAWYER, MD; MICHAEL J. HULSTYN, MD

ABSTRACT

Anterior cruciate ligament (ACL) rupture is a common knee injury and an understanding of current medical knowledge regarding its management is essential. Accurate and prompt diagnosis requires an awareness of injury mechanisms and risk factors, common symptoms and physical/radiologic findings. Early mobilization and physical therapy improves outcomes regardless of treatment modality. Many older patients regain sufficient stability and function after non-operative rehabilitation. Early ACL reconstruction is appropriate for younger patients and those who engage in activities requiring frequent pivoting and rapid direction changes. ACL surgery involves reconstruction of the torn ligament tissue with various replacement graft options, each with advantages and disadvantages. The guidance of a knowledgeable and experienced therapist is required throughout an intensive and prolonged rehabilitation course. Generally excellent outcomes and low complication rates are expected, but treatment does not prevent late osteoarthritis.

KEYWORDS: Anterior Cruciate, Rupture, Non-Operative, Reconstruction, Rehabilitation

I. BACKGROUND

Acute rupture of the anterior cruciate ligament (ACL) is a common cause of knee instability, necessitating over 120,000 ACL reconstructions in the United States annually.[1] An understanding of current diagnostic, treatment and rehabilitation principles is essential in order to care for patients with ACL injuries.

Over two-thirds of ACL tears occur through non-contact mechanisms, including jump landings and knee hyperextension; direct contact from sports and trauma make up the remaining third.[1] Anatomic risk factors for non-contact injury include increased valgus alignment of the lower extremities (knock knees) and characteristic differences in the shape of the distal femur and proximal tibia (e.g. decreased femoral intercondylar notch width). Neuromuscular risk factors include an upright posture (reduced hip/knee flexion) and imbalanced quadriceps – hamstring muscle activation with jump landing activities. A number of these risk factors are present in females, who are significantly more likely to suffer an ACL injury compared with males.[2]

II. INITIAL EVALUATION AND MANAGEMENT

Patients with an acute ACL rupture state that the knee shifted or gave way during decelerating or changing direction while running. When associated with an audible "pop," severe pain and immediate swelling (hemarthrosis), the likelihood of ACL tear is 70%.[3] Other possible diagnoses for an acute hemarthrosis include patella dislocations/fractures or other osteochondral fractures; effusions associated with isolated meniscal injury typically present more slowly.[3] When patients begin to ambulate normally, complaints of instability are common, particularly with pivoting. Mechanical symptoms (i.e. clicking and locking) raise suspicion for concomitant meniscal damage.[4]

During the physical examination, patients should be relaxed in order to prevent quadriceps and muscular guarding. Comparison with the contralateral extremity and a careful neurovascular examination are also crucial for any patient with possible ligamentous knee injury. The ACL is the primary restraint to anterior tibial translation, so its disruption allows abnormal anterior movement of the tibia relative to the femur. The Lachman is the most sensitive test for an ACL tear; with the distal femur stabilized and the knee in 20-30 degrees of flexion, the tibia is pulled anteriorly. Increased laxity compared to the uninjured side and the lack of an end-point indicates a positive test. The anterior drawer test also assesses tibial translation and an end-point, but at 90 degrees of knee flexion.[4] The pivot shift test is the most specific for ACL rupture, but can be limited by patient guarding. The knee is stressed with valgus and internal rotation forces while simultaneously being ranged from full extension into flexion. With ACL rupture, the anteriorly subluxated tibia will reduce or "pivot shift" back into place as the knee is flexed.[4] Concomitant collateral ligament injury is evaluated by applying varus/valgus stress at 30 degrees of knee flexion; while posterior cruciate ligament injury is assessed with a posterior drawer maneuver.[4]

Initial imaging includes standard anterior-posterior and lateral plain films. The Segond fracture, a tibial avulsion fracture fragment associated with anterolateral capsule sprain, is pathognomonic for an ACL tear. Tibial spine fractures resulting from ACL avulsion, though rare, are more commonly found in younger patients.[5] Other possible diagnoses on knee radiographs include subtle findings of patella dislocation and tibial plateau fractures. Magnetic resonance imaging (MRI) demonstrates discontinuity, lack of

visualization, or an abnormal slope of the ACL.[6] Secondary MRI signs include hemarthrosis, Segond fracture, bone bruising (posterolateral tibia plateau and mid-portion of the lateral femoral condyle), anterior translation of the tibia on the femur, and impaction of the lateral femoral condyle. MRI also aids in the diagnosis of concomitant ligamentous, osteochondral and meniscal injuries (present in 40%-70%).[5]

Initial treatment should focus on decreasing pain, swelling and stiffness. Ice, elevation, compressive wraps and anti-inflammatory medications are recommended.[7] Bracing in a knee immobilizer and crutches should be avoided beyond a few days and physical therapy should be instituted immediately, even if the knee is painful and swollen. Rehabilitation should encourage range of motion, weight-bearing as tolerated, and progressive isometric strengthening as motion improves. Early rehabilitation enhances the likelihood of success with either operative or non-operative management.[7] To prevent further joint injury, the patient should avoid high-risk pivoting activities or a return to sports prior to full evaluation and treatment.

III. NON-OPERATIVE TREATMENT AND REHABILITATION

Several studies have classified patient demands and activity levels in an attempt to identify the best candidates for non-operative management ("copers" or "non-copers"). Non-operative treatment is reasonable for patients who can modify their activities and who require less pivoting or quick changes of direction in sports and work.[7] In one study, 72% of potential "copers" successfully returned to pre-injury activity levels after non-operative treatment without further instability and 43% ultimately avoided ACL reconstruction.[8] A willingness to attempt non-operative management despite initial concerns regarding knee instability can increase non-operative treatment success, as 60% of potential "copers" and 70% of potential "non-copers" became "true copers" at one year.[9]

Both patient age and willingness to modulate activity are important factors. Over 80% of patients 40-60 years of age at the time of injury had satisfactory outcomes with rehabilitation and activity adaptations; furthermore, they had mild to no radiographic progression of osteoarthritis after an average of seven years. Only a minority (17%) were dissatisfied with their ultimate functional level.[10]

ACL-injured patients who function well with non-operative management can regain dynamic knee stability and return to pre-injury activity levels without ACL support through neuromuscular and proprioceptive re-training.[8] Common non-operative ACL rehabilitation programs are graduated, initially focusing on progressive strengthening of the quadriceps/hamstring muscle groups and endurance training. Ultimately, increased general agility and sports-specific training is added. The addition of perturbation training, in which subjects learn to compensate for multi-directional movement changes, may further enhance the likelihood of return to baseline activity.[11]

The use of off-the-shelf and custom-fitted ACL braces, though controversial, is encouraged. These braces stabilize the knee by resisting abnormal tibial subluxation and may also improve knee proprioception.[12]

IV. OPERATIVE TREATMENT AND GRAFT SELECTION

Despite rehabilitation after ACL rupture, many patients continue to experience knee instability with activities of daily living, sports or work. Operative management is recommended to restore knee stability and return these patients to their previous level of function.[7] Current surgical intervention involves arthroscopic reconstruction using either autograft or allograft tendon tissue to replace the torn ACL.[13] Primary ligament repair historically has poor outcomes,[14] but is currently being revisited using growth hormones and cytokines to help modulate healing.[15]

Patients make the decision on graft choice after they research options and discuss alternatives with their surgeon [Figure 1]. Three commonly used graft options include bone-patellar tendon-bone (BTB), quadrupled hamstring, and allografts:

Figure 1. Graft Options for Anterior Cruciate Ligament Reconstruction

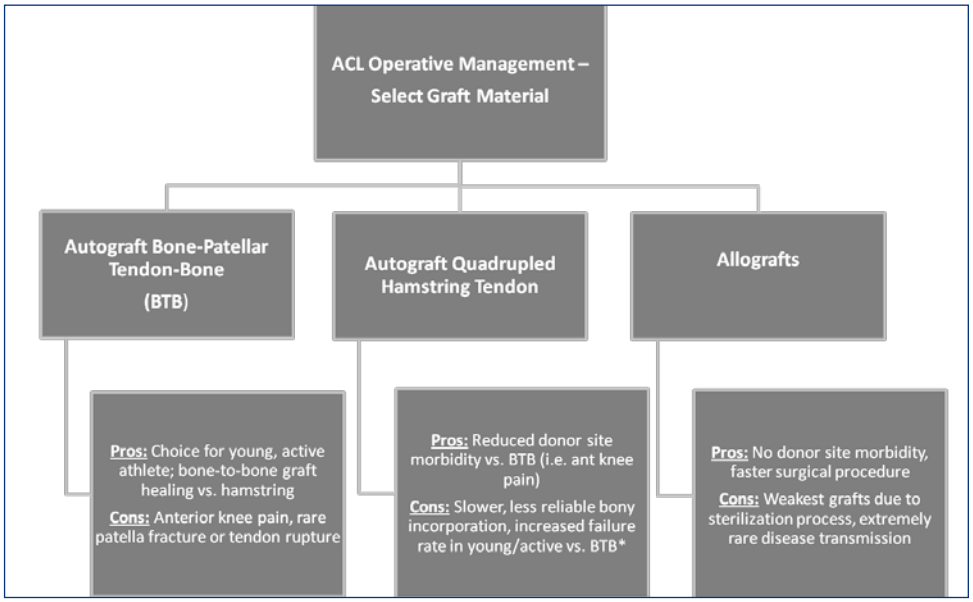

Legend: *Barrett, *Am J Sports Med*, 2011[17]

BTB Autograft

Often considered the gold standard in ACL reconstruction, BTB autograft requires harvest of the central third of the patellar tendon with attached bone blocks from both the patella and tibial tubercle. Advantages include bone-to- bone healing, ease of harvesting, and good clinical outcomes.[16] Disadvantages include anterior knee pain as well as a low risk of patella fracture and patellar tendon rupture.[16-17] BTB is the graft of choice for more active individuals under 25 years who participate in high-risk pivoting sports. BTB failure rates are less than when hamstring autograft is utilized.[17]

Quadrupled Hamstring Autograft

The semitendinosus and gracilis tendons are harvested from their pes anserine attachment and then folded to form a quadrupled construct. This graft has decreased donor site morbidity and greater initial biomechanical strength, which are key advantages compared to BTB. The main disadvantage for the hamstring graft is less reliable healing, because it relies on bone growth into tendinous soft tissue as opposed to bone-to-bone healing.[16]

Allografts

Allograft options include cadaveric patellar, quadriceps, hamstring, and Achilles tendons. These grafts eliminate donor site harvest morbidity and have good clinical results in lower demand and revision surgery patients. Despite concerns, they have extremely low infectious disease transmission rates due to processing and disease testing.[16] Allograft reconstructions have increased failure rates in more active individuals due to graft weakening from sterilization processes.[16]

V. OPERATIVE REHABILITATION

Teaming with an experienced physical therapist to guide patients through post-operative rehabilitation is essential for successful outcomes. Rehabilitation after ACL reconstruction should begin within days after surgery [Figure 2]. Key goals are restoration of joint range of motion and strength while protecting the integrity of the surgical graft.[18] Patients are placed in a knee immobilizer and encouraged to begin partial or full weight-bearing with crutches. Range-of-motion exercises begin immediately, with the goal of full extension and flexion to 90 degrees within two weeks. Adjunctive exercises include isometric quadriceps strengthening and patella mobilization.[18] Bracing and crutches are discontinued when there is enough quadriceps strength to allow a straight leg raise without lag. At 10-14 days, the surgeon evaluates wound healing, removes sutures and ensures that initial therapy goals are being met.

During weeks two through six after surgery, therapy should achieve full range of motion, equivalent to the contralateral extremity, through passive and active exercises. Strengthening is gradually advanced after improving range

Figure 2. Anterior Cruciate Ligament Operative Rehabilitation Time-Line1

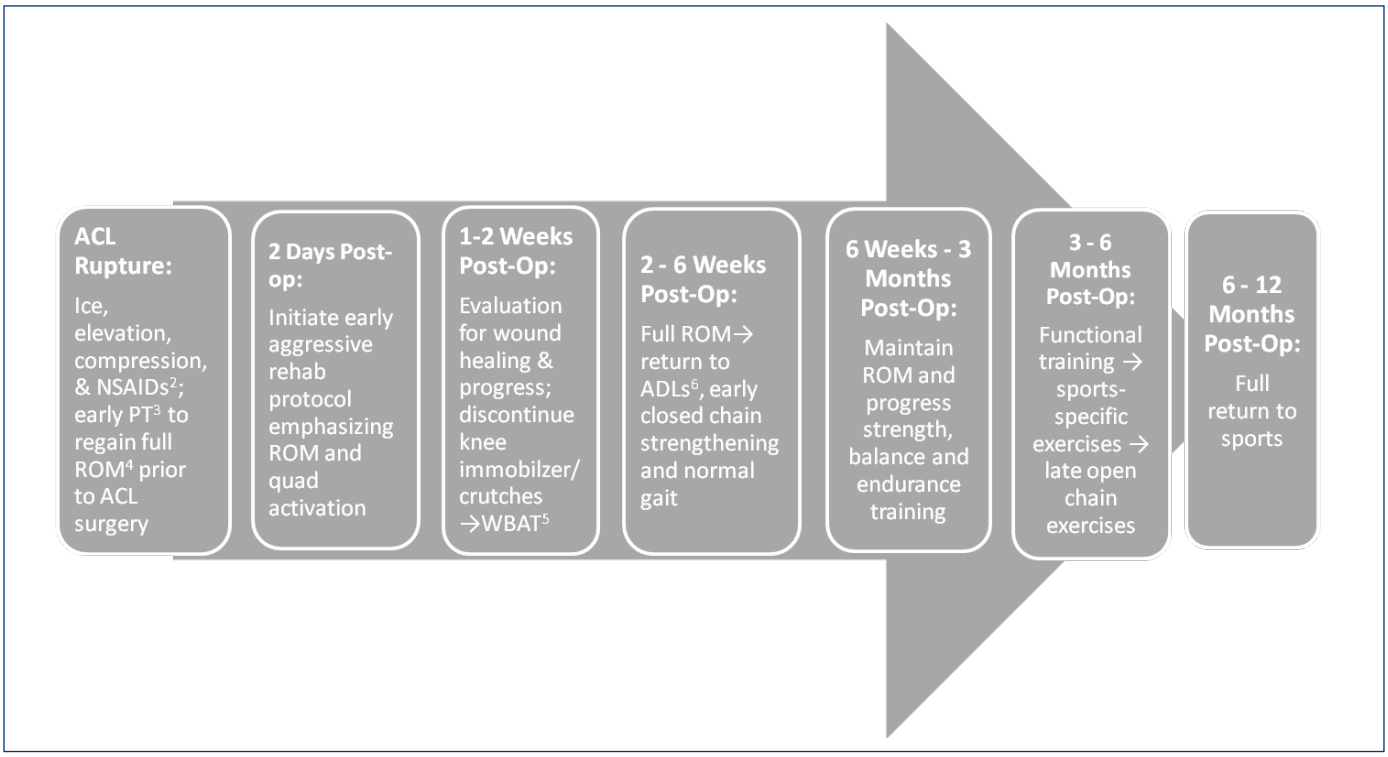

Legend: [1]Non-operative rehabilitation follows a similar but shorter progressive course, [2]Non-steroidal anti-inflammatory medications, [3]Physical therapy, [4]Range of motion, [5]Weight bearing as tolerated, [6]Activities of daily living

of motion. Early routines primarily include closed-chain exercises, in which the foot is in contact with a solid surface (ie, squats or leg presses). These exercises result in effective strengthening (ie, quadriceps and hamstring co-contraction) while minimizing stress on the healing graft, which is most susceptible to failure in this early period.[18]

Between six weeks and three months post-operatively, as graft healing proceeds, therapy should maintain range of motion and gradually improve strength and endurance. Stationary biking without resistance and gentle elliptical training are examples of appropriate early endurance activities. After three months, functional training, jogging and swimming are added. Running, plyometrics and sports-specific exercises are added as rehabilitation progresses. Open chain strengthening exercises (eg, knee extensions) place increased stress on the graft and are introduced later. Time frames for therapy advancement should be individualized. For example, sports-specific training should begin only after patients demonstrate 70% strength in the quadriceps and hamstrings compared to the preoperative contralateral extremity. Additionally, patients should regain at least 80% of pre-injury strength before resuming full sports activities.[19] Most patients can return to full sports activity between six and twelve months.[19] Bracing after ACL reconstruction has not been shown to improve outcomes and remains controversial.[20]

Following surgery and rehabilitation, the majority of patients have normal or near-normal knee function and activity outcome measurements.[21] Nearly two-thirds of athletes return to pre-injury levels of participation, and almost half resume competitive sports. It is theorized that many athletes do not fully return to prior activity levels despite good knee function because they fear re-injury.[21] Anterior knee pain (21%-35%) and loss of terminal extension (12%–17%) are the most common complications. Post-operative infections (3%-4%) and graft failures (4%-5%) are infrequent.[22] The ACL-injured joint is at high risk for osteoarthritis. The mechanism(s) of cartilage degeneration after ACL tear remain elusive and are most likely multifactorial, including: mechanical factors (eg, kinematics, altered joint loading), biologic factors (eg, inflammation, remodeling), and the presence of associated injuries (eg, subchondral bone bruising, meniscal damage). Current conservative and surgical treatment options do not reduce osteoarthritis following ACL injury.[23]

VI. CONCLUSION

ACL rupture is a common knee injury that causes instability and places the joint at risk for late osteoarthritis. A high index of suspicion and thorough history and evaluation of the patient with a "bad knee sprain" will allow a prompt and accurate diagnosis. Early rehabilitation after ACL injury enhances the likelihood of success with either operative or non-operative management, and both options can lead to good patient satisfaction and outcomes. Patients may function well with non-operative management if they regain sufficient dynamic knee stability with or without modifying their activities. Early ACL reconstruction is appropriate for younger, active patients engaged in activities that require pivoting and rapid direction changes. Surgical treatment requires reconstruction of the ACL with donor tendon tissue, with each graft choice having advantages and disadvantages. Rehabilitation after surgery is intensive and prolonged, requiring the guidance of an experienced therapist. ACL reconstruction restores knee stability with low complication rates and has excellent clinical outcomes, but does not prevent late osteoarthritis.

References

1. Levine JW, Kiapour AM, Quatman CE, Wordeman SC, Goel VK, Hewett TE, Demetropoulos CK. Clinically Relevant Injury Patterns After an Anterior Cruciate Ligament Injury Provide Insight Into Injury Mechanisms. *Am J Sports Med*. Nov 2012. [Epub ahead of print]
2. Smith HC, Vacek P, Johnson RJ, Slauterbeck JR, Hashemi J, Shultz S, Beynnon BD. Risk factors for anterior cruciate ligament injury: a review of the literature - part 1: neuromuscular and anatomic risk. *Sports Health*. 2012;4(1):69-78.
3. Maffulli N, Binfield PM, King JB, Good CJ. Acute haemarthrosis of the knee in athletes. A prospective study of 106 cases. *J Bone Joint Surg Br*. 1993;75(6):945-9.
4. Malanga GA, Andrus S, Nadler SF, McLean J. Physical examination of the knee: a review of the original test description and scientific validity of common orthopedic tests. *Arch Phys Med Rehabil*. 2003;84(4):592-603.
5. Moore SL. Imaging the anterior cruciate ligament. *Orthop Clin North Am*. 2002;33(4):663-74.
6. Sanders TG, Miller MD. A systematic approach to magnetic resonance imaging interpretation of sports medicine injuries of the knee. *Am J Sports Med*. 2005;33(1):131-48.
7. Spindler KP, Wright RW. Clinical practice. Anterior cruciate ligament tear. *N Engl J Med*. 2008;359(20):2135-42.
8. Hurd WJ, Axe MJ, Snyder-Mackler L. A 10-year prospective trial of a patient management algorithm and screening examination for highly active individuals with anterior cruciate ligament injury: Part 1, outcomes. *Am J Sports Med*. 2008;36(1):40-7.
9. Moksnes H, Snyder-Mackler L, Risberg MA. Individuals with an anterior cruciate ligament-deficient knee classified as noncopers may be candidates for nonsurgical rehabilitation. *J Orthop Sports Phys Ther*. 2008;38(10):586-95.
10. Ciccotti MG, Lombardo SJ, Nonweiler B, Pink M. Non-operative treatment of ruptures of the anterior cruciate ligament in middle-aged patients. Results after long-term follow-up. *J Bone Joint Surg Am*. 1994;76(9):1315-21.
11. Fitzgerald GK, Axe MJ, Snyder-Mackler L. The efficacy of perturbation training in nonoperative anterior cruciate ligament rehabilitation programs for physical active individuals. *Phys Ther*. 2000;80(2):128-40.
12. Beynnon BD, Ryder SH, Konradsen L, Johnson RJ, Johnson K, Renström PA. The effect of anterior cruciate ligament trauma and bracing on knee proprioception. *Am J Sports Med*. Mar-1999;27(2):150-5.
13. Yasuda K, van Eck CF, Hoshino Y, Fu FH, Tashman S. Anatomic single- and double-bundle anterior cruciate ligament reconstruction, part 1: Basic science. *Am J Sports Med*. 2011;39(8):1789-99.
14. Grøntvedt T, Engebretsen L, Benum P, Fasting O, Mølster A, Strand T. A prospective, randomized study of three operations for acute rupture of the anterior cruciate ligament. Five-year follow-up of one hundred and thirty-one patients. *J Bone Joint Surg Am*. 1996;78(2):159-68.

15. Vavken P, Fleming BC, Mastrangelo AN, Machan JT, Murray MM. Biomechanical outcomes after bioenhanced anterior cruciate ligament repair and anterior cruciate ligament reconstruction are equal in a porcine model. *Arthroscopy*. 2012;28(5):672-80.
16. West RV, Harner CD. Graft selection in anterior cruciate ligament reconstruction. *J Am Acad Orthop Surg*. 2005;13(3):197-207.
17. Barrett AM, Craft JA, Replogle WH, Hydrick JM, Barrett GR. Anterior cruciate ligament graft failure: a comparison of graft type based on age and Tegner activity level. *Am J Sports Med*. 2011;39(10):2194-8.
18. Siegel L, Vandenakker-Albanese C, Siegel D. Anterior cruciate ligament injuries: anatomy, physiology, biomechanics, and management. *Clin J Sport Med*. 2012;22(4):349-55.
19. Shelbourne KD, Klotz C. What I have learned about the ACL: utilizing a progressive rehabilitation scheme to achieve total knee symmetry after anterior cruciate ligament reconstruction. *J Orthop Sci*. 2006;11(3):318-25.
20. Kruse LM, Gray B, Wright RW. Rehabilitation after anterior cruciate ligament reconstruction: a systematic review. *J Bone Joint Surg Am*. 2012;94(19):1737-48.
21. Ardern CL, Webster KE, Taylor NF, Feller JA. Return to sport following anterior cruciate ligament reconstruction surgery: a systematic review and meta-analysis of the state of play. *Br J Sports Med*. 2011;45(7):596-606.
22. Li S, Chen Y, Lin Z, Cui W, Zhao J, Su W. A systematic review of randomized controlled clinical trials comparing hamstring autografts versus bone-patellar tendon-bone autografts for the reconstruction of the anterior cruciate ligament. *Arch Orthop Trauma Surg*. 2012;132(9):1287-97.
23. Fleming BC, Hulstyn MJ, Oksendahl HL, Fadale PD. Ligament Injury, Reconstruction and Osteoarthritis. *Curr Opin Orthop*. 2005;16(5):354-362.

Authors

Michael J. Hulstyn, MD, is an Associate professor of orthopaedics at The Warren Alpert Medical School of Brown University.

Stephen A. Klinge, MD, is a Resident physicians affiliated with the Department of Orthopedics at Rhode Island Hospital.

Gregory A. Sawyer, MD, is a Resident physician affiliated with the Department of Orthopedics at Rhode Island Hospital.

Disclosures

The authors have no financial interests to disclose.

Correspondence

Stephen A. Klinge, MD
Resident Physician
Department of Orthopedics/Rhode Island Hospital
401-444-4030
Fax 401-444-6182
steveklingemd@gmail.com