Trouble from the Tropics: Challenges in Managing Malaria in Rhode Island

JONATHAN DWORKIN, MD; MARJORIE JANVIER, MD; DIANA TREABA, MD; ADRIAN GARDNER, MD

ABSTRACT

The authors present a case of severe falciparum malaria diagnosed in a traveler after he returned to Rhode Island from a visit to the Dominican Republic. They then review aspects of the case pertinent to our local practice environment that make diagnosis and management especially challenging.

KEYWORDS: Severe falciparum malaria

BACKGROUND

Malaria causes 350-500 million infections per year worldwide, with one million resulting in death. Between 1997 and 2006 there were 10,745 cases that occurred among U.S. residents, almost all acquired during travel.[1] In Rhode Island many residents travel to the Caribbean, where malaria remains sensitive to chloroquine. However, many travelers still do not obtain consultation with a travel medicine specialist prior to leaving the country, increasing their chances of acquiring a life-threatening infection. This case describes the challenges raised in diagnosing and managing severe malaria in a returning traveler to Rhode Island, including the controversial use of exchange transfusions to quickly reduce parasite burden.

The Case

The patient was a 57-year-old man with a medical history of hypertension, hyperlipidemia and depression who traveled to the Dominican Republic on a snorkeling vacation. He did not see a travel physician before leaving town, and he did not make use of malaria prophylaxis or mosquito repellant. He recalled no insect exposure while travelling.

A week after returning home the patient developed nightly fevers and chills. His maximum temperature exceeded 104 F. He went to an urgent care center where he was given a presumptive diagnosis of sinusitis. He received amoxicillin-clavulanate for 10 days and prednisone for 5 days. The fevers decreased in intensity, but they continued to occur every 48–72 hours.

In the days leading up to admission the patient experienced progressive fatigue and anorexia. He also experienced watery diarrhea, cough and shortness of breath. On the day of admission his wife returned from work and realized he couldn't get out of bed. This is when she brought him to the hospital.

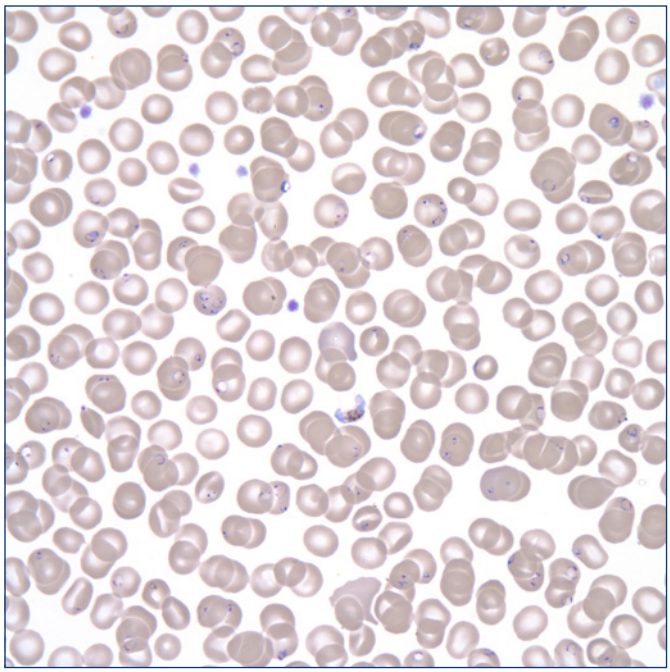

Picture 1. Gametocytes present on the smear confirmed the diagnosis was falciparum malaria.

In the emergency room the patient's systolic blood pressure was in the 80s. Lab tests were quickly obtained and showed a parasitemia on admission of 20.8%. Gametocytes present on the smear confirmed the diagnosis was falciparum malaria (Picture 1). He also had acute renal failure (creatinine 4.8 mg%), hyperbilirubinemia (total bilirubin 10.0 mg%), and thrombocytopenia. Blood pressure responded to saline boluses and he was admitted to the ICU.

The patient received an intravenous quinidine-loading dose upon admission, but his QTc increased by 24% after the bolus, and the team then discontinued the quinidine. After discussing the case with the on-call fellow at the CDC malaria hotline the team decided to initiate IV artesunate and red-cell exchange transfusions. The medication was sent the following morning from the CDC facility in New York City. The patient was awake and able to take PO medications on the evening of admission, so while awaiting the IV artesunate, the team administered two doses of PO artemether-lumefantrine.

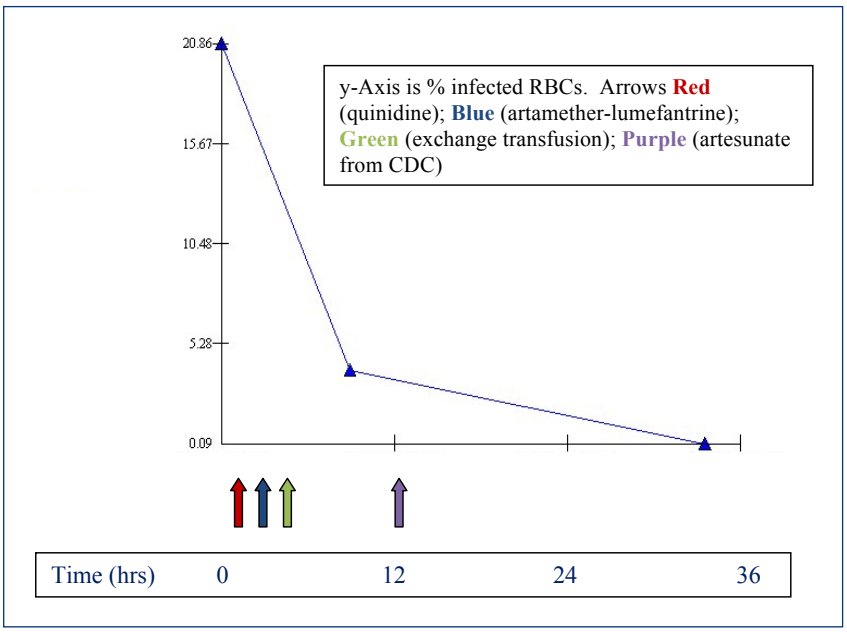

Figure 1. Over the next 48 hours the patient demonstrated significant clinical improvement. Even before starting the IV artesunate, his degree of parasitemia came down to 3.9%.

Over the next 48 hours the patient demonstrated significant clinical improvement. Even before starting the IV artesunate, his degree of parasitemia came down to 3.9% (**Figure 1**). This improvement occurred after receiving the quinidine-loading dose, two oral doses of artemether-lumenfantrine, and a 12-unit red cell exchange transfusion. He then continued on the intravenous artesunate in combination with intravenous doxycycline. Two days after admission the degree of parasitemia was 0.9%. His other clinical parameters also significantly improved. He completed IV artesunate after three days, and he then received three additional days of malarone. Parasite smears were negative after completing the IV artesunate.

DISCUSSION

This case raises several points about the diagnosis and management of severe Plasmodium falciparum malaria in Rhode Island. First, there was a delay in diagnosis due to a low index of suspicion by a doctor working at an urgent care clinic. Second, there can be initial confusion about whether intraerythrocytic ring form parasites on a peripheral blood smear, in a region endemic for Babesia, represented Plasmodium falciparum malaria or infection with Babesia species. Third, there were difficulties obtaining an appropriate intravenous agent for the treatment of severe Plasmodium falciparum malaria. Finally there was the debate regarding the role of red-cell exchange transfusions in management of severe disease.

The missed opportunity to diagnose this infection early emphasizes the need to better integrate urgent care centers into the educational and quality improvement initiatives common at larger institutions. Easy access to patient medical records and laboratory test results, through a statewide electronic medical system, would also enhance the ability of urgent care clinicians to identify and follow up on pertinent details of the patient's care.

Differentiation of Plasmodium falciparum malaria from Babesia is based primarily on morphological characteristics of the parasites on smear. In this case the presence of gametocytes was diagnostic of falciparum malaria. This required consultation with an expert pathologist during the night of admission, a resource not available in many settings.

The management of severe falciparum malaria in technologically advanced countries raises several issues that tend to be less relevant to practitioners in endemic areas where the disease is more common.[2-4] Interestingly, intravenous artemether compounds, which are the gold standard in much of the world, are not yet licensed in the United States. Physicians here must use intravenous quinidine as first-line therapy for severe malaria, a treatment notorious for causing electrolyte disturbances, QTc prolongation, and potentially dangerous arrhythmias. In this case dramatic QTc prolongation caused the clinical team to abandon quinidine therapy. The team was able to obtain intravenous artesunate from the CDC, but only after a significant 12-hour delay.

The role of red-cell exchange transfusions in the treatment of severe malaria is controversial. Studies looking at the utility of exchange transfusions in the past have suffered from methodological flaws and mixed results.[5] In the developing world, where ICU support services are scarce and the blood supply is often unsafe, the strategy is less promising. However in this case, where the ICU and transfusion support services were excellent, and where intravenous artemether was not initially available, exchange transfusion formed a crucial bridge to definitive therapy. The low number of cases of severe falciparum malaria in the United States makes it unlikely that a randomized trial will be performed.

CONCLUSION

In conclusion, we present a case of severe falciparum malaria in a Rhode Island resident returning from travel to the Caribbean. The case demonstrates multiple challenges in the care of severe malaria patients intrinsic to practice in this environment. In particular the case shows the need to better integrate urgent care centers into educational and quality improvement initiatives common in other settings, the need to improve the availability of first-line treatments for severe malaria, and the promising role of exchange transfusion in resource-intensive settings where benefit almost certainly outweighs risks.

References

1. Centers for Disease Control. *Health Information for International Travel 2010: The Yellow Book*. 2009;128-143. Mosby Elsevier.
2. Sarkar P, Ahluwalia G, Vijayan V, Talwar A. Critical care aspects of malaria. *Journal of Intensive Care Medicine*. 2010;25(2):93-103.
3. Das BS. Renal failure in malaria. *J Vector Borne Disease*. 2008;45:83-97.
4. Mishra S, Newton C. Diagnosis and management of the neurological complications of falciparum malaria. *Nat Rev Neurol*. 2009;5(4):189-98.
5. Shelat S, Lott J, Braga M. Considerations on the use of adjunct red blood cell exchange transfusion in the treatment of severe Plasmodium falciparum malaria. *Transfusion*. 2010;50:875-880.

Authors

Jonathan Dworkin, MD is a Former Brown fellow in infectious diseases, and is now assistant professor of medicine at the University of Hawaii, John A. Burns School of Medicine.

Marjorie Janvier, MD was a Fellow affiliated with the Division of Infectious Diseases, Brown University.

Diana Treaba, MD is an Assistant professor of pathology at the Warren Alpert Medical School of Brown University.

Adrian Gardner, MD is a Research assistant professor of medicine at the Warren Alpert Medical School of Brown University.

Disclosures

The authors have no financial disclosures to report.

Correspondence

Jonathan Dworkin
jdworkin@hotmail.com