High-Pressure Injection to the Great Toe with River Water

TODD R. BORENSTEIN, MD; JOEY P. JOHNSON, MD; BRIAN COHEN, MD; PATRICK KANE, MD

ABSTRACT

CASE: A 53-year-old male sustained a high-pressure water injection injury to his foot while working in a river. He was taken to the operating room for emergent irrigation and debridement of copious riverbed sediment. Cultures taken from the operating room were positive for multiple anaerobes, fungus and mold and he was treated with appropriate antibiotics. To date, his only residual deficit is a 1 cm area of numbness at the entrance wound.

CONCLUSION: High-pressure water injections to the foot are uncommon injuries. These are serious injuries that require emergent antibiotics, tetanus and surgical debridement.

KEYWORDS: Trauma, Emergency Care, Orthopedics, High-Pressure Injection Injury

INTRODUCTION

High-pressure injection injuries (HPII) of the foot are uncommon injuries, and are usually the result of industrial work accidents. A HPII to the foot, as in the hand, may have devastating consequences. Sequelae of these injuries include serious injury to the soft tissues, neurovascular structures, decreased long-term function and may ultimately result in amputation.[1] HPII most commonly occur in men, with the non-dominant hand being the most frequent location; however, injuries have also been reported in the feet, legs, abdomen and face.[2–5] The injected material provokes an inflammatory response causing pain and swelling and can often lead to irreversible tissue destruction.[1] There continues to be a question in the literature as to whether injections with certain materials such as water necessitate operative intervention.

CASE REPORT

We present a case of a 53-year-old healthy male who was volunteering in a local river-cleaning project (Blackstone River, Rhode Island). He was attempting to clean a turbine in the riverbed when he sustained a power washer injury to his foot. He was submerged to his waist in the river and was wearing thick rubber boots. Given the cold temperature of the water, the patient continued working for one hour after the time of injury. He only noticed the extent of the injury after he had exited the river. He then realized the pressure washer had perforated his rubber boot and two pairs of socks. Upon inspection of his foot he noticed a small hemorrhagic lesion and consequently presented to Rhode Island Hospital (RIH), four hours after injury.

At presentation to RIH ED, the urgency of his HPII was noted immediately and the patient was taken emergently to the OR for irrigation and debridement. Upon arrival in the OR, the foot presented with a pinhole injury (assumed entrance wound) and streaking proximal erythema (**Figure 1**). The foot was neurovascularly intact; however, he had exquisite tenderness proximal to the zone of injury. In the OR an extensive debridement was performed. Debris was noted on his radiographs as well as grossly during initial debridement

Figure 1. The patient's foot at presentation with a pinhole injury (assumed entrance wound) and streaking erythema.

(**Figure 2 and 3**) and had infiltrated vascular structures (**Figure 4**). All gross debris was excised at the initial debridement (**Figure 5**). Cultures were sent from the OR, and the wound was copiously irrigated and washed in a betadine/lactated ringers solution and primarily closed with interrupted nylon suture. The patient remained hospitalized for three days, to allow daily examination of the wound. He was seen in consultation by the infectious disease team and was started empirically on IV levofloxacin 750mg IV daily and Zosyn 4.5g q6h. He was made non-weight bearing for three weeks to allow the soft tissue to heal and was discharged on levofloxacin 500mg daily.

Figure 2. The initial radiograph showing debris tracking proximally from injection site.

Figure 3. Gross debris noted at initial debridement.

Figure 4. Debris tracking along and infiltrating vascular structures.

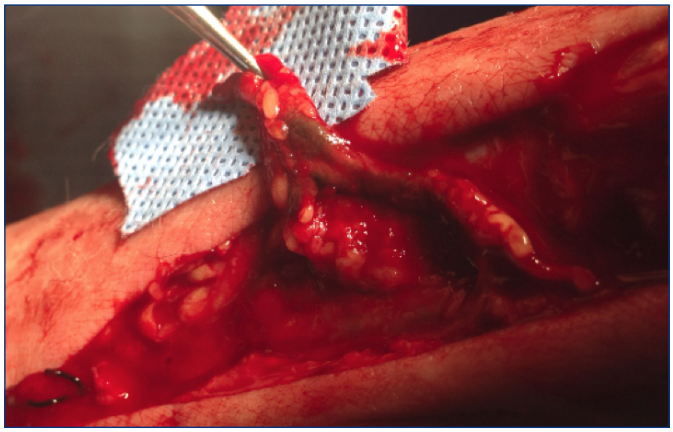

Figure 5. Wound after all gross debris was excised at the initial debridement.

Cultures grew multiple anaerobes (B. cereus, Bacillus sp. not Anthrasis, Cornybacterium sp, Clostridium sp) and Stenotrophomonas maltophilia, requiring the addition of Flagyl 500mg q8h. Approximately two weeks after injury the cultures began to grow 1+ Fusarium and 1 colony mold consistent with Acremonium species; consequently Voriconazole was added. At three weeks post-op, his wound continued to heal with a 2 cm zone of eschar focused around the initial injection injury. At six weeks his incision had almost fully healed with a half-centimeter eschar remaining. His antibiotics were continued for a total of six weeks for levofloxacing and flagyl and four weeks for voriconazole. His recovery after initial debridement was uneventful; at no time did he present with systemic signs of infection. CBC, ESR, and CRP were followed throughout his recovery and all had returned to baseline normal by four weeks post injury. He was made weight bearing as tolerated three weeks after injury. His only residual symptoms are localized numbness approximately 1 cm in diameter centered over the initial injection wound.

DISCUSSION

HPII are associated with irreversible tissue ischemia with several described mechanisms. First, the injected material dissects through tissue planes of least resistance and can lead to compression of neurovascular structures and vasospasm causing tissue ischemia. Second, the injected material may create enough pressure to decrease tissue perfusion, resulting in a local compartment syndrome. Third, the material itself may result in a localized toxicity secondary to the chemical properties of the injected material. Lastly, ischemia and tissue necrosis set the stage for secondary infection which is frequently encountered with these injuries.[7] As our case report demonstrates, river water should be considered a potent biological and chemical toxin.[6]

On first inspection of HPII, the entry wound is a small, benign appearing puncture. Additionally, patients initially have little to no pain, which may explain delays in seeking medical attention as well as missed diagnoses.[1,8] An accurate history should be obtained at presentation to determine the material injected, the pressure of the gun and the distance of the extremity from the gun.[8] A thorough physical examination should include the entry and exit wounds if present, neurovascular status, and the presence of the injected material.[8,9] Additionally, radiographs are necessary to determine the extent of the injected material, assess for other foreign bodies and exclude fractures.[1,8,9] Broad-spectrum antibiotics and tetanus prophylaxis are mandatory. Surgical debridement is necessary, although there are reports of successful conservative management of high-pressure injuries with water, air, and vaccine.[1,2,7,10,11]

The degree of tissue damage depends on the pressure of the injection and the amount and type of injected material. The most frequent injected agents are grease, paint, paint-thinner, diesel oil, hydraulic fluid, and gasoline, while reports of water and air are less common. Significantly, this is only the second report we were able to find on injected river water, although similar to the report of sea mud injection by Marinovic et al.[3,6]

A meta-analysis of high-pressure injection injuries concluded that the type of injected material was the most important factor affecting outcomes.[1,12] The authors found that 4 of 5 (80%) patients injected with paint thinner or turpentine required eventual amputation. Whereas only 9 of 40 (22.5%) patients injected with grease, a much less caustic agent, required amputation.[1,12] A review by Hogan et al had similar findings and found that organic solvents such as paint, paint-thinner, diesel fuel, gasoline and oil resulted in amputation 40% of the time. They concluded that these agents cause an inflammatory response that promotes vasospasm and tissue necrosis.[1] Additionally, paint is considered by some to be the most toxic injected agent. However Hogan et al found the rate of amputation with latex-based paints was only 6%, whereas it was 58% with oil-based paints.[1] While strong solvents to clean oil-based paints such as toluene and turpentine are discouraged due to risk of further tissue damage, a study by Urso-Baiarda et al found that the use of butter to emulsify and facilitate solvent removal enhanced tissue cleansing.[13] Additionally, many painters find that baby oil is useful to emulsify oil paints and may have a role to play in gentle tissue cleansing of oil-based paints. In our case, we irrigated the wound with a mixture of lactated ringers and betadine solution. Subjectively we felt that the yellow coloring of the betadine/lactated ringers irrigant made visualizing the small dirt particles easier. It is possible that this is a result of enhanced contrast due to blue-light filtering, similar to the effect of wearing yellow-lensed glasses.[14]

There are few other case reports of HPII with water. A report by Bussewitz et al detailed an incident of a 40,000-psi -pressure water washer injury to the hallux. The patient did well after aggressive multiple debridements, foot and lower extremity fasciotomies, antibiotics and eventual primary closure.[2] The pressure of the injection injury is an important factor to consider. A recent review demonstrated that when the pressure of the injection was less then 1000-psi for all injected materials the amputation rate was 19%. With pressures greater than 1000-psi, the amputation rate increased to 43%, demonstrating increased injury to the soft tissues and neurovascular structures. However, it is important to note that in the same review no cases of injection with water or air resulted in amputation, independent of pressure or surgical versus nonsurgical treatments.[1]

The question of when to treat high-pressure water injuries with surgical debridement continues to be debated. The most important factor to consider is the source of water.[9] Water sources for high-pressure sprayers can come from enclosed containers, or may be siphoned from nearby water sources such as rivers, lakes, and ponds.[2,9,15] Even the water from enclosed containers poses a threat as these containers can grow bacteria from sewage and industrial waste.[2,6] Additionally, water from a presumed safe water supply may lead to infection from atypical bacteria.[9] Although water is not overly inflammatory, most high-pressure guns are lubricated with oils that may consist of inflammatory agents such as carbons, sulfur, and vanadium.[2,16]

CONCLUSION

All patients with a HPII should be admitted to the hospital, given broad-spectrum antibiotics to cover both gram-negative and gram-positive organisms, and in our opinion, should undergo thorough surgical exploration and debridement. All devitalized tissue and foreign material should be removed, and cultures should be sent. We recommend using a betadine-saline solution for both its antimicrobial properties and improved visualization of dark colored foreign material. Additionally, we think there may be a role for the use less harsh solvents, such as baby oil, for aiding in removal of oil-based paints despite previous literature supporting the contrary. Post-operatively the patient should be monitored

closely for signs of infection and compartment syndromes. Re-exploration should be utilized if any signs of infection develop, or to reassess the wound if a large amount of foreign material was initially encountered.

References

1. Hogan, CJ, Ruland, RT: High-pressure injection injuries to the upper extremity: a review of the literature. *J Orthop Trauma* 2006;20:503–511.
2. Bussewitz, B, Littrell, S, Fulkert, K, VanCourt, R: High-pressure water injection of the foot with associated subcutaneous emphysema: a case report. *J Foot Ankle Surg Off Publ Am Coll Foot Ankle Surg* 2010;49:399.e15–20.
3. Marinovic, M, Bakota, B, Spanjol, J, Sosa, I, Grzalja, N, Gulan, G, Ivancic, A, Cicvaric, T: High-pressure injection injury of the foot: a role of negative pressure wound therapy. *Injury* 2013;44 Suppl 3:S7–10.
4. Smith, TE, Jr, Canady, JW, Jons, CD: Cervicofacial high-pressure hydraulic injection injury. Report of a case. *Arch Otolaryngol Chic Ill 1960* 1982;108:452–453.
5. Neill, RW, George, B: Penetrating intra-abdominal injury caused by high-pressure water jet. *Br Med J* 1969;2:357–358.
6. Greenberg, MI: High-pressure injection injury with river water. *JACEP* 1978;7:241–242.
7. Verhoeven, N, Hierner, R: High-pressure injection injury of the hand: an often underestimated trauma: case report with study of the literature. *Strateg Trauma Limb Reconstr Online* 2008;3:27–33.
8. Pappou, IP, Deal, DN: High-pressure injection injuries. *J Hand Surg* 2012;37:2404–2407.
9. Walker, WA, Burns, RP, Adams, J, Sr: High-pressure water injury: case report. *J Trauma* 1989;29:258–260.
10. Kon, M, Sagi, A: High-pressure water jet injury of the hand. *J Hand Surg* 1985;10:412–414.
11. Pai, CH, Wei, DC, Hou, SP: High-pressure injection injuries of the hand. *J Trauma* 1991;31:110–112.
12. Schoo, MJ, Scott, FA, Boswick, JA, Jr: High-pressure injection injuries of the hand. *J Trauma* 1980;20:229–238.
13. Urso-Baiarda, F, Stanley, PRW: The "Butter Test" to guide effective tissue cleansing after high-pressure injection injury. *J Plast Reconstr Aesthetic Surg JPRAS* 2010;63:e792–795.
14. Wolffsohn, JS, Cochrane, AL, Khoo, H, Yoshimitsu, Y, Wu, S: Contrast is enhanced by yellow lenses because of selective reduction of short-wavelength light. *Optom Vis Sci Off Publ Am Acad Optom* 2000;77:73–81.
15. Larsson, P, Lundin, O, Falsen, E: "Corynebacterium aquaticum" wound infection after high-pressure water injection into the foot. *Scand J Infect Dis* 1996;28:635–636.
16. Calhoun, JH, Gogan, WJ, Viegas, SF, Mader, JT: Treatment of high-pressure water gun injection injury of the foot with adjunctive hyperbaric oxygen: a case report. *Foot Ankle* 1989;10:40–42.

Authors

Todd R. Borenstein, MD, Department of Orthopedics, Warren Alpert Medical School, Brown University, Providence, RI

Joey P. Johnson, MD, Department of Orthopedics Warren Alpert Medical School, Brown University, Providence, RI

Brian Cohen, MD, Department of Orthopedics Warren Alpert Medical School, Brown University, Providence, RI

Patrick Kane, MD, Department of Orthopedics, Clinical Instructor, Warren Alpert Medical School, Brown University, Providence, RI

Correspondence

Joey P. Johnson, MD
Department of Orthopedics
593 Eddy Street
Providence, RI 02818
Phone: 678-234-4385
Joey.johnson12@gmail.com