Systemic Amyloidosis Masquerading as Intractable Cardiomyopathy

LINDSEY CILIA, MD; LESLIE PARIKH, MD; MADHU M. OUSEPH, MD, PhD; EDWARD STOPA, MD; MICHAEL K. ATALAY, MD, PhD

KEYWORDS: cardiac amyloidosis, MRI, multiple myeloma

INTRODUCTION

Cardiac amyloidosis is an infiltrative cardiomyopathy in which amyloid protein is deposited throughout the myocardium. It is increasingly recognized as a cause of heart failure with preserved ejection fraction in the elderly. Presenting symptoms include exercise intolerance, fatigue, angina, breathlessness and syncope or pre-syncope.[1] Atrial fibrillation is the most common early arrhythmia, with ventricular fibrillation occurring later in the course of the disease.[1]

This case presents a 79-year-old man with multiple myeloma and non-ischemic cardiomyopathy whose diagnostic tests failed to illustrate the typical findings seen in cardiac amyloidosis, although extensive cardiac amyloid deposition was seen at autopsy. This case highlights the need to pursue myocardial biopsy as the gold standard test if clinical suspicion is high.

CASE PRESENTATION

A 79-year-old man presented to the hospital after one day of fever, nausea and vomiting. History included non-ischemic cardiomyopathy with an ejection fraction (EF) of 35%, smoldering multiple myeloma diagnosed by bone marrow biopsy in 2014 with evidence of focal amyloid deposition, and cholangiocarcinoma status-post roux-en-y and hepato-jejunostomy with stenting in 2013. He had diabetes, hyperlipidemia, and anxiety. After the diagnosis of smoldering myeloma, he was lost to follow-up, so no treatment was initiated. Medications included aspirin, atorvastatin, metformin, metoprolol, lisinopril, mirtazapine and venlafaxine. He had a 20 pack-year smoking history and drank alcohol occasionally. His family history was significant for multiple myeloma in his sister.

Nine months earlier he was hospitalized for new onset heart failure. EKG was normal and echocardiogram demonstrated an EF of 35%. Cardiac catheterization showed minimal coronary artery disease. Clinical concern for cardiac amyloidosis, given his history of smoldering myeloma and bone marrow amyloid, prompted cardiac MRI. MRI demonstrated features concerning for myocarditis without evidence of cardiac amyloid (**Figures 1&2**). Hospitalization was complicated by multiple episodes of monomorphic ventricular tachycardia. He was started on lisinopril and metoprolol and discharged with the diagnosis of heart failure secondary to myocarditis of unknown etiology.

At his current presentation, his temperature was 101.2F, with a blood pressure of 122/74 mmHg, a regular heart rate of 100 bpm, and a respiratory rate of 20 breaths per minute with an oxygen saturation of 97% on room air. His exam was notable for diffuse abdominal tenderness. EKG showed normal sinus rhythm, normal voltage, and QTc prolongation of 514. Computed tomography of the abdomen showed new hypodense lesions within the right hepatic lobe

Figure 1. Cardiac MRI of the patient. Horizontal long axis (a) and mid-ventricle short axis (b) end-diastolic views were taken from "bright-blood" cine loops. The left atrium (LA) is mildly dilated. There is no left ventricular (LV) thickening. Images (c) and (d) are corresponding post-contrast views. Normal myocardium appears black and abnormal myocardium, bright (enhancement). The proximal interventricular septum has a small linear focus of enhancement (arrow). Questionable enhancement is seen in the LA posterior and subendocardial LV free walls (arrowheads). These imaging findings are not typical of cardiac amyloidosis. RV: right ventricle.

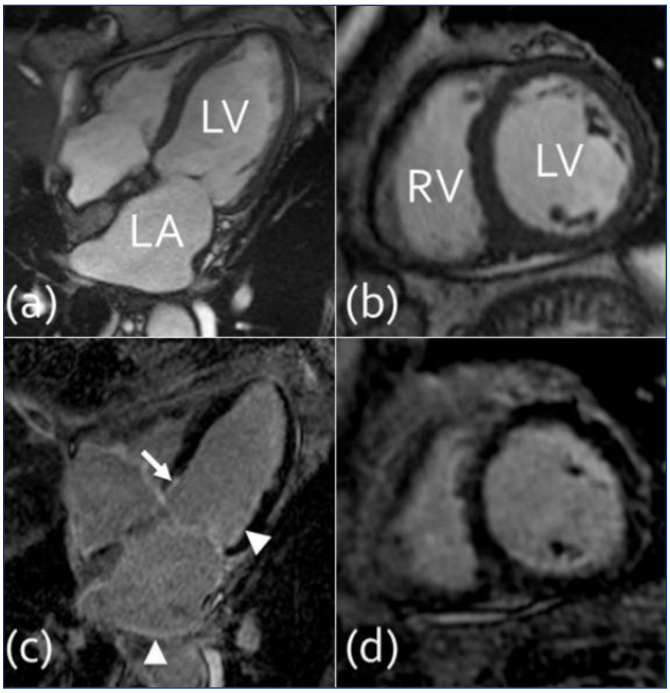

Figure 2. Cardiac MR images of another patient with biopsy proven cardiac amyloidosis. Image on left is a mid-ventricle short axis end-diastolic view from a bright-blood cine loop. Note the left ventricular (LV) thickening, worst inferiorly (arrowheads). A small pericardial effusion is also present (arrows). Image on right is a corresponding post-contrast view. There is no normal (black) myocardium; instead the myocardium is heterogeneously gray. These findings are virtually pathognomonic for cardiac amyloidosis.

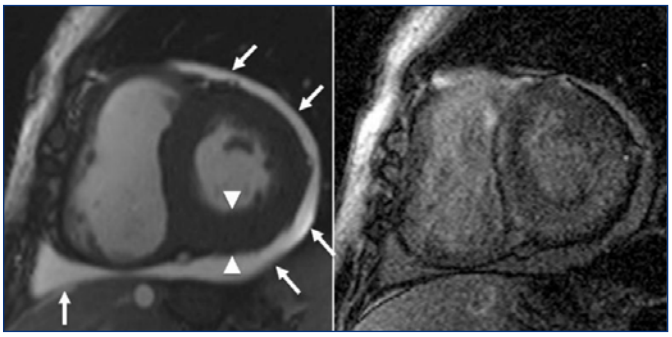

Figure 3. Congo red stain of interventricular myocardium shows scattered plasma cells with extensive salmon pink colored amorphous deposits in the interstitium and small arteries (left), also present in both atria and ventricles. These deposits demonstrate apple green birefringence under polarized light, consistent with amyloid deposition (right).

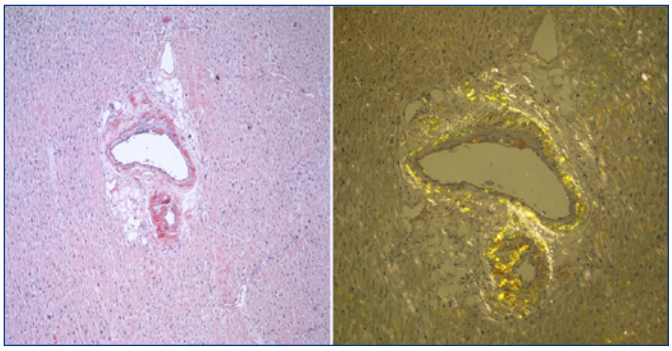

with intrahepatic biliary ductal dilatation, concerning for micro-abscesses. He had a white blood cell count 12.1 x 10^9 cells/L, elevated alkaline phosphatase (223 IU/L, upper limit of normal is 104 IU/L), and elevated troponin (0.21 ng/mL, upper limit of normal is 0.06 ng/mL). He was admitted for ascending cholangitis complicated by liver micro-abscesses and started on piperacillin-tazobactam and vancomycin. Blood cultures returned positive for *Enterococcus faecalis,* prompting a switch to linezolid and gentamicin. His course was complicated by multiple episodes of polymorphic ventricular tachycardia (PMVT), in the absence of profound electrolyte abnormalities, ischemia or acidosis, requiring direct current cardioversion and amiodarone. The refractory PMVT episodes raised concern for recurrent myocarditis or progressive cardiomyopathy. His family decided to focus on comfort measures and hours later, the patient expired from a ventricular arrhythmia. Autopsy revealed plasma cell myeloma and systemic AL (light chain) amyloidosis with extensive deposition in the cardiovascular, gastrointestinal, respiratory, and genitourinary systems, and involvement of skin and bone marrow.

DISCUSSION

Three types of amyloid are responsible for the majority of cardiac involvement. They include (1) light chain (AL) amyloidosis (2) senile systemic amyloidosis (SSA) and (3) the hereditary forms. While AL amyloidosis occurs in isolation, 10% of patients with multiple myeloma develop systemic AL amyloid.[2] Clinical evidence of cardiac involvement occurs in up to 50% of patients with AL amyloidosis.[2] The classic electrocardiogram finding is low voltage.[3] Low QRS voltages (all limb leads <5 mm in height) with poor R-wave progression in the chest leads occur in up to 50% of patients with cardiac AL amyloidosis. Characteristic echocardiographic features include a thickened interventricular wall, diastolic dysfunction and preserved EF.[2] EKG and echocardiogram have poor sensitivity to detect cardiac amyloidosis, so cardiac MRI is emerging as the preferred diagnostic modality.[4] Cardiac MRI has excellent spatial resolution for tissue characterization with an 80% sensitivity for detecting infiltrative cardiomyopathy.[4,1] MRI in cardiac AL amyloidosis usually demonstrates global and subendocardial late gadolinium enhancement of the myocardium due to increased interstitial cardiac volume as amyloid replaces normal myocardium.[3]

Despite extensive amyloid deposition throughout the myocardium and cardiac conduction system, our patient did not demonstrate characteristic electrocardiographic, echocardiographic, or cardiac MRI findings (**Figures 1&2**), highlighting the importance of endomyocardial biopsy. Biopsy remains the gold standard for diagnosis, and shows amyloid deposits (**Figure 3**).[3]

AL amyloidosis management involves both slowing protein production and deposition, and preventing complications including cardiac arrhythmias and decompensated heart failure. AL amyloidosis results from extracellular deposition of monoclonal immunoglobulin light chains secreted by a plasma cell clone. Most patients have an isolated monoclonal gammopathy or smoldering myeloma.[5] Treatment goal is to suppress the plasma cell dyscrasia, thus reducing the production of immunoglobulin light chains and minimizing end-organ damage.[6] Combination therapy with bortezomib, melphalan and dexamethasone provokes a rapid response in most patients with AL amyloidosis and is preferred for cardiac amyloidosis patients needing prompt reduction of pathogenic light chain.[7] Further regimen selection is dependent upon extent of organ involvement and potential toxicities.[6]

Cardiac involvement, manifested as diastolic heart failure, left ventricular hypertrophy and ventricular arrhythmias, is the main determinant of prognosis in AL amyloidosis. Electrophysiology studies suggest the His-Purknjee system is the most affected part of the conduction system in patients,

causing QTc prolongations and ventricular arrhythmias.[3] Cardioverter-defibrillator (ICD) implantation in cardiac AL amyloidosis can prolong survival with a good quality of life, and may be appropriate in some settings.[8] Although data on the efficacy of antiarrhythmic medications in AL amyloidosis is lacking, amiodarone is widely used and has shown benefit.[6] In patients with AL amyloidosis with limited extra-cardiac involvement and systemic disease control, cardiac transplantation is an evolving therapeutic option that may decrease mortality and reduce complications including heart failure and arrhythmia.[9] The prognosis of systemic AL amyloidosis with dominant cardiac involvement is generally very poor. However, timely and tailored chemotherapy along with ICD implantation, antiarrhythmic therapy or cardiac transplantation can improve survival and decrease morbidity.[8]

Acknowledgments

We thank Dr. Caitlin Dugdale for editorial assistance and contribution to literature review.

References

1. Sharma, N. & Howlett, J. Current state of cardiac amyloidosis. *Current Opinion in Cardiology* **28**, 242-248 (2013).
2. Sedaghat, D., Zakir, R. M., Choe, J., Klapholz, M. & Saric, M. Cardiac amyloidosis in a patient with multiple myeloma: a case report and review of literature. *Journal of clinical ultrasound : JCU* **37**, 179-184, doi:10.1002/jcu.20552 (2009).
3. Basha, H. I., Raj, E. & Bachuwa, G. Cardiac amyloidosis masquerading as biventricular hypertrophy in a patient with multiple myeloma. *BMJ case reports* **2013**, doi:10.1136/bcr-2012-008113 (2013).
4. Mohty, D. *et al.* Cardiac amyloidosis: updates in diagnosis and management. *Arch Cardiovasc Dis* **106**, 528-540, doi:10.1016/j.acvd.2013.06.051 (2013).
5. Desport, E. *et al.* Al amyloidosis. *Orphanet J Rare Dis* **7**, 54, doi:10.1186/1750-1172-7-54 (2012).
6. Wechalekar, A. D. *et al.* Guidelines on the management of AL amyloidosis. *British journal of haematology* **168**, 186-206 (2015).
7. Hayashi, T. *et al.* Addition of bortezomib to melphalan plus dexamethasone provides rapid response in AL amyloidosis. *Blood* **124** (2014).
8. Patel, K. S., Hawkins, P. N., Whelan, C. J. & Gillmore, J. D. Life-saving implantable cardioverter defibrillator therapy in cardiac AL amyloidosis. *BMJ case reports* **2014**, doi:10.1136/bcr-2014-206600 (2014).
9. Roeker, L. E. *et al.* Cardiac transplantation in immunoglobulin light chain amyloidosis: A large single center experience. *Journal of the American College of Cardiology* **63**, A887 (2014).

Authors

Lindsey Cilia, MD, PGY-3, Department of Internal Medicine, Alpert Medical School of Brown University, Rhode Island Hospital, Providence, RI.

Leslie Parikh, MD, Fellow, Division of Cardiology, Alpert Medical School of Brown University, Rhode Island Hospital, Providence, RI.

Madhu M. Ouseph, MD, PhD, Resident, Department of Pathology, Alpert Medical School of Brown University, Rhode Island Hospital, Providence, RI.

Edward Stopa, MD, Professor, Department of Pathology, Alpert Medical School of Brown University; Director of the Neuropathology Division at Rhode Island Hospital, Providence, RI.

Michael K. Atalay, MD, PhD, Associate Professor of Diagnostic Imaging and Associate Professor of Medicine, Department of Diagnostic Imaging, Alpert Medical School of Brown University, Providence, RI.

Disclosures

None of the authors report a conflict of interest

Correspondence

Lindsey Cilia, MD
Department of Internal Medicine
Rhode Island Hospital – JB 0100
593 Eddy Street
Providence, RI 02903
516-524-2114
Fax 401-444-3056
lcilia@lifespan.org
lindseycilia4@gmail.com