Current Strategies in the Surgical Management of Ischemic Stroke

CODY A. DOBERSTEIN, BS; RADMEHR TORABI, MD; SANDRA C. YAN, BS, BA; RYAN McTAGGART, MD; CURTIS DOBERSTEIN, MD; MAHESH JAYARAMAN, MD

ABSTRACT

Stroke is a major cause of death and disability in the United States and rapid evaluation and treatment of stroke patients are critical to good outcomes. Effective surgical treatments aim to restore adequate cerebral blood flow, prevent secondary brain injury, or reduce the likelihood of recurrent stroke. Patient evaluation in centers with a comprehensive stroke program and a dedicated neurovascular team is recommended.

KEYWORDS: stroke, embolectomy, cerebrovascular occlusion

INTRODUCTION

Stroke is the leading cause of long-term adult disability in North America and the fifth leading cause of death.[1,2] Although some strokes are hemorrhagic, the majority (87%) are ischemic due to insufficient cerebral blood flow secondary to occlusion or flow limiting stenosis. Brain tissue is exquisitely sensitive to ischemia, and an estimated 1.9 million neurons die every minute that blood flow is not restored. Time is brain.[3]

Surgical treatment for stroke can be classified into acute (emergent) or non-acute. Acute interventions, initiated within hours of stroke onset, are aimed at reestablishing cerebral blood flow, restoring lost neurologic function, and preventing permanent tissue damage. Non-acute surgical therapies focus on reducing secondary injuries resulting from brain swelling or preventing recurrent stroke.

The effective surgical management of stroke requires continuous and immediately available treatment by dedicated personnel specializing in complex cerebrovascular interventions. These requirements may be best accomplished in facilities with a dedicated neurovascular center and stroke program.

EMERGENT EMBOLECTOMY FOR STROKE

Intravenous tissue plasminogen activator (IV-tPA) remains an effective medical treatment in stroke patients if administered within 4.5 hours of symptom onset. However, 20–30% of acute ischemic stroke patients have evidence of large vessel occlusion (LVO) involving a major proximal intracranial artery and the efficacy of IV-tPA is significantly reduced in these cases.[4] Furthermore, many patients do not fit the strict time window and inclusion criteria for the administration of IV-tPA and therefore are ineligible to receive treatment.

The recent refinement of endovascular catheter-based surgical techniques, which use a stent-retriever device to directly remove clots from occluded vessels and restore blood flow, have proven effective in reducing morbidity and mortality in stroke patients with LVO. Several recent randomized studies have demonstrated a significant benefit of embolectomy compared to standard medical treatment alone.[5,6] Due to improved outcomes, embolectomy in combination with IV-tPA has now become the standard of care for patients with LVO stroke. **Figure 1** demonstrates pre- and post-angiographic images in a patient who underwent emergent embolectomy and shows the dramatic improvement of cerebral perfusion following recanalization.

In addition to improving outcomes, embolectomy has less restrictive enrollment criteria and a longer time treatment window (usually 6 hours from stroke onset, though 12 or more hours in suspected basilar artery occlusion). It is estimated that the likelihood of a good outcome decreases by 10% for every 30-minute delay in recanalization from embolectomy, making efficient diagnosis and management critical. Computed tomographic angiography (CTA) can rapidly and accurately demonstrate the presence of an occlusion, and should be part of the minimum imaging workup for suspected stroke patients. A national study in 2015, led by members of our neurovascular team, identified several elements that are required to achieve timely revascularization in LVO patients.[7] Expanding upon these findings, our Comprehensive Stroke Center (CSC) developed a standardized practice to decrease procedure times and initiated a protocol for LVO patients who first presented to an outside primary stroke center (PSC) to facilitate quick treatment (**Figure 2**).[8] This method was designed to minimize waiting times for suspected LVO patients, getting them closer to intervention as soon as possible. Initial results demonstrate that when fully executed, median time from PSC arrival to CSC intervention was reduced from 151 to 111 minutes ($p<0.0001$). This protocol also made patients twice as likely to have a favorable outcome (50% vs. 25%). Evidence

Figure 1. A) AP view of left ICA angiogram demonstrating MCA occlusion (arrow).
B) AP view of left ICA post-embolectomy angiogram showing recanalization of MCA (arrow)

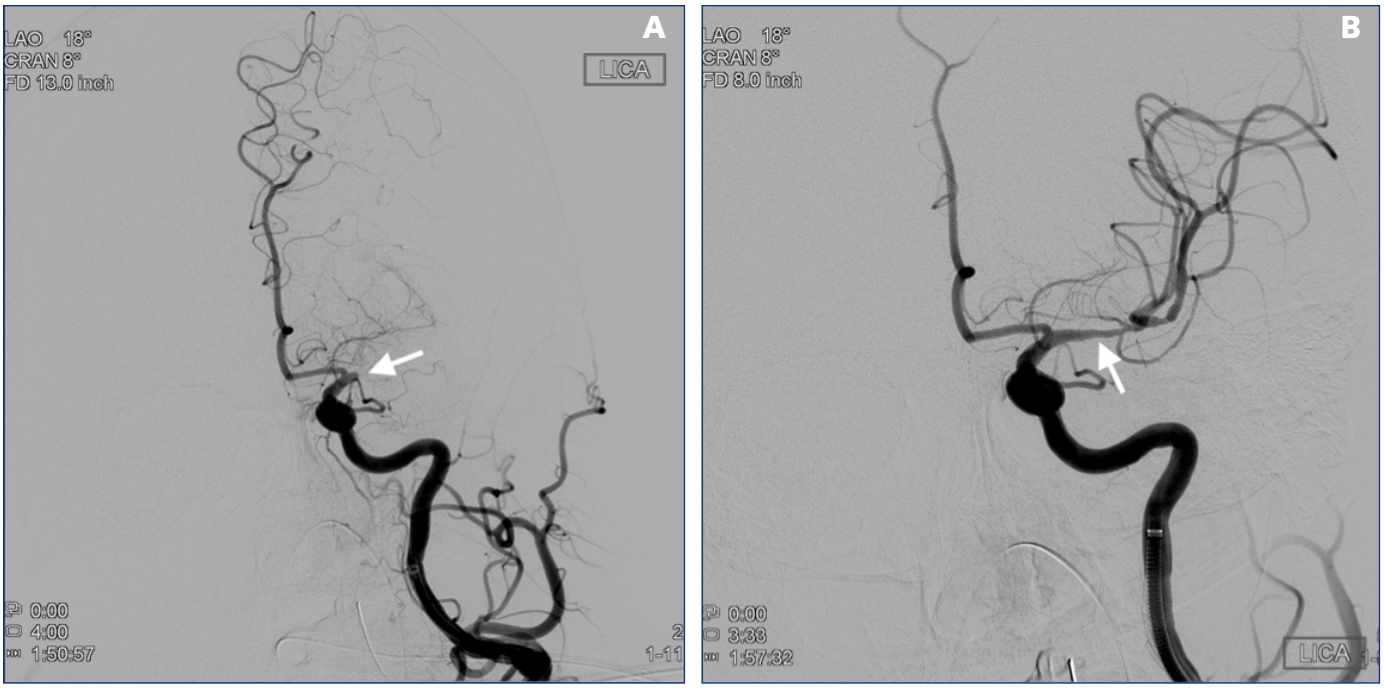

Figure 2. Protocol to expedite time to embolectomy

Outside hospitals (PSC) notify the CSC immediately upon patient arrival
Obtain a CTA in addition to non-contrast CT in all patients with suspected LVO, although this should not delay IV-tPA administration
Share imaging with CSC using a secure cloud-based platform
Activation of the neurointerventional surgical team as soon as possible based on LVO confirmation or clinical stroke severity
Additional imaging techniques, particularly those intended to physiologically select patients for embolectomy, may provide additional value but should not delay the procedure
Avoidance of routine general anesthesia during intervention

strongly supports that prompt evaluation and treatment of stroke patients with documented LVO in centers capable of performing embolectomy is crucial to obtaining optimal clinical outcomes.

DECOMPRESSIVE HEMICRANIECTOMY

Despite acute interventions such as IV-tPA and embolectomy, up to 10% of ischemic strokes result in large areas of infarction. This can lead to significant brain swelling, raised intracranial pressure (ICP), and in severe cases, life-threatening herniation syndromes. These conditions are associated with worse outcomes, as they promote further reductions in cerebral blood flow leading to additional ischemic tissue damage (secondary brain injury).

Significant edema that occurs in the supratentorial space after a stroke is referred to as malignant infarction of the middle cerebral artery (MCA).[9] This condition is associated with CT evidence of infarction involving at least 50% of the MCA territory or an infarct volume of greater than 145 cm^3 on diffusion weighted magnetic resonance imaging (MRI). Despite aggressive medical management including hyperventilation, barbiturates, hyperosmolar therapy, and corticosteroids, malignant MCA infarctions have been associated with an 80% fatality rate. However, recent multi-center trials and pooled analyses strongly support the role of surgical intervention, consisting of a decompressive hemicraniectomy (DHC), in reducing mortality and disability after malignant MCA infarction in select patients.[9,10] The surgical procedure involves removal of a large bone flap, followed by insertion of a dural patch. This results in reduced constriction of the injured brain and culminates in lower ICP and reduced risk of brain herniation.

Three European prospective, multi-center, randomized controlled trials have investigated the benefit of DHC versus medical treatment in patients with space-occupying hemispheric strokes and altered level of consciousness.[9,10,11] The DESTINY trial enrolled patients, between 18 and 60 years of age, within 36 hours of stroke onset. The trial was terminated per the study protocol when statistical significance was reached for reduction in 30-day mortality in the surgical arm (88% of patients randomized to DHC versus

47% receiving conservative therapy survived after 30 days). DECIMAL randomized 38 patients, 18–55 years old, within 24 hours of stroke onset. There was a 52.8% absolute reduction in death in the surgical cohort. Lastly, the HAMLET trial included 64 patients between 18 and 60 years of age treated within 96 hours of symptom onset and found that DHC reduced case fatality by 38%. A pooled analysis of 94 patients from all three trials demonstrated a significant increase in favorable outcome in the DHC cohort.[11] However, there was no statistically significant evidence in any individual trial regarding improved functional outcomes for patients undergoing DHC.

Current evidence suggests a role for DHC in patients younger than 60 with malignant infarction of the MCA associated with altered consciousness who are treated within 48 hours of stroke onset. For patients older than 60, surgical decompression is controversial. There are notable improvements in mortality, but many of the surviving patients have severe disability.[12]

CAROTID ENDARTERECTOMY AND CAROTID STENTING

Carotid artery stenosis causes up to 10% of all ischemic strokes. The risk of recurrent stroke is significantly higher in patients who have previously suffered an initial stroke or transient ischemic attack (TIA). It is estimated that 25% of patients presenting with a stroke are suffering from a recurrent ischemic episode. The risk of stroke is particularly high in symptomatic patients who have severe narrowing of the extracranial internal carotid artery, and several large randomized studies have demonstrated the effectiveness of carotid endarterectomy (CEA) in reducing future stroke risk in these patients. The North American Symptomatic Carotid Endarterectomy Trial (NASCET) reported that in symptomatic patients with greater than 70% carotid stenosis who undergo CEA, the absolute risk of future stroke is reduced by 17% compared to medical therapy alone[13], which has been confirmed by other large studies.[14] Pooled analysis of three large trials of CEA versus medical therapy has shown a 16% absolute risk reduction when CEA was performed in patients with symptomatic stenosis of 70% or more.[15] For patients with 50–69% stenosis, there was still a benefit but to a lesser degree. Patients with less than 50% narrowing of the carotid artery do not appear to benefit from surgical intervention.

Despite the proven effectiveness of CEA, carotid artery stenting (CAS) has been promoted as an attractive, less invasive option for revascularization. Potential advantages of CAS include decreased patient discomfort and a shorter recuperation period. Early studies indicated a higher procedural risk during CAS compared to CEA, but these studies have been criticized for inadequate and non-uniform operator experience.[16] Furthermore, advances in endovascular techniques and devices used for CAS have made the procedure safer.

The largest trial to date, the Carotid Revascularization Endarterectomy versus Stent Trial (CREST) was a prospective, randomized trial of 2,502 patients comparing the efficacy of CAS with CEA.[17] The primary endpoint was the composite of any stroke, myocardial infarction, or death during the periprocedural period and ipsilateral stroke within 4 years thereafter. The study found that CAS and CEA had similar outcomes, although there were varying complications with each intervention. The rate of any periprocedural stroke or post-procedural ipsilateral stroke within 30 days was significantly higher in the CAS group than in the CEA group (5.5% versus 3.2%). However, the rate of myocardial infarction was higher in the CEA group (2.3% versus 1.0%). Overall, the CREST study demonstrated that CAS and CEA had similar short- and long-term outcomes. Carotid artery stenting may prove especially useful in cases of surgically inaccessible lesions, radiation-induced stenosis, or and in patients with severe cardiac or pulmonary disease.

To date, studies have shown that surgical interventions aimed at preventing stroke in patients who have already suffered a stroke or TIA from extracranial carotid stenosis have proven more effective than medical treatment alone. However, previous studies did not include optimal medical therapies such as statins. As advances in the medical treatment of stroke continue, it is imperative to compare these with both CEA and CAS. The CREST 2 trial currently underway attempts to compare current best medical therapy versus CEA and CAS.

EXTRACRANIAL TO INTRACRANIAL ARTERIAL BYPASS

Extracranial-intracranial (ECIC) bypass surgery has not been shown to provide any benefit for patients with atherosclerotic carotid occlusion or carotid artery narrowing distal to the carotid bifurcation. However, in patients with moyamoya disease or syndrome, ECIC bypass has been shown to be effective at reducing stroke risk.

Moyamoya can occur in children and adults and is a cerebrovascular condition that predisposes affected patients to stroke due to progressive stenosis of the intracranial internal carotid arteries and their branches (**Figure 3a**). Genetic factors play a role, and moyamoya can be associated with other conditions such as Down's syndrome, sickle cell disease, neurofibromatosis, or previous cranial irradiation. If the disease is unilateral, or is associated with one of these conditions, it is called moyamoya syndrome. Moyamoya disease is bilateral and is not associated with other risk factors. Most patients present with stroke or ischemic symptoms with 50–75% of known moyamoya patients experiencing ischemic stroke.[18]

It has been estimated that up to two-thirds of patients

Figure 3. A) Lateral left ICA angiogram in a patient with moyamoya disease. The MCA is occluded and there is poor angiographic filling in the MCA territory. Small collateral vessels develop at the ICA terminus (arrow).
B) Lateral left ICA angiogram in a patient who underwent a STA-MCA bypass for the treatment of moyamoya disease.

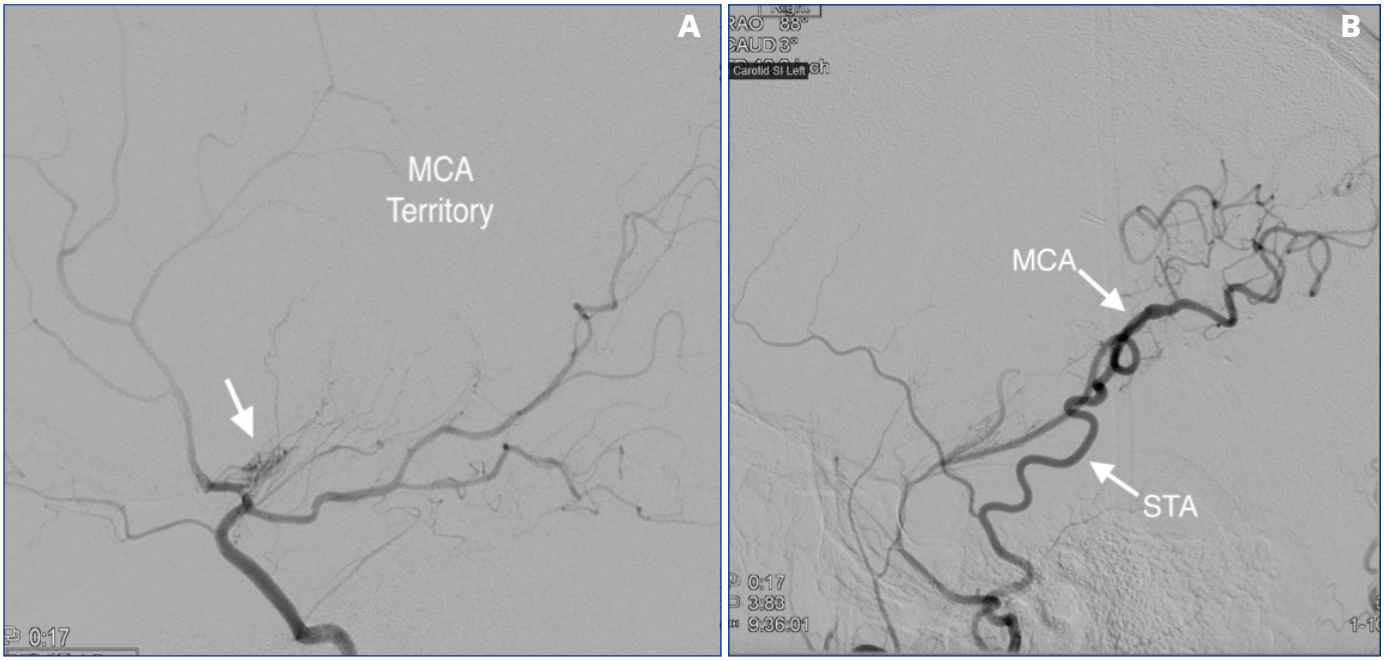

with moyamoya have symptomatic progression over a 5-year period with poor outcomes without treatment. Medical therapies have not been shown to be beneficial in reducing stroke risk and surgical revascularization (ECIC bypass) is the primary treatment for moyamoya. This procedure utilizes extracranial arterial supply (usually the superficial temporal artery) which is either directly or indirectly anastomosed to an intracranial cortical artery (**Figure 3b**). Following ECIC bypass, there is a 96% probability of remaining stroke-free over the subsequent 5 years, and a meta-analysis concluded that 1003 of 1156 patients (87%) derived symptomatic benefit from surgical revascularization.[19]

FUTURE DIRECTIONS

Time to treatment is a critical factor in improving outcomes in acute stroke, and the development of additional strategies to decrease time to intervention are warranted. Field triage based on clinical severity to a Comprehensive Stroke Center can help decrease time to treatment. Perhaps the ultimate solution, Mobile stroke ambulances (composed of trained medical personnel, a CT scanner, and telecommunications) can allow ultra-rapid patient assessment, in-field administration of IV-tPA, and rapid transport to a dedicated neurovascular center. Only a few units currently exist, but preliminary reports show improvement in treatment times and clinical outcomes.

The precise time window for acute embolectomy has not been fully evaluated. A select group of patients, with defined areas of reversible ischemia, may benefit from recanalization outside of the current time recommendations. Further refinement of patient selection using advanced CT or MR based imaging will likely allow us to offer treatment to a greater group of patients. In addition, as endovascular technologies continue to improve, treatment of non-LVO stroke patients with occlusion in smaller, more distal vessels may benefit from embolectomy.

Despite treatment, many stroke patients have permanent neurologic deficits such as hemiplegia, aphasia, or visual loss. Surgical techniques to restore function are needed. Stem cell transplantation, neuromodulation and cortical stimulation techniques, and brain-computer interface technologies have potential to improve neurorestoration and warrant future investigation.

References

1. Mozaffarian D, Benjamin EJ, Go AS, et al. Executive summary: heart disease and stroke statistics—2015 update: a report from the American Heart Association. Circulation 2015;131:434–41.
2. Centers for Disease Control and Prevention (CDC). Leading causes of death. http:// www.cdc.gov/nchs/fastats/leading-causes-of-death.htm (accessed 20 Feb 2015).
3. Saver JL. Time is brain—quantified. Stroke 2006;37:263-266.
4. Smith WS, Lev MH, English JD, et al. Significance of large vessel intracranial occlusion causing acute ischemic stroke and TIA. Stroke 2009;40:3834-3840.
5. Chen CJ, Ding D, Starke RM, et al. Endovascular vs medical management of acute ischemic stroke. Neurology 2015;85:1980-1990.
6. Badhiwala JH, Nassiri F, Alhazzani W, et al. Endovascular thrombectomy for acute ischemic stroke: A meta-analysis. JAMA 2015;314:1832-1843.

7. McTaggart RA, Ansari SA, Goyal M, et al. Initial hospital management of patients with emergent large vessel occlusion (ELVO): report of the standards and guidelines committee of the Society of NeuroInterventional Surgery. J Neurointerv Surg. 2015; 0:1-9.
8. McTaggart RA, Yaghi S, Baird G, Haas RA, Jayaraman MV. Decreasing procedure times with a standardized approach to ELVO cases. *JNIS*. 2017;9(1):2-5.
9. Vahedi K, Vicaut E, Mateo J, Kurtz A, Orabi M, Guichard J, Boutron C, Courvreur G, Rouanet F, Touzé E, Guillon B, Carpentier A, Yelnik A, George B, Payen D, Bousser M. Sequential-design, multicenter, randomized, controlled trial of early decompressive craniectomy in malignant middle cerebral artery infarction (DECIMAL trial). *Stroke* 2007; 38(9): 2506-17.
10. Hofmeijer J, Kapelle LJ, Algra A, Amelink GJ, van Gijn J, van der Worp HB. Surgical decompression for space-occupying cerebral infarction (the hemicraniectomy after middle cerebral artery infarction with life-threatening edema trial [HAMLET]): a multicenter, open, randomized trial. *Lancet Neurology* 2009; 8(4): 326-33.
11. Vahedi, Katayoun, et al. "Early decompressive surgery in malignant infarction of the middle cerebral artery: a pooled analysis of three randomized controlled trials." *The Lancet Neurology* 6.3 (2007): 215-222.
12. Jüttler E, Unterberg A, Woitzik J, Bösel J, Amiri H, Sakowitz OW, Gondan M, Schiller P, Limprecht R, Luntz S, Schneider J, Pinzer T, Jobohm C, Meixensberger J, Hacke W. Hemicraniectomy in older patients with extensive middle cerebral artery stroke. *The New England Journal of Medicine* 2014; 370(12): 1091-1100.
13. North American Symptomatic Carotid Endarterectomy Trial Collaborators. Beneficial effect of carotid endarterectomy in symptomatic patients with high-grade carotid stenosis. N Engl J Med 1991; 325:445.
14. MRC European Carotid Surgery Trial: interim results for symptomatic patients with severe (70-99%) or with mild (0-29%) carotid stenosis. European Carotid Surgery Trialists' Collaborative Group. Lancet 1991; 337:1235.
15. Rothwell PM, Eliasziw M, Gutnikov SA, et al. Analysis of pooled data from the randomised controlled trials of endarterectomy for symptomatic carotid stenosis. Lancet 2003; 361:107.
16. Bonati LH, Lyrer P, Ederle J, et al. Percutaneous transluminal balloon angioplasty and stenting for carotid artery stenosis. Cochrane Database Syst Rev 2012; :CD000515.
17. Mantese VA, Timaran CH, Chiu D, Begg RJ, Brott TG; CREST Investigators. The Carotid Revascularization Endarterectomy versus Stenting Trial (CREST): stenting versus carotid endarterectomy for carotid disease. Stroke. 2010 Oct;41(10 Suppl):S31-4.
18. Scott RM, Smith ER: Moyamoya Disease and Moyamoya Syndrome. N Engl J Med 2009;360:1226-37.
19. Fung LW, Thompson D, Ganesan V. Revascularization surgery for paediatric moyamoya: a review of the literature. Childs Nerv Syst 2005;21:358-64.

Authors

Cody A. Doberstein, BS, Department of Neurosurgery, Warren Alpert Medical School of Brown University, Providence, RI.

Radmehr Torabi, MD, Department of Neurosurgery, Warren Alpert Medical School of Brown University, Providence, RI.

Sandra C. Yan, BS, BA, Warren Alpert Medical School of Brown University, Providence, RI.

Ryan McTaggart, MD, Associate Professor, Departments of Diagnostic Imaging, Neurology and Neurosurgery, Warren Alpert Medical School of Brown University, Providence, RI.

Curtis Doberstein, MD, Professor (Clinical), Department of Neurosurgery, Warren Alpert Medical School of Brown University, Providence, RI.

Mahesh Jayaraman, MD, Associate Professor, Departments of Diagnostic Imaging, Neurology and Neurosurgery, Warren Alpert Medical School of Brown University, Providence, RI.

Correspondence

Curtis Doberstein, MD
Department of Neurosurgery
Rhode Island Hospital
593 Eddy Street, APC 6th Floor
Providence, Rhode Island 02903
401-793-9169
Fax: 401-444-2761
cdoberstein@lifespan.org