Encapsulating Peritoneal Sclerosis: Imitator of Common Abdominal Disorders

MATTHEW J. HAGAN, BS, MD'22; MUHAMMAD T. SHAKOOR, MD

KEYWORDS: encapsulating sclerosing peritonitis, peritoneal dialysis, hemodialysis, tamoxifen

INTRODUCTION

Encapsulating peritoneal sclerosis (EPS) is a rare but catastrophic complication of long-term peritoneal dialysis (PD) and is associated with frequent small bowel obstruction, malnutrition, with significant morbidity and mortality.[1] It is characterized by extensive fibro-collagenous changes in the peritoneal membrane, leading to formation of a fibrous cocoon encapsulating the bowel.[2]

CASE PRESENTATION

A 45-year-old male with a history of end-stage renal disease on PD for 10 years, and a recent admission for culture negative peritonitis, presented to the emergency department with four days of dizziness, diarrhea, poor oral intake, and diffuse abdominal pain. He reported cloudy peritoneal fluid during PD exchanges. Physical exam-vital signs were within normal limits; abdominal exam was notable for left lower quadrant tenderness, no masses or organomegaly, and no signs of peritoneal irritation. Peritoneal fluid analysis revealed a total cell count of 2,519/mm^3 with 98% polymorphonuclear leukocytes; intraperitoneal vancomycin and cefepime were initiated. Oral vancomycin for *Clostridioides difficile* colitis was begun following a positive PCR for the bacterium.

Despite down trending of the peritoneal fluid cell count and persistent negative cultures, his generalized abdominal pain continued. A Computed Tomography (CT) scan of the abdomen and pelvis showed diffuse thickening and enhancement of peritoneal membranes along with moderate ascites. Thickening of the sigmoid colon and rectum was also noted with extensive areas of calcified loops of distal small bowel (**Figure 1**). Subsequently, repeat peritoneal fluid analysis showed an increased total fluid cell count = 1,564/mm.[3] Repeat CBC also showed an increased peripheral WBC = 16,000 per microliter. Based on the imaging and laboratory findings, EPS and refractory peritonitis were suspected. The PD catheter was removed and the patient was switched to hemodialysis. He underwent a diagnostic exploratory laparotomy. Biopsy revealed thickened, fibrin-encased abdominal structures throughout the peritoneum and filmy adhesions confirming the diagnosis of EPS (**Figure 2**). He also had elevated fungal biomarkers serum beta-d-glucan and galactomannan levels in the peritoneal fluid and was started on Amphotericin B for suspicion of a fungal peritonitis. He was also started on tamoxifen. Steroids were held given the concern for fungal peritonitis. Tamoxifen was stopped after a week

Figure 1. Axial and sagittal contrast-enhanced CT. Extensive, mixed-attenuating ascites with peritoneal thickening and enhancement (arrows). The bowel does not float dependently within ascites, but is instead pushed posteriorly.

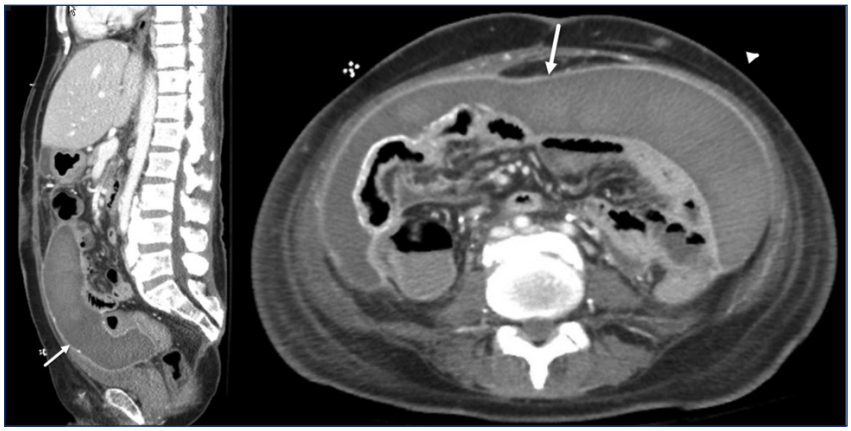

Figure 2. Peritoneal membrane biopsy with dense acute and chronic inflammation, necrosis, fibrin deposition.

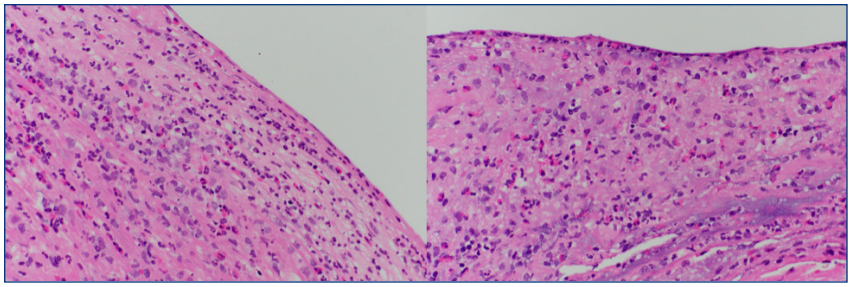

as he was not tolerating oral intake. He did not improve. Subsequently, paracentesis revealed grossly hemorrhagic, purulent fluid with an increasing total fluid cell count = 46,048/mm.[3] Eventually, he was unable to tolerate hemodialysis due to hemodynamic instability and was transitioned to comfort measures only.

DISCUSSION

EPS is a rare complication of PD with a reported incidence of 0.3 to 3.3%.[2] The pathogenesis of EPS remains poorly understood. It is believed that the disease is a result of peritoneal inflammation leading to hyperplasia of peritoneal mesothelial cells.[3] Risk factors for EPS include long-term PD with toxic, high dextrose-based dialysate. Less common causes include medications, solid organ transplantation, endometriosis, systemic inflammatory diseases, and recurrent peritonitis.[2,4,5] Johnson and colleagues, in a matched case-control analysis, observed that duration of PD independently predicted EPS.[2]

EPS most commonly presents with abdominal pain, vomiting, anorexia, ascites and bowel obstruction.[4] While there are no specific laboratory findings that confirm EPS, early in the disease course, there is often a decrease in ultrafiltration as measured by serial peritoneal equilibration tests.[6]

The non-specific symptoms of EPS, coupled with laboratory data mimicking more common abdominal disorders, commonly lead to a delay in diagnosis and treatment. Treatment includes steroids, tamoxifen and nutritional support,[3] and eliminating the triggering factor - PD in our case. While previously contraindicated in patients with EPS, surgical management is now utilized in selected cases of bowel obstruction.[7]

CONCLUSION

Patients with EPS often develop mechanical small bowel obstruction due to their increased risk for adhesive disease. Unexplained abdominal complaints in patients on long-term PD should lead to consideration of EPS. Early suspicion and prompt diagnosis may reduce the risk of catastrophic consequences.

References

1. Kawanishi H, Shintaku S, Banshodani M, Hashimoto S. Past and present perspectives on encapsulating peritoneal sclerosis. Contrib Nephrol. 2015;185:87-97.
2. Johnson DW, Cho Y, Livingston BE, Hawley CM, McDonald SP, Brown FG, Rosman JB, Bannister KM, Wiggins KJ. Encapsulating peritoneal sclerosis: incidence, predictors, and outcomes. Kidney Int. 2010 May;77(10):904-12.
3. Jagirdar RM, Bozikas A, Zarogiannis SG, Bartosova M, Schmitt CP, Liakopoulos V. Encapsulating Peritoneal Sclerosis: Pathophysiology and Current Treatment Options. Int J Mol Sci. 2019 Nov 16;20(22):5765.
4. Brown MC, Simpson K, Kerssens JJ, Mactier RA; Scottish Renal Registry. Encapsulating peritoneal sclerosis in the new millennium: a national cohort study. Clin J Am Soc Nephrol. 2009 Jul;4(7):1222-9.
5. Korte MR, Yo M, Betjes MG, Fieren MW, van Saase JC, Boer WH, Weimar W, Zietse R. Increasing incidence of severe encapsulating peritoneal sclerosis after kidney transplantation. Nephrol Dial Transplant. 2007 Aug;22(8):2412-4.
6. Brown EA, Bargman J, van Biesen W, Chang MY, Finkelstein FO, Hurst H, Johnson DW, Kawanishi H, Lambie M, de Moraes TP, Morelle J, Woodrow G. Length of Time on Peritoneal Dialysis and Encapsulating Peritoneal Sclerosis - Position Paper for ISPD: 2017 Update. Perit Dial Int. 2017 Jul-Aug;37(4):362-374.
7. Kawanishi H, Banshodani M, Yamashita M, Shintaku S, Dohi K. Surgical Treatment for Encapsulating Peritoneal Sclerosis: 24 Years' Experience. *Perit Dial Int*. 2019;39(2):169-174.

Acknowledgments

The authors would like to thank Yiru Wu, MD, and David Grand, MD, for their contributions to figure preparation.

Authors

Matthew J. Hagan, BS, MD'22, The Warren Alpert Medical School of Brown University, Providence, RI.

Muhammad T. Shakoor, MD, Department of Nephrology, Rhode Island Hospital; The Warren Alpert Medical School of Brown University, Providence, RI.

Financial Disclosures

None

Correspondence

Matthew J. Hagan
Warren Alpert Medical School of Brown University
222 Richmond Street
Providence, RI 02903
matthew_hagan@brown.edu