Chronic Hypotension Due to Thrombosis of an Inferior Vena Cava Filter

SHAFFIN SIDDIQUI; MOHAMMAD SAUD KHAN, MD; ABDELMONIEM MOUSTAFA, MD;
VIJAIRAM SELVARAJ, MD; MOHD AMER ALSAMMAN, MD

ABSTRACT

Inferior vena cava filters (IVCF) are associated with many long-term complications. Often, these complications manifest as acute events, such as shock. However, we report a case of a patient who presented with chronic hypotension and dizziness due to a thrombosed IVCF filter.

KEYWORDS: THRO (Thrombectomy), VCF (Vena Cava Filter), CS (Shock, Cardiogenic), FBR (Foreign Body Retrieval), PE (Pulmonary Embolism), VC (Vena Cava)

BACKGROUND

Inferior vena cava filters (IVCF) are often used in conjunction with or as a substitute to anticoagulation therapy in patients with venous thromboembolism (VTE), aimed at preventing pulmonary embolism (PE). These filters are either permeant or retrievable, but few filters are retrieved from patients following implantation, increasing the likelihood of long-term complications, including thrombosis of the filter.[1] Most IVCF thrombosis cases are asymptomatic or accompanied by a severely acute presentation. We describe a patient who had an IVCF placed 15 years prior and presented with chronic hypotension and dizziness secondary to IVC obstruction due to a thrombosed filter.

CASE PRESENTATION

A 46-year-old male with a history of Hodgkin's Lymphoma (in remission), antiphospholipid antibody syndrome with multiple deep venous thromboses (DVT) and PE in the past, and chronic kidney disease stage III presented with complaints of dizziness and lightheadedness. He underwent IVCF placement 15 years prior (in 2005) after suffering multiple spine injuries from a motor vehicle accident. The patient reported little to no follow-up following his filter placement and questionable compliance to anticoagulation therapy. He reported symptoms of dizziness and lightheadedness with minimal exertion for several months, which had gotten progressively worse for the past 3 weeks. He also reported worsening chronic lower extremity edema for the past 2 weeks.

On presentation, he was found to be hypotensive with a blood pressure of 85/55 mmHg, heart rate of 85 beats per minute, respiratory rate of 16 per minute, and oxygen saturation of 100% on room air. Orthostatic vital signs were remarkable for a drop of blood pressure to 70/35 mmHg, and an increase in the heart rate to 112 beats per minute, with significant dizziness. Cardiopulmonary examination revealed normal S1 and S2 without any murmur and clear bilateral lung fields. The abdominal examination was unremarkable. Extremities showed bilateral 2+ pitting edema extending up to the mid-calf. Initial laboratory work-up was unremarkable with hemoglobin of 14 g/dl, white blood count of 5600 cells/mm^3, platelets of 400,000 cells/mm^3, creatinine of 1.35 mg/dl (baseline), blood urea nitrogen of 13 mg/dl, and normal electrolytes. Whole blood lactate was normal at 1.1 mEq/L.

He received fluid boluses (2.5L normal saline) with no significant improvement in blood pressure. Cardiogenic, septic, and endocrine etiologies of hypotension and shock were considered, and relevant laboratory and imaging workup was initiated. The liver function panel and urinalysis were unremarkable. TSH was 3.63 uIU/ml, ACTH was 16 pg/ml, morning cortisol was 13.2 ug/dL, and cosyntropin stimulation test was normal. Blood culture and urine culture remained negative. Chest X-ray showed normal bilateral lung fields, and no infiltrates. A venous duplex scan of bilateral lower extremities did not show evidence of acute DVT. An echocardiogram showed normal systolic and diastolic ventricular function and no significant valvular abnormalities. Broad-spectrum antibiotics, which were initially started for suspicion of septic shock, were discontinued. Midodrine and fludrocortisone were also initiated. However, no significant improvement in blood pressure was noted. Subsequently, a computed tomography (CT) scan of the abdomen and pelvis was performed, which did not show a source of infection or bleeding. However, it revealed an occluded IVCF (**Figure 1**) and extensive pelvic and lumbar collateral vessels (**Figure 2**).

Based on these imaging findings and no other identifiable explanation of hypotension, we hypothesized a decreased cardiac preload from a chronically occluded ilio-caval system from a thrombosed IVCF to be the reason for the patient's hypotension and symptoms. Interventional radiology and vascular surgery teams were consulted. The IVCF was retrieved, and the IVC and bilateral common iliac veins were reconstructed. Covered stents were placed to block collateral venous flow. Following the procedure, the patient's

Figure 1. Computed tomography of abdomen and pelvis (axial and coronal scans) showing thrombosed inferior vena cava filter (arrow).

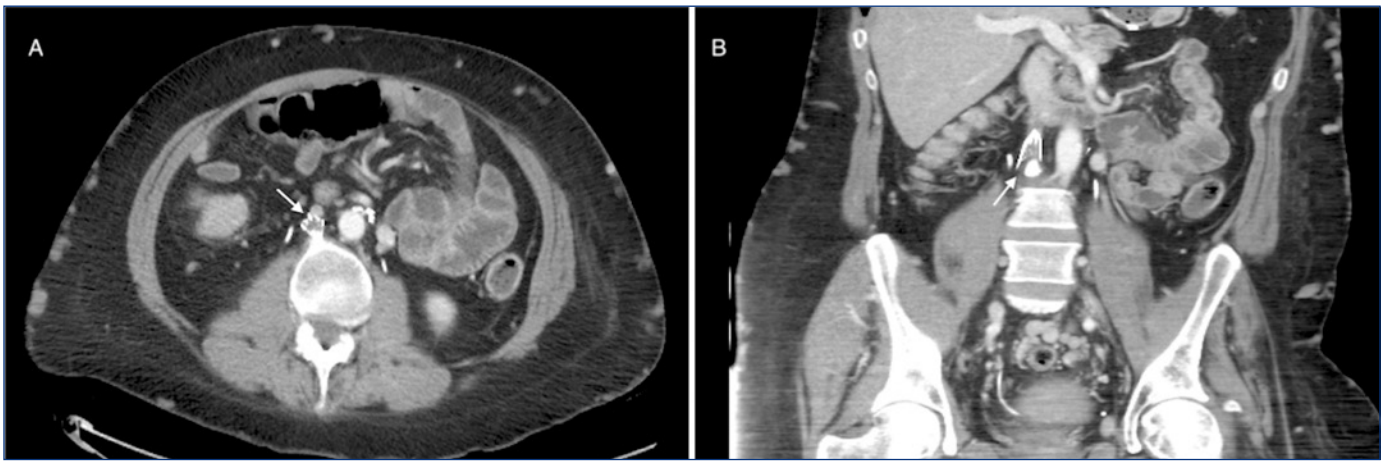

Figure 2. Computed tomography of abdomen and pelvis (axial and coronal scans) showing extensive collateral vessels in pelvis (arrow).

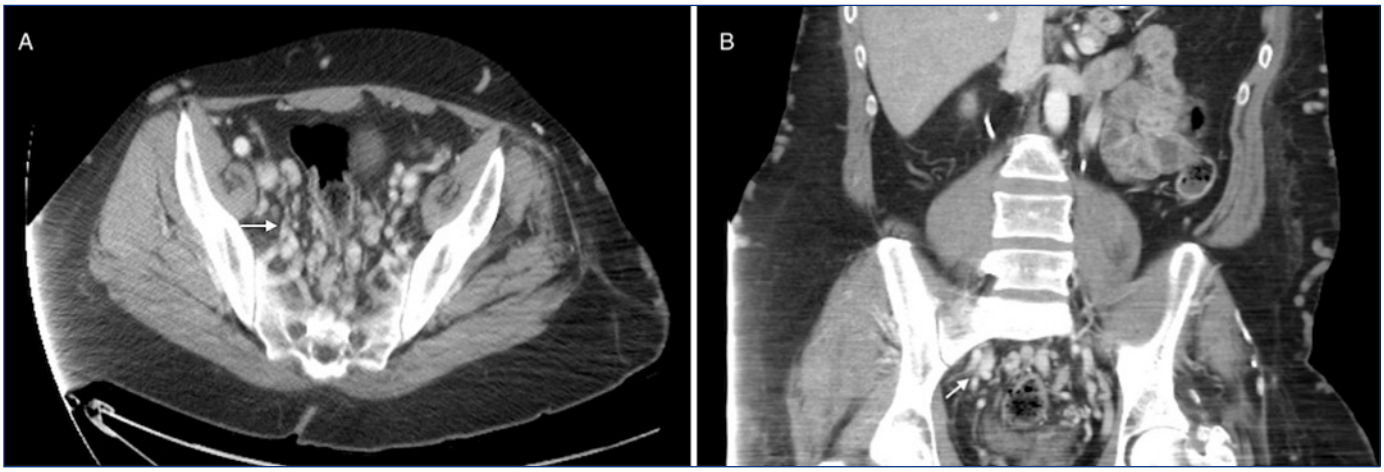

blood pressure improved with systolic blood pressure ranging between 95–115 mmHg and diastolic blood pressure ranging from 65–90 mmHg. The patient also reported significant improvement in orthostasis and dizziness and improvement in bilateral lower extremity edema.

DISCUSSION

This case represents an unusual cause of refractory hypotension with dizziness. Given the improvement following the retrieval of the IVCF and venous reconstruction, the patient's hypotension was likely due to decreased cardiac preload, secondary to IVC occlusion, due to thrombosis of a long-standing IVCF. The blockage likely developed slowly over time, with development of venous collaterals. Symptoms were gradual and chronic, unlike previous reports, where hypotension secondary to thrombosed IVCF is associated with a more acute presentation.[2,3] Clots may have collected in situ or migrated from the lower extremity and lodged in the filter, occluding the ICV over time. Clinicians, when presented with cases of hypotension or shock, should be alerted to the possibility of obstruction of pre-existing IVCF.

This case illustrates one of the risks associated with ICVF placement and the necessity for follow-up. Indeed, IVCF use has risen remarkably in recent years.[4] In general, IVCF placement is indicated for increased risk of PE in patients for whom anticoagulation is contraindicated or in whom anticoagulation alone is felt to be insufficient to prevent PE. Remarkably, however, little data support the efficacy and safety of IVCFs, despite their prolific use. Of the few randomized trials conducted, the PREPIC study divided patients with proximal DVT and PE risk into two cohorts, one group receiving anticoagulation alone and another a permeant IVCF with anticoagulation. The study found only a small reduction in symptomatic and asymptomatic PE at the 12-day mark but an increased rate of recurrent DVT amongst the filter group across an 8-year follow-up.[5] Moreover, long-term complications associated with IVCFs (e.g., filter migration, thrombosis, and perforation) make their prompt removal after placement even more critical.

However, only a small proportion of retrievable filters associated with greater complication rates than permanent ones are removed.[1] Indeed, clinical practice guidelines issued by the American College of Radiology (ACR), American College of Chest Physicians (ACCP), and European Society of Cardiology (ESC), all recommend against IVCF placement unless there is a contraindication to anticoagulation therapy or recurrent PE despite anticoagulation therapy.[6] As such, clinicians should balance the risks of ICVF placement and ensure rigorous follow-up and a timeline for retrieval. In our patient, more attentive follow-up following IVCF placement might have averted this complication.

CONCLUSION

In conclusion, IVCFs, even when correctly positioned, are well known for their long-term complications. However, the above presentation of chronic hypotension and dizziness secondary to IVC obstruction due to thrombosis of an IVCF is a rare and clinically notable occurrence – this being the first report, to our knowledge, in the literature. As such, our case reinforces the risks associated with IVCF placement. Indeed, they should be used as a last resort with very close follow-up and a punctual plan for retrieval.

References

1. Geerts W, Selby R. Inferior vena cava filter use and patient safety: legacy or science? *Hematology Am Soc Hematol Educ Program.* 2017;686-692. DOI: 10.1182/asheducation-2017.1.686.
2. Mohammed M, Elhamdani S, Abusnina W, et al. Inferior Vena Cava Obstruction and Shock. *J Emerg Trauma Shock.* 2018;11:146-148. DOI: 10.4103/JETS.JETS_22_17.
3. Shem K. Phlegmasia cerulea dolens: rare complication of vena cava filter placement in man with paraplegia. *J Spinal Cord Med.* 2008;31:398-402. DOI: 10.1080/10790268.2008.11760743.
4. Angel LF, Tapson V, Galgon RE, et al. Systematic review of the use of retrievable inferior vena cava filters. *J Vasc Interv Radiol.* 2011;22:1522-1530 e1523. DOI: 10.1016/j.jvir.2011.08.024.
5. Group PS. Eight-year follow-up of patients with permanent vena cava filters in the prevention of pulmonary embolism: the PREPIC (Prevention du Risque d'Embolie Pulmonaire par Interruption Cave) randomized study. *Circulation.* 2005;112:416-422. DOI: 10.1161/CIRCULATIONAHA.104.512834.
6. DeYoung E, Minocha J. Inferior Vena Cava Filters: Guidelines, Best Practice, and Expanding Indications. *Semin Intervent Radiol.* 2016;33:65-70. DOI: 10.1055/s-0036-1581088.

Authors

Shaffin Siddiqui, Princeton University, New Jersey.

Mohammad Saud Khan, MD, Division of Medicine, The Miriam Hospital, and Warren Alpert School of Brown University, Providence, RI.

Abdelmoniem Moustafa, MD, Division of Medicine, The Miriam Hospital, and Warren Alpert School of Brown University, Providence, RI.

Vijairam Selvaraj, MD, MPH, Division of Medicine, The Miriam Hospital, and Warren Alpert School of Brown University, Providence, RI.

Mohd Amer Alsamman, MD, Division of Medicine, The Miriam Hospital, and Warren Alpert School of Brown University, Providence, RI.

Disclosures

Authors' Note: Informed consent has been obtained from the patient for publication of the case report.

Conflicts of Interests: The authors have no conflicts of interest to declare.

Funding Statement: There were no external funders involved in the production of this case report.

Correspondence

Vijairam Selvaraj, MD, MPH
The Miriam Hospital
164 Summit Avenue
Providence, RI 02906
Vijairam.selvaraj@lifespan.org