

Blast from the Past: Acute Myeloid Leukemia Presenting with Cardiac Tamponade

JESSICA M. GONZALEZ, MD; GABRIEL LOWENHAAR, MD; ANSHUL PARULKAR, MD; ARI PELCOVITS, MD

ABSTRACT

Acute Myeloid Leukemia (AML) is a life-threatening illness that requires prompt diagnosis and often immediate treatment. It can present in a variety of manners but most commonly is associated with fevers, fatigue, shortness of breath, or infection. Extramedullary leukemia is a less common finding upon initial presentation, but includes dermatologic manifestations, including leukemia cutis, and rarely, large mass-like presentations known as myeloid sarcomas. While leukemic infiltration of organ systems is a well-described phenomenon, cardiac tamponade is a rare form of presentation. Herein we describe a 58-year-old man with a recent hospitalization for idiopathic cardiac tamponade who re-presented to the hospital with worsening dyspnea and fevers. He was found to have a recurrent pericardial effusion with features concerning for tamponade, as well as worsening thrombocytopenia and macrocytic anemia. Bone marrow biopsy revealed 24% myeloblasts, confirming the diagnosis of AML. Notably, his cardiac symptoms improved with treatment of his leukemia. To our knowledge, this is one of only a few cases of AML with cardiac tamponade as the initial presentation.

KEYWORDS: AML, Cardiac tamponade, TP53 mutation AML

INTRODUCTION

Acute Myeloid Leukemia (AML) is the most common acute leukemia in adults.^{1,2} The pathophysiology of AML involves the clonal expansion of myeloid progenitor cells, also known as immature blast cells; these blast cells multiply in the blood and bone marrow leading to bone marrow failure.¹ Risk factors for the development of AML include hematologic disorders such as myelodysplastic syndrome, myelofibrosis, and other myeloproliferative neoplasms and aplastic anemia.¹ Smoking, exposure to radiation, and prior chemotherapy are also risk factors.¹ In the US, the incidence is approximately 20,000 cases per year.^{1,2} Clinical manifestations vary but many patients present with signs of bone marrow failure and resulting cytopenias leading to weakness, pallor, shortness of breath, chest tightness, and fatigue.³ Large pericardial effusions occur in less than 0.5%

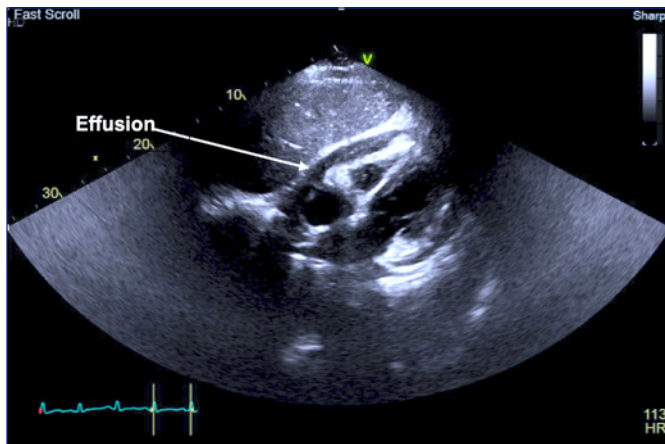
of all patients with AML.⁴ Diagnosis of AML is performed via bone marrow aspiration and biopsy and is confirmed by the presence of greater than 20% blast cells in the peripheral blood or bone marrow, or unique cytogenetic changes on molecular pathology.⁵ Induction therapy, consolidation therapy with chemotherapeutic drugs and stem-cell transplantation are treatment strategies for patients with AML.⁶ Typical induction chemotherapeutic regimens use combinations of cytarabine and anthracycline-based therapy.⁶ Due to the cardiotoxic adverse effects of anthracyclines, baseline evaluation of cardiac function must be performed.⁷

Despite advancements in prognostic markers, treatment outcomes remain poor.¹ Prompt diagnosis and initiation of treatment is of paramount importance, particularly in patients with life-threatening complications due to their leukemia. Cardiac tamponade as the initial presentation of AML is rare and has only been described in a few case reports thus far.⁴ Large effusions causing tamponade have been associated with increased mortality. In patients with atypical presentations, diagnostic strategies allowing for rapid identification and treatment initiation are not well described.

CASE PRESENTATION

A 58-year-old man with a recent hospitalization for cardiac tamponade and subsequent pericardiocentesis with no abnormal cytology presented with worsening dyspnea, fever, and tachycardia. He had been hospitalized approximately a month before for myopericarditis. During that hospitalization he had a pericardiocentesis that had no abnormal immunologic, microscopic, infectious studies, and non-diagnostic flow cytometry. He also had been found to have anemia and thrombocytopenia. He was begun on prednisone and colchicine and discharged with outpatient follow-up. He began experiencing progressive dyspnea and fevers and he returned to the hospital. In the emergency department, a bedside echocardiogram revealed a moderate, circumferential pericardial effusion with thickened pericardium and limited free-flowing fluid. Findings were consistent with pericardial constriction with no overt tamponade physiology (**Figure 1**). However, given his deteriorating clinical status, sampling of the pericardium was deferred, since infectious etiologies were felt to be unlikely as the source of his effusion. It was decided that the risks of a repeat pericardiocentesis outweighed the benefits.

Figure 1. Transthoracic Echocardiogram Subxiphoid view showing moderate, circumferential pericardial effusion.



Laboratory studies revealed worsening thrombocytopenia with a platelet count of 8g/dL and macrocytic anemia 7.7g/dL with MCV 105.7fL, and occasional myeloblasts of 4% were noted on the peripheral smear. He developed tachypnea, tachycardia and hypotension and was treated with cefepime and vancomycin for presumed sepsis. Chest imaging revealed pleural effusions and he subsequently had an unrevealing diagnostic thoracentesis. His dyspnea worsened and he developed acute hypoxic respiratory failure and required a therapeutic thoracentesis followed by rapid improvement of his shortness of breath. In the intensive care unit, he had a bone-marrow biopsy that revealed 24% myeloblasts, confirming the diagnosis of AML. He was found to have a complex karyotype and high VAF TP53 (variant allele frequency tumor suppressor gene) mutation. Given a lack of improvement with antibiotics and no infectious or alternative source identified for his rapid deterioration it was decided to emergently initiate chemotherapy with cytarabine and daunorubicin for treatment of his AML as the presumed cause of his clinical syndrome. The patient's clinical status rapidly improved after initiation of chemotherapy, suggesting a systemic inflammatory response to his underlying leukemia, as the likely etiology of his overall clinical deterioration on presentation, as well as the likely etiology of his pericardial and pleural effusions. He received consolidation therapy with high-dose cytarabine (HIDAC) and completed three cycles. He was evaluated for allogeneic bone marrow transplant (BMT) but had a high risk of relapse because of a TP53 mutation found in his myeloblasts.

A follow-up transthoracic echocardiogram (TTE) was performed a month after his diagnosis and showed preserved systolic function and resolution of his pericardial effusion, suggesting that chemotherapy eliminated the myeloblasts provoking the pericardial effusion. Unfortunately, within a year of his diagnosis, he was hospitalized multiple times and eventually elected hospice care.

DISCUSSION

This patient's presentation illustrates that patients with acute myeloid leukemia may have life-threatening complications and the need for life-saving chemotherapy. His likely pericardial involvement was atypical. Five similar cases in the published literature included four cases in which pericardial fluid cytology showed leukemic cells. Pericardial cytologic evidence of myeloblasts, however, has been found to have variable sensitivity,⁸ with several studies showing the detection of malignancy from pericardial sampling, ranging from 53–92%.^{8–10} Given this and our patient's deteriorating clinical status, pericardiocentesis was not performed during his second admission when he presented with a recurrent pericardial effusion.

Given the uncommon nature of this presentation, specific treatment approaches for leukemic effusions have not been elucidated, and the standard of care remains high-dose induction chemotherapy. Literature review shows patients with similar presentations were initiated on chemotherapy and achieved initial improvements in their clinical status. In two cases, patients were begun on cytarabine and daunorubicin, as in our case.^{4,11} In one of the other cases with negative cytology, the patient was initiated on chemotherapy with decitabine, high-dose corticosteroids and then continued on colchicine for four months. He had improvement of his pericardial effusion following therapy.⁸ Our patient was originally treated with corticosteroids and colchicine prior to the diagnosis of malignancy as mentioned above. The efficacy of using colchicine, corticosteroids, or anti-inflammatory medications for treatment of malignant pericardial effusions was analyzed in a retrospective study.¹² This study showed that use of colchicine reduced the need for further interventions and was associated with overall less mortality. Corticosteroids and anti-inflammatory agents did not show significant benefit.¹² Taking these findings into consideration, colchicine may be an effective agent to consider for patients with malignant effusions. As mentioned in our case presentation, our patient also had resolution of his pericardial effusion following therapy. Besides medical therapy, many of these patients ultimately are evaluated for BMT.^{4,8}

Our patient had a TP53 mutation which only occurs in 10–15% of AML cases.¹³ The presence of this mutation has been associated with the worst AML outcomes.¹³ Unfortunately, the majority of patients with this mutation eventually relapse.¹³ Their median survival rates range between 4–6 months.¹⁴

AML presenting with cardiac tamponade is rare. This case shows the importance of having a high index of suspicion for extramedullary manifestations of AML and the importance of rapidly initiating workup and treatment. Our case also highlights the potential morbidity associated with an associated systemic inflammatory disorder. Patients may require emergent initiation of treatment without determination of a definitive cytologic etiology.

References

1. Shallis RM, Wang R, Davidoff A, et al. Epidemiology of acute myeloid leukemia: Recent progress and enduring challenges. *Blood Rev.* 2019 Jul;36:70-87. doi: 10.1016/j.blre.2019.04.005. Epub 2019 Apr 29. PMID: 31101526.
2. Siegel RL, Miller KD, Jemal A. Cancer Statistics, 2017. *CA Cancer J Clin.* 2017 Jan;67(1):7-30. doi: 10.3322/caac.21387. Epub 2017 Jan 5. PMID: 28055103.
3. Meyers CA, Albitar M, Estey E. Cognitive impairment, fatigue, and cytokine levels in patients with acute myelogenous leukemia or myelodysplastic syndrome. *Cancer.* 2005 Aug 15;104(4):788-93. doi: 10.1002/cncr.21234. PMID: 15973668.
4. Karmo D, Hafeez A, Halalau A, et al. Cardiac Tamponade as the Initial Presentation of Acute Myeloid Leukemia: A Case Report with Review of the Literature. *Case Rep Oncol Med.* 2018 Mar 26;2018:8201917. doi: 10.1155/2018/8201917. PMID: 29780652;
5. Döhner H, Wei AH, Appelbaum FR, et al. Diagnosis and management of AML in adults: 2022 recommendations from an international expert panel on behalf of the ELN. *Blood.* 2022 Sep 22;140(12):1345-1377. doi: 10.1182/blood.2022016867. PMID: 35797463.
6. Lin M, Chen B. Advances in the drug therapies of acute myeloid leukemia (except acute wpromyelocytic leukemia). *Drug Des Devel Ther.* 2018 Apr 30;12:1009-1017. doi: 10.2147/DDDT.S161199. PMID: 29750014
7. Saleh, Y, Abdelkarim, O, Herzallah, K, et al. Anthracycline-induced cardiotoxicity:mechanisms of action, incidence, risk factors, prevention, and treatment. *Heart Fail Rev* 26,1159–1173 (2021). <https://doi.org/10.1007/s10741-020-09968-2>
8. Lutz A, Schelbert EB, Lontos K, et al. Acute Myeloid Leukemia Presenting as Effusive Constrictive Pericarditis. *CASE (Phila).* 2019 Oct 15;4(2):97-102. doi: 10.1016/j.case.2019.09.002. PMID: 32337400
9. Saab J, Hoda RS, Narula N, et al. Diagnostic yield of cytopathology in evaluating pericardial effusions: Clinicopathologic analysis of 419 specimens. *Cancer Cytopathol.* 2017 Feb;125(2):128-137. doi: 10.1002/cncy.21790. Epub 2016 Oct 24. PMID: 28207201.
10. Perek B, Tomaszewska I, Stefaniak S, et al. Cardiac tamponade - unusual clinical manifestation of undiagnosed malignant neoplasm. *Neoplasma.* 2016;63(4):601-6. doi: 10.4149/neo_2016_414. PMID: 27268924.
11. Ankney C, Swidler G, Robin C, et al. Acute myeloid leukaemia presenting with Cardiac Tamponade: A case report and review of the literature. *Cardiology Research and Cardiovascular Medicine*, 8(1). 2023. <https://doi.org/10.29011/2575-7083.100208>
12. Kim S, Kim E, Cho J, et al. Effect of Anti-Inflammatory Drugs on Clinical Outcomes in Patients With Malignant Pericardial Effusion. *J Am Coll Cardiol.* 2020 Sep 29;76(13):1551-1561. doi: 10.1016/j.jacc.2020.08.003. PMID: 32972532.
13. Kuykendall A, et al. Acute Myeloid Leukemia: The Good, the Bad, and the Ugly. *Am Soc Clin Oncol Educ Book* 38, 555-573 2018 May 23;38:555-573. doi: 10.1200/EDEBK_199519. PMID: 30231330.
14. Molica M, Mazzone C, Niscola P, et al. TP53 Mutations in Acute Myeloid Leukemia: Still a Daunting Challenge? *Front Oncol.* 2021 Feb 8;10:610820. doi: 10.3389/fonc.2020.610820. PMID: 33628731

Authors

Jessica M. Gonzalez, MD, Warren Alpert Medical School of Brown University, Rhode Island Hospital, Department of Medicine, Providence, RI.

Anshul Parulkar, MD, Warren Alpert Medical School of Brown University, Rhode Island Hospital, Department of Cardiology, Providence, RI.

Gabriel Lowenhaar, MD, Warren Alpert Medical School of Brown University, Rhode Island Hospital, Department of Emergency Medicine, Providence, RI.

Ari Pelcovits, MD, Warren Alpert Medical School of Brown University, Rhode Island Hospital, Department of Hematology and Oncology, Providence, RI.

Disclosures

The authors have no conflicts of interest to disclose.

Correspondence

Jessica M. Gonzalez, MD
Rhode Island Hospital, Department of Medicine
593 Eddy Street, Providence, RI 02903
Jlowenhaar@gmail.com